

Content available at: <https://www.ipinnovative.com/open-access-journals>

IP International Journal of Ocular Oncology and Oculoplasty

Journal homepage: <https://ijooo.org/>

## Case Report

# Conjunctival squamous cell carcinoma in Verruca Vulgaris- A rare case report

Venugopal Anitha<sup>1,\*</sup>, Aditya Ghorpade<sup>1</sup>, Swati Kumble<sup>2</sup>, Meenakshi Ravindran<sup>3</sup>

<sup>1</sup>Dept. of Cornea and Refractive Services, Aravind Eye Hospital, Tirunelveli, Tamil Nadu, India

<sup>2</sup>Aravind Eye Hospitals, Tirunelveli, Tamil Nadu, India

<sup>3</sup>Dept. of Pediatric and Strabismus Services, Aravind Eye Hospital, Tirunelveli, Tamil Nadu, India



## ARTICLE INFO

### Article history:

Received 06-10-2020

Accepted 09-11-2020

Available online 23-01-2021

### Keywords:

Verruca Vulgaris

Conjunctival Squamous Neoplasia

OSSN

Mitomycin -C

## ABSTRACT

**Purpose:** To report a rare association of conjunctival squamous cell carcinoma with the benign skin condition, Verruca Vulgaris, with the common aetiology being HPV.

**Case Report:** A 30 year-old-male with benign, diffuse, verrucous lesions all over the skin, presented with conjunctival squamous cell carcinoma, involving more than 180 degree of the limbus and cornea was treated successfully with topical chemotherapy without recurrence. HPV infection is the predisposing to both these conditions.

**Results:** The association of Verruca Vulgaris and Conjunctival papilloma has been established to a great degree in literature along with the common etiological factor HPV, and not conjunctival Squamous cell carcinoma, is the peculiarity of this case report.

© This is an open access article distributed under the terms of the Creative Commons Attribution License (<https://creativecommons.org/licenses/by/4.0/>) which permits unrestricted use, distribution, and reproduction in any medium, provided the original author and source are credited.

## 1. Introduction

Lee and Hirst first described Ocular Surface Squamous Neoplasia (OSSN) 1. The incidence is 0.13-1.9% per lakh.<sup>1</sup> It is an umbrella term, which includes benign to malignant lesions of the conjunctiva. The risk factors are male gender, old age, UV exposure, Immunosuppression, Smoking, Vitamin A deficiency, HIV infections, Hepatitis B, and HPV(Human Papilloma Virus) 16 and 18 (high-risk types).<sup>2</sup> The prevalence of Conjunctival papilloma associated with HPV is 44-92%, and of Squamous cell carcinoma (SCC) is 33%.<sup>3</sup> Verruca Vulgaris (VV) or Common warts are caused by epidermal infection caused by HPV 6 and 11 (Low-risk types).<sup>4</sup> The incidence of common warts among the general population is 1-13%.<sup>4</sup> Reports of co-existent conjunctival papillomas and verruca Vulgaris implies that the HPV infection can co-occur at multiple sites.<sup>4,5</sup> The other skin conditions associated with OSSN include Papillon-Lefevre syndrome,<sup>6</sup> Xeroderma pigmentosa,<sup>7</sup>

Non-Hodgkin's lymphoma,<sup>8</sup> congenital ichthyosis,<sup>9</sup> and Epidermodysplasia verruciformis.<sup>10</sup> Verruca Vulgaris and associated mucosal type of SCC have not been previously reported in the literature. We report a case of conjunctival SCC in association with verruca Vulgaris.

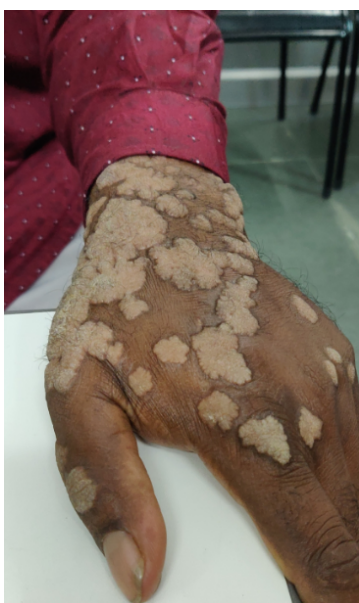## 2. Case Report

A 30-year-old male, farmer by occupation, presented to us with redness in the left eye for the past 3months. The best Corrected Visual Acuity in both eyes was 20/20. Recent medical history included dermatology consultation for an unknown skin disease. On general examination, diffuse, multiple, elevated cauliflower-like lesions were seen all over the arms, legs, and face (Figure 1). Ocular inspection of the right eye was within normal limits. The left eye revealed diffuse, elevated, pink, fleshy gelatinous growth around the limbus, invading 2mm of cornea extending nasally from 5 to 1 o'clock hours and sentinel vessels (Figure 2a). The skin biopsy revealed acanthosis with downward invaginations and papillomatosis with

\* Corresponding author.

E-mail address: [aniths22@gmail.com](mailto:aniths22@gmail.com) (V. Anitha).

marked surface keratinization- church-spire keratosis. The subepithelial tissue was hyperemic and is infiltrated with few mononuclear inflammatory cells, and kiliocytes were present. The complete blood counts were normal. ELISA for HIV, VDRL/RPR, HBsAg was non-reactive. Hence the clinical diagnosis of OSSN was made. Since the OSSN involves more than six clock hours, an incisional biopsy was done. The biopsy report showed squamous cell carcinoma. To avoid surgical complications such as LSCD, conjunctival scarring, and symblepharon, Mitomycin-C (MMC) 0.04% was started, one drop four times daily for a week and one week off cycle. After three cycles of chemotherapy, the lesion completely regressed (Figure 2b and c). The sequence was continued for one more week with MMC 0.02% to prevent the recurrence. The patient is on regular follow-up for the past one year, and no recurrence was noted (Figure 2d).

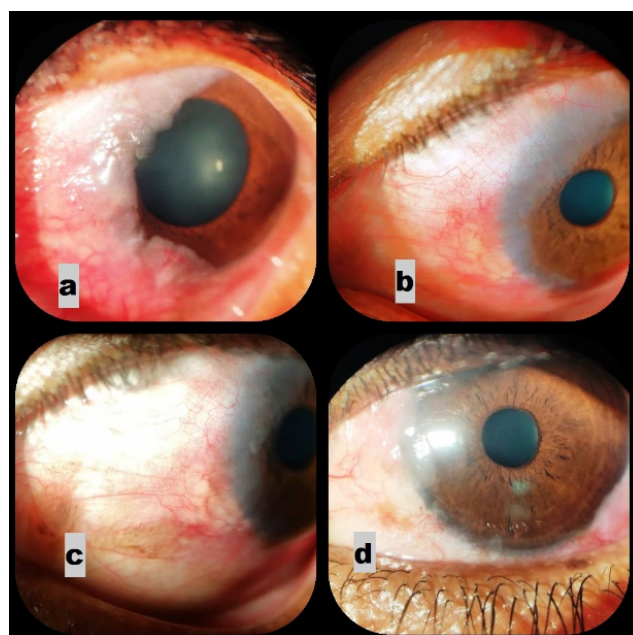


**Fig. 1:** Benign Verrucous lesions all over the skin

### 3. Discussion

Verruca Vulgaris is a skin condition caused by HPV 6 & 11.<sup>4,11</sup> They rarely occur on the eyelids, but if seen, typically appear near the lid margin. The risk factors are the usage of public showers, meat cutters, eczema, and a weak immune system.<sup>12</sup> The lesions appear diffuse, hyperkeratotic, exophytic, and dome-shaped papules or nodules and typically multiple, or sessile, with discrete borders.<sup>12</sup> Diagnosis is clinically confirmed by hemorrhages caused by cutting the wart horizontally with a scalpel or piercing it.<sup>4</sup> They spread by direct contact or autoinoculation.<sup>4</sup>

It is a benign condition but frequently has been reported with squamous cell carcinoma of the skin. Kopelson et



**Fig. 2:** **a:** Pinkish, Gelatinous mass seen extending nasally from 5 to 10 o'clock hours and sentinel vessels, **b:** and **c:** The Regressing lesions after chemotherapy, **d:** The appearance of the eye at the final visit

al.<sup>13</sup> reported SCC at the verruca Vulgaris, in the finger (10 out of 32 patients). Zaesim et al. reported SCC arising within the verruca Vulgaris on the nipple in a 49-year-old Caucasian woman, and the association was confirmed by positive Immunohistochemical testing for HPV L1 capsid protein.<sup>14</sup> The association of conjunctival papillomas and Verrucae Vulgaris, which shares the common etiological factor HPV, can occur together, but conjunctival SCC and Verruca Vulgaris have not been reported previously in the literature. The presence of Kiliocytosis is the pathognomic feature of HPV infection, though not confirmatory for diagnosis. Carreira H et al. in his systematic review and meta-analysis to quantify the association between HIV and HPV infection and OSSN reported that HIV was associated with the risk of OSSN and in HPV; only cutaneous types seem to be a risk factor and not the mucosal types.<sup>15</sup>

Our case was peculiar in which the patient presented to us with extensive OSSN involving the limbus and cornea. The incisional biopsy revealed the SCC and had an excellent prognosis with chemotherapy. The recovery time was six weeks. The SCC can occur with other skin conditions such as EDV,<sup>10</sup> Xeroderma pigmentosa,<sup>7</sup> and Congenital Ichthyosis,<sup>9</sup> but uncommon with verruca Vulgaris. The common etiological association would be the HPV. The other skin condition associated with HPV infection is Epidermodysplasia verruciformis (EDV).<sup>10</sup> It is also known as tree man syndrome, is a rare, autosomal recessive disorder with a high risk of skin cancer in 30-70%

individuals. It is characterized by abnormal susceptibility to HPV infections. EDV is caused by multiple types of HPV, 3,8,10, and 14 in 86% of cases, suggesting the strong association of HPV with SCC of skin. It is characterized by scaly macules and papules resembling tree bark, particularly on the hands and feet.<sup>10</sup>

To conclude, the association of Verruca Vulgaris and conjunctival SCC has not been reported in the literature. HPV is the common etiological factor between Verruca Vulgaris and OSSN; the presence of koiocytes in the biopsy report suggested the same.

#### 4. Conflicts of Interest

All contributing authors declare no conflicts of interest.

#### 5. Source of Funding

None.

#### References

- Lee GA, Hirst LW. Ocular surface squamous neoplasia. *Survey Ophthalmol.* 1995;39(6):429–50. doi:10.1016/s0039-6257(05)80054-2.
- Shields CL, Chien JL, Surakiatchanukul T, Sioufi K, Lally SE, Shields JA, et al. Conjunctival Tumors: Review of Clinical Features, Risks, Biomarkers, and Outcomes-The J. Donald M. Gass Lecture. *Asia Pac J Ophthalmol (Phila).* 2017;6:109–20.
- Sjo NC, von Buchwald C, Cassonnet P, Norrild B, Prause JU, Vinding T, et al. Human papillomavirus in normal conjunctival tissue and in conjunctival papilloma: types and frequencies in a large series. *Br J Ophthalmol.* 2007;91(8):1014–5. doi:10.1136/bjo.2006.108811.
- Bacelieri R, Johnson SM. Cutaneous Warts: An Evidence-Based Approach to Therapy. *AFP.* 2005;72:647–52.
- Girolamo ND. Association of human papilloma virus with pterygia and ocular-surface squamous neoplasia. *Eye.* 2012;26(2):202–11. doi:10.1038/eye.2011.312.
- Murthy R, Honavar SG, Vemuganti GK, Burman S, Naik M, Parathasaradhi A, et al. Ocular surface squamous neoplasia in Papillon-Lefevre syndrome. *Am J Ophthalmol.* 2005;139(1):207–9. doi:10.1016/j.ajo.2004.07.028.
- Gupta N, Sachdev R, Tandon R. Ocular surface squamous neoplasia in xeroderma pigmentosum: clinical spectrum and outcome. *Graefes Arch Clin Exp Ophthalmol.* 2011;249(8):1217–21. doi:10.1007/s00417-011-1679-8.
- Joshi RS. Ocular surface squamous neoplasia inpatient with non-Hodgkin's lymphoma. *Indian J Ophthalmol.* 2017;65:71–2.
- Kumar DA, Krishna SN. Invasive ocular surface squamous neoplasia in congenital ichthyosiform erythroderma. *TNOA J Ophthalmic Sci Res.* 2017;55(4):318.
- Ateynyi-Agaba C, Weiderpass E, Smet A, Dong W, Dai M, Kahwa B, et al. Epidermodysplasia verruciformis human papillomavirus types and carcinoma of the conjunctiva: a pilot study. *Br J Cancer.* 2004;90(9):1777–9. doi:10.1038/sj.bjc.6601743.
- Sjo NC, von Buchwald C, Cassonnet P, Norrild B, Prause JU, Vinding T, et al. Human papillomavirus in normal conjunctival tissue and in conjunctival papilloma: types and frequencies in a large series. *Br J Ophthalmol.* 2007;91(8):1014–5. doi:10.1136/bjo.2006.108811.
- Loo SF, Tang WM. Warts (non-genital). *BMJ Clin Evid.* 2014;2014(12).
- Kopelson P, Nguyen Q, Moy R. Verruca Vulgaris and Radiation Exposure Are Associated with Squamous Cell Carcinoma of the Finger. *J Dermatol Surg Oncol.* 1994;20(1):38–41. doi:10.1111/j.1524-4725.1994.tb03747.x.
- Zaesim A, Jackson AC, Lee SW, Price SA. Squamous Cell Carcinoma Arising within Verruca Vulgaris on the Nipple. *Case Rep Dermatol Med.* 2018;.
- Carreira H, Coutinho F, Carrilho C, Lunet N. HIV and HPV infections and ocular surface squamous neoplasia: systematic review and meta-analysis. *Br J Cancer.* 2013;109:1981–8. doi:10.1038/bjc.2013.539.

#### Author biography

**Venugopal Anitha**, Senior Consultant/HOD

**Aditya Ghorpade**, Consultant

**Swati Kumble**, Senior Resident

**Meenakshi Ravindran**, Senior Consultant/ HOD

**Cite this article:** Anitha V, Ghorpade A, Kumble S, Ravindran M. Conjunctival squamous cell carcinoma in Verruca Vulgaris- A rare case report. *IP Int J Ocul Oncol Oculoplasty* 2020;6(4):257-259.