



## Short Communication

# A case of simple bilateral dacryops: A review of literature

Nagalakshmi Narayana-Swamy<sup>1,\*</sup>, Alhaj Farhath Tasneem<sup>1</sup>, Irvathur Vittal Nayak<sup>1</sup>

<sup>1</sup>Dept. of Ophthalmology, Vydehi Institute of Medical Sciences and Research Center, Bengaluru, Karnataka, India



### ARTICLE INFO

#### Article history:

Received 13-12-2019

Accepted 06-08-2020

Available online 03-09-2020

#### Keywords:

Dacryops

Orbit

Lacrimal gland

### ABSTRACT

**Purpose:** Dacryops, is a clinical entity of unknown aetiology. Here we present the clinical features and radiological presentation of a bilateral dacryops as a unique case.

**Case Description:** A 36year old woman presented with unilateral lid swelling, since 7years non-perceptible but obvious on reflex tear secretion. However, she had no complaints of pain, redness, discharge. On examination, vision was normal and lacrimal ducts were patent. Mass in the left eye was noted on reflex tear secretion such as exposure to air/chewing. No signs of inflammation present. Tear film tests were normal. Fundus, routine blood parameters and serum ACE was negative. Ultrasonography of the orbits showed well defined hypoechoic cystic lesion along lateral aspect of left globe and CT showed bilateral predominantly cystic lesion more prominent on left compared to right. Bilateral Dacryops, is unusual. Thus it becomes essential that clinicians are aware of this condition and consider it as one of the differential diagnosis of the lacrimal gland masses.

**Results:** A case of bilateral dacryops detected incidentally, was investigated and followed up.

**Conclusion:** Dacryops, or a lacrimal gland ductal cyst, is a rare clinical entity, whose bilateral presentation is unusual. It is essential that we as clinician's are aware of this condition and consider it as a differential diagnosis of the lacrimal gland masses.

© 2020 Published by Innovative Publication. This is an open access article under the CC BY-NC license (<https://creativecommons.org/licenses/by-nc/4.0/>)

## 1. Introduction

Lacrimal apparatus has its own unique anatomy. The tears which are produced by lacrimal gland and accessory lacrimal glands, allows drainage of tears through the lacrimal ducts. The main lacrimal gland is situated in the anterolateral aspect of the orbit and is divided into an orbital part and palpebral part.<sup>1</sup>

Dacryops is a rare clinical entity usually affecting the palpebral lobe of the lacrimal gland. It is a rare cystic condition of the lacrimal gland duct of unknown etiology.<sup>2</sup> An history of trauma or inflammation or a congenital anomaly of the excretory duct could be an precipitating factor.<sup>3</sup> Mechanism of spiral valve effect and neuromuscular dysfunction of the duct wall reflects underlying functional problem and intermittent fluctuation

of the swelling;<sup>2</sup> It is also said that periductal or conjunctival inflammation may result in lacrimal gland hypersecretion causing damage to the ductile walls and secondary ductile obstruction resulting in formation of the cyst.<sup>3</sup> This rare clinical presentation is usually insidious in onset, presenting as a painless mass on the eye lids. Its bilateral presentation is usually rare.

In our work, we present the clinical features and radiological presentation of a simple.

Dacryops detected bilaterally as a unique case.

## 2. Case Study

A 36-year-old female of Indian origin presented to the EYE OPD, with gradual painless swelling of the left upper eyelid for 7 years (Figure 1). There was no history of trauma, inflammation, discharge, epiphora, eye surgery, or systemic illness. The patient mentioned periodic fluctuation in the size of swelling, which increased on crying or

\* Corresponding author.

E-mail address: [anushkanarayan5@gmail.com](mailto:anushkanarayan5@gmail.com) (N. Narayana-Swamy).

chewing. She had no associated pain, redness, discharge or visual disturbances. She denied history of trivial trauma or infection. No similar history in the past or similar complaints in the family members.

At present, best corrected visual acuity in both eyes was 6/6 with normal near and colour vision. Ocular fundus was normal and lacrimal syringing was patent in both eyes.

There was a non-tender, fluctuant, tense swelling, and round to oval in shape with smooth consistency on the lateral two-thirds of the upper lid on reflex tear secretion. There was no limitation of extraocular movements, proptosis, or globe dystopia. There was no sign of inflammation, and tear breakup time and Schirmer’s test results.

Ultrasonography showed a single-walled cyst in the left eye with low internal reflectivity, without intra orbital extension (Figure 2). And further computerised tomography (Figures 3 and 4) with contrast enhancement was performed to confirm the diagnosis and cysts were noted bilaterally more obvious on left side.

Routine blood investigations were normal and other investigations to rule out autoimmune disorders were negative. Patient was asymptomatic, denied further management.

She has been kept on followup.



**Fig. 1:** Showing clinically obvious swelling on left side (external examination), appears normal on right side

### 2.1. On Radiological Examination

1. Ultrasonography of the orbits showed a well-defined fluid filled cystic lesion along the lateral aspect of globe of left globe (Figure 2)

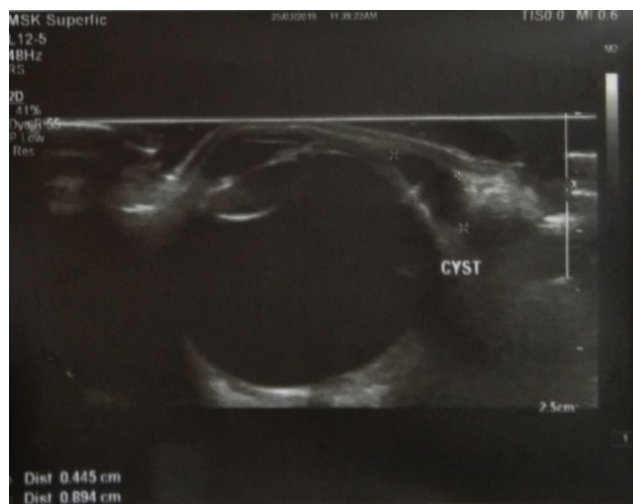
2. Axial and direct coronal CT of orbits with sagittal oblique reformation was performed after administration of a non-ionic contrast material.(Figure 4 )

CT showed a bilateral lateral predominantly cystic lesion more prominent on left side compared to right, contiguous with the palpebral lobe of the lacrimal gland detected on both sides.

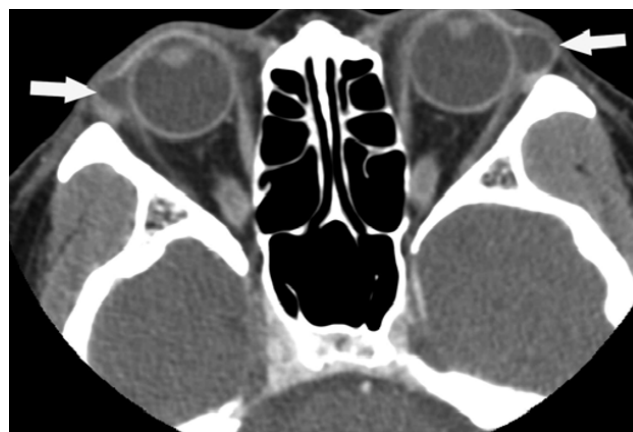
Lesion on right side was detected as an incidental finding.

1. Measurement RE 0.5 X 0.7cm LE 1.5 X 2cm
2. Cyst was consistent with fluid density, with peripheral enhancement without nodular or irregular enhancements.

3. Globe and rest of the lacrimal gland tissue was normal
4. No associated tissue inflammation
5. No bony erosions or irregularities seen



**Fig. 2:** Showing ultrasonography of the orbit showing cysts of left eye

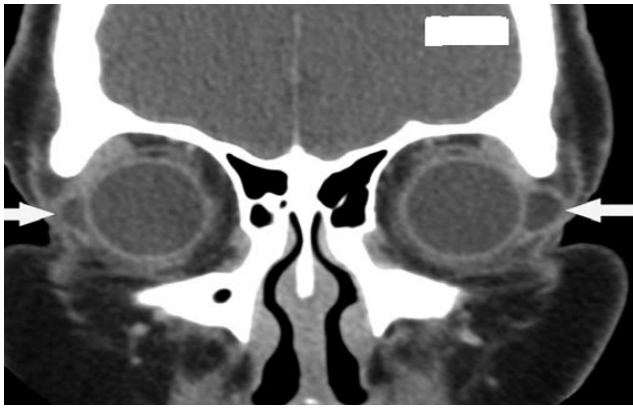

**Fig. 3:** CT image showing bilateral dacryops

### 3. Discussion

Lacrimal gland cysts also known as Dacryops.<sup>4-6</sup> usually presents unilaterally,<sup>5</sup> detected on examination Classically a non-tender, well circumscribed, transparent lateral lid swelling along superior temporal aspect of the orbit. Cases exhibiting tenderness and irritation have also been reported.<sup>7</sup>

Histologically, these cysts are composed of an inner cuboidal layer containing goblet cells surrounded by an outer myo-epithelial layer with a surrounding glandular tissue and dilated lacrimal gland ducts.<sup>6</sup> Usually slow



**Fig. 4:** CT image showing bilateral dacryops

growing lesions, can result in proptosis or globe displacement due to mass effect.<sup>7</sup>

Contrast-enhanced computerised tomography masses with fluid density in the region of the lacrimal glands, lateral to the globe with no bony abnormality is detected.<sup>8,9</sup> Although there are no CT attenuation values specific for dacryops, the literature has reported fluid and soft-tissue densities in relation to these swellings.<sup>3,6</sup>

In our patient, CT examination (field of view, 15 cm; 120 kVp; 230 mA; 1.3-mm slice thickness; matrix, 512 \* 512; axial and direct coronal imaging with sagittal reformations) showed bilateral fluid-density masses located in the palpebral lobe of the lacrimal glands. No evidence of bone erosion or adjacent inflammation was detected (Figures 3 and 4). Although the patient complained of the swelling on left side, lesion was detected on right side (Figure 2) incidentally on radiological examination.

Cysts involving the orbital part of lacrimal gland are rare. Because of the bilateral incidence of the cysts, it is vital to rule out systemic disease such as Sjogren's syndrome, Mikulicz disease, sarcoidosis.<sup>10</sup> As they result in non-specific diffuse enlargement of the cysts. Other differential diagnosis to be considered are benign and malignant orbital tumours such as pleomorphic adenoma, adenoid cystic carcinoma, mucoepidermoid carcinoma, pleomorphic adenocarcinoma, lymphoma, pseudo lymphoma, and metastasis and developmental cysts such as dermoid and epidermoid cysts must be considered.

Overall, the diagnosis depends on biopsy results and the patient's clinical history. In our patient, the bilaterality of the lesion, fluid attenuation of the lesions, lack of internal enhancement, and absent inflammation serves as an evidence for this condition. Therefore, other possibilities were considered such as dacryops because of its classic location in the orbit and presentation.

Although the treatment for symptomatic dacryops involves local resection through a superotemporal conjunctival approach without damaging the remaining

tear ducts. Use of topical antibiotic/steroid ointment has also been described. Marsupialisation can be performed to fistulise the cyst onto the conjunctival surface. Some authors have used blue-green argon laser to open and fistulise the cyst.<sup>11</sup> Smaller cysts that are asymptomatic can be observed as in our report.

In summary, dacryops, or a lacrimal gland ductal cyst, is a rare clinical entity. It is essential that we as clinicians are aware of this condition and consider it as a differential diagnosis of the lacrimal gland masses.

#### 4. Source of Funding

None.

#### 5. Conflict of Interest

None.

#### References

1. Newell FW. Lacrimal apparatus. In: Ophthalmology: principles and concepts. St. Louis, MO: Mosby; 1986. p. 254.
2. Jakobiec FA, Zakka FR, Perry LP. The Cytologic Composition of Dacryops: An Immunohistochemical Investigation of 15 Lesions Compared to the Normal Lacrimal Gland. *Am J Ophthalmol.* 2013;155(2):380–96.
3. Bullock JD, Fleishman JA, Rosset JS. Lacrimal Ductal Cysts. *Ophthalmol.* 1986;93(10):1355–60.
4. Conway ST. Bilateral Lacrimal Duct Cyst. *Pediatric Ann.* 1988;17(11):811–3.
5. Duran JA, Cuevas J. Cyst of accessory lacrimal gland. *Br J Ophthalmol.* 1983;67(7):485–6.
6. Smith S, Rootman J. Lacrimal ductal cysts. Presentation and management. *Survey Ophthalmol.* 1986;30(4):245–50.
7. Hornblase A, Herschorn BJ. Lacrimal gland duct cysts. *Ophthalmic Surg.* 1985;16(5):301–6.
8. Bradey N, Hayward JM. Case Report: Bilateral lacrimal gland enlargement: An unusual manifestation of dacryops. *Clin Radiol.* 1991;43(4):280–1.
9. Khoury N, Haddad MC, Tawil A. Ductal cysts of the accessory lacrimal glands: CT findings. *AJNR.* 1999;20:1140–2.
10. Sacher M, Lanzieri CF, Sobel LI, Som PM. Computed tomography of bilateral lacrimal gland sarcoidosis. *J Comput Assist Tomogr.* 1984;8:213–5.
11. Shields JA, Shields CL, Scartozzi R. Survey of 1264 patients with orbital tumors and simulating lesions. *Ophthalmol.* 2004;111(5):997–1008.

#### Author biography

**Nagalakshmi Narayana-Swamy** Post Graduate Resident

**Alhaj Farhath Tasneem** Professor

**Irvathur Vittal Nayak** Professor and HOD

**Cite this article:** Narayana-Swamy N, Tasneem AF, Nayak IV. **A case of simple bilateral dacryops: A review of literature**. *IP Int J Ocul Oncol Oculoplasty* 2020;6(3):229-231.