



## Case Report

# Primary acquired melanosis: A unique presentation

Vandana Sharma<sup>1</sup>, Gunjan Chadha<sup>1,\*</sup>, Anchit Wapa<sup>2</sup>, Joginder Pal Chugh<sup>1</sup>,  
Urmil Chawla<sup>1</sup>

<sup>1</sup>Regional Institute of Ophthalmology, Pt. B.D. Sharma PGIMS, Rohtak, Haryana, India

<sup>2</sup>Shri Lal Bahadur Shastri Government Medical College, Mandi, Himachal Pradesh, India



### ARTICLE INFO

#### Article history:

Received 30-06-2020

Accepted 29-07-2020

Available online 03-09-2020

#### Keywords:

Conjunctival nevus

Malignant melanoma

Primary acquired melanosis

### ABSTRACT

**Purpose:** to report a case of PAM with atypical presentation

**Observations:** We are reporting a case of a 45 years old male who presented to the outpatient department of Ophthalmology with complaints of sudden onset watering and foreign body sensation in the right eye. Detailed slit lamp examination revealed an elevated pigmented lesion of the conjunctiva in the nasal quadrant extending up to 2 clock hours. Excision biopsy was done and histopathological examination found the lesion to be moderate grade dysplastic conjunctival PAM.

**Conclusions and importance:** Primary acquired melanosis (PAM) is an acquired disorder of the conjunctiva characterized by a flat brown pigmentation of the conjunctival epithelium. It may be analogous to lentigo maligna — a preinvasive epidermal pigmentation of skin. It presents as a unilateral patchy area of conjunctival pigmentation mostly seen in middle aged or elderly light skinned individuals with a potential for malignant transformation.

© 2020 Published by Innovative Publication. This is an open access article under the CC BY-NC license (<https://creativecommons.org/licenses/by-nc/4.0/>)

## 1. Introduction

Primary acquired melanosis (PAM) is a pigmented intraepithelial lesion of the conjunctiva which can undergo malignant transformation. The age at which it is first noticed is important as it helps in distinguishing nevi from PAM. Nevi are mostly seen in early childhood while PAM are seen in the elderly. Nevi usually present with a cyst and are well circumscribed. They are thicker and have epithelial and sub epithelial component. PAM, on the other hand is a diffuse intraepithelial disease, therefore it appears as pigmentary dusting and is usually not well circumscribed.<sup>1</sup>

PAM with atypia can progress to malignant melanoma, while PAM with no atypia is usually benign. It is a pre-cancerous condition and can often lead to life threatening malignant melanoma. PAM accounts for 11% of total conjunctival tumors and 21 % of melanocytic lesions.<sup>2</sup>

We are presenting a case of PAM in a young Asian male who presented with sudden onset of symptoms and conjunctival lesion which is quite unlike the typical presentation.

## 2. Case Report

A 38 years old male presented to the Ophthalmology OPD with complaints of sudden onset redness, watering and foreign body sensation in the right eye for the last 10 days. He had a history of insect striking the right eye while driving a motorbike just preceding the onset of symptoms. There was no past history of ocular trauma, ocular surgery or any chronic ocular medication. There was no medical history of diabetes, hypertension, asthma or tuberculosis.

On examination, BCVA in both eyes on Snellen's chart was 6/6. Slit lamp examination revealed a brown-black pigmented and elevated area of conjunctiva extending from 2 o'clock to 4 o'clock on the nasal side in the right eye. A leash of dilated and tortuous vessel extended from the

\* Corresponding author.

E-mail address: [gunjanchadha64@gmail.com](mailto:gunjanchadha64@gmail.com) (G. Chadha).

medial canthus to the lesion. It was freely mobile and no foreign body was palpable with a cotton tipped applicator in the lesion. Rest of the anterior segment was normal. The patient denied presence of any old pigmented lesion in the region. (Figure 1).

Anterior segment of the left eye was normal. Posterior segment examination of both eyes was normal. Probability of an embedded foreign body was considered keeping the patient's history in mind. However, the possibility of Primary acquired melanosis was also not ruled out.

The pigmented lesion was excised with wide clear margins of 2mm and the excised tissue was sent for HPE examination. Postoperatively, patient was started on lubricating eye drops four times a day, moxifloxacin and ketorolac eye drop 4 times a day and moxifloxacin eye ointment 2 times a day.

HPE report showed melanocytic cells with moderate atypia. Underlying conjunctival degeneration was also present. (Figure 2) Patient was followed upto 2 years after surgery. There was complete resolution of symptoms and no recurrence was seen.

### 3. Discussion

Conjunctival primary acquired melanosis (PAM) is an acquired flat, painless non-cystic pigmented lesion of the conjunctiva.<sup>2,3</sup> PAM is a phenotypically serious melanocytic lesion which can often lead to malignant melanoma of conjunctiva. However, it has been a subject of changing concepts regarding demographics, terminology, clinical definition, histopathological definition, incidence, natural course and management.<sup>4</sup>

It has also been reported in middle aged males of Caucasian origin, with a median age at diagnosis of 56 years.<sup>2</sup> Most cases are asymptomatic or present with a pigmented area in the conjunctiva. Our case was unique as the patient presented with acutely symptomatic, younger and was of Asian origin.

Histopathological examination is a predictor for malignant conversion of PAM into melanoma. A PAM without atypia is best characterised by minimal melanocytic hyperplasia along the basal epithelial layer of conjunctiva. PAM with atypia usually shows isolated or confluent nests of atypical melanocytes.<sup>5–7</sup> If PAM shows microscopic evidence of atypia, progression to melanoma occurs in 46 % of the cases. The extent of conjunctival involvement is the most important risk factor for development of conjunctival melanoma.<sup>3</sup> The greater the involvement of conjunctival clock hours, greater is risk of conversion to melanoma.<sup>1</sup>

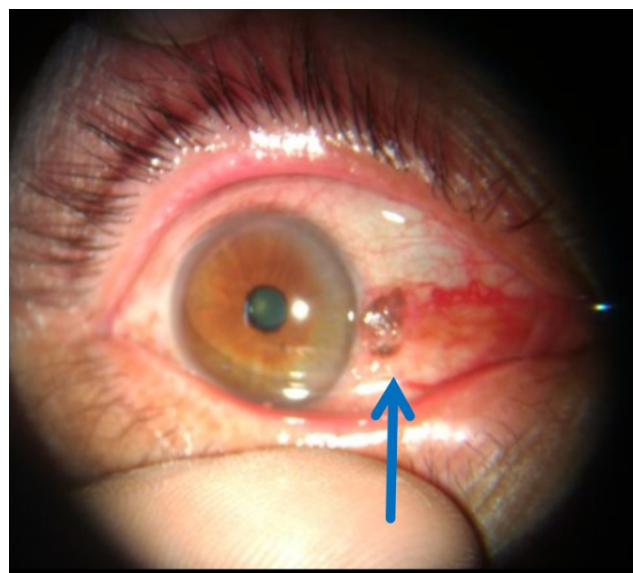
The treatment of PAM depends on area of conjunctiva involved. If less than 2 clock hours is involved — close monitoring is all that is needed. For PAM lesions with 2–5 clock hours of conjunctival involvement, excision biopsy and cryotherapy to the edges is advocated. For lesions greater than 5 clock hours, wide incisional biopsy with

cryotherapy to all remaining pigmentation should be done.<sup>2</sup> The treatment protocol as advised by Shield et al has been summarized in Table 1.<sup>2</sup> Other treatment options for PAM are topical mitomycin C and cryotherapy.<sup>8</sup>

**Table 1:** Preferred modality of treatment for different extent of disease in PAM (Shield et al)

Extent of lesion	Preferred modality of treatment
<2 clock hours	Observation
2-5 clock hours	Excision biopsy with clear margins followed by cryotherapy to the edges
>5 clock hours	Wide incisional biopsy with cryotherapy to residual pigmented conjunctiva

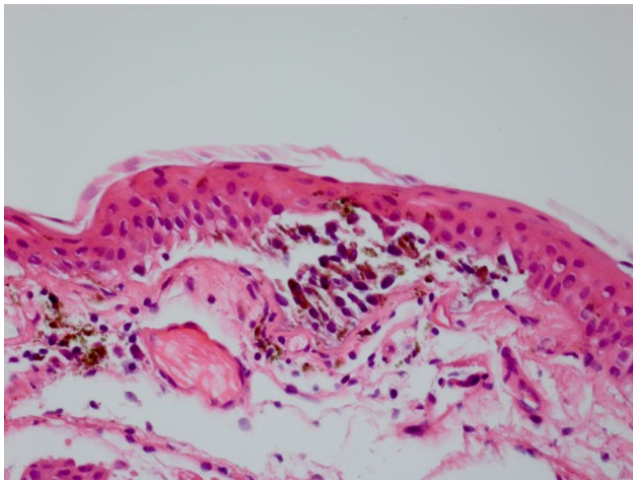
Some groups advocate clinical observation for all patients with features of flat acquired pigmentation. Biopsy is mandatory in cases with additional features such as thickened conjunctiva, intrinsic vascularity, feeder vessels and progression or multiple risk factors for melanoma development such as intense dark appearance, corneal involvement and palpebral location.<sup>9</sup> In our case the lesion had feeder vessel extending from the medial canthus to the lesion which was against the typical appearance of a conjunctival nevus.



**Fig. 1:** Pigmented and elevated lesion in nasal conjunctiva in right eye

### 4. Conclusion

PAM though reported most commonly in elderly population can also be seen in young Asian population. It has to be carefully identified and managed accordingly based on the clock hours of conjunctival involvement as more the involvement of conjunctiva more is the risk of progression to melanoma. Histopathological examination



**Fig. 2:** Histopathological picture depicting atypical cells with conjunctival degeneration

helps to understand the pattern of PAM with or without atypia. Treatment modalities are surgical excision, topical mitomycin C and cryotherapy. The patient should be followed up for a long time as some lesions may convert to melanoma.

### 5. Acknowledgements

None.

### 6. Source of Funding

None.

### 7. Conflicts of Interests

None.

## References

1. Shields CL, Chien JL, Surakiatchanukul T, Sioufi K, Lally SE, Shields JA, et al. Conjunctival Tumors: Review of Clinical Features, Risks, Biomarkers, and Outcomes. *Asia Pac J Ophthalmol*. 2017;6(2):109–20.
2. Shields JA, Shields CL, Mashayekhi A, Marr BP, Benavides R, Thangappan A, et al. Primary Acquired Melanosis of the Conjunctiva: Risks for Progression to Melanoma in 311 Eyes. *Ophthalmol*. 200;105:61–71.
3. Gloor P, Alexandrakis G. Clinical characterization of primary acquired melanosis. *Gaz Med Fr*. 1995;36(8):1721–9.
4. Shields JA, Shields CL. Conjunctival primary acquired melanosis. vol. 824. Lippincott, Williams & Wilkins; 2007. p. 824.
5. Folberg R, Jakobiec FA, Bernardino VB, Iwamoto T. Benign Conjunctival Melanocytic Lesions. *Ophthalmol*. 1989;96(4):436–61.
6. Folberg R, McLean IW, Zimmerman LE. Primary acquired melanosis of the conjunctiva. *Human Pathol*. 1985;16(2):129–35.
7. Grossniklaus HE, Green WR, Luckenbach M, Chan CC. Conjunctival lesions in adults. A clinical and histopathologic review. *Cornea*. 1987;6(2):78–116.
8. Finger PT, Czechowska G, Liarikos S. Topical mitomycin C chemotherapy for conjunctival melanoma and PAM with atypia. *Br J Ophthalmol*. 1998;82(5):476–9.
9. Cohen V, Day O, F R. Management Issues in Conjunctival Tumours: Conjunctival Melanoma and Primary Acquired Melanosis. *Ophthalmol Ther*. 2019;8(4):501–10.

## Author biography

**Vandana Sharma** Senior Resident

**Gunjan Chadha** Senior Resident

**Anchit Wapa** Senior Resident

**Joginder Pal Chugh** Senior Professor and Head

**Urmil Chawla** Professor

**Cite this article:** Sharma V, Chadha G, Wapa A, Chugh JP, Chawla U. **Primary acquired melanosis: A unique presentation.** *IP Int J Ocul Oncol Oculoplasty* 2020;6(3):223-225.