



## Original Research Article

## Surgical treatment of pterygium in melanoderma: Preliminary results of the conjunctival autograft at the infirmary of bamako hospital

Bakayoko Seydou<sup>1</sup>, Sidibe Mohamed Kolé<sup>1</sup>, Elien G Y R R<sup>1,\*</sup><sup>1</sup>Dept. of Ophthalmology, IOTA-Teaching Hospital, Bamako, Mali

## ARTICLE INFO

## Article history:

Received 09-06-2020

Accepted 24-06-2020

Available online 03-09-2020

## Keywords:

Surgery

Pterygium

Conjunctival autograft

Infirmary Bamako Hospital

Mali

## ABSTRACT

**Introduction:** Pterygium is a benign eye disease with varying prevalence in different regions. Ultraviolet light is the main risk factor. The curative treatment is surgical, but it remains incompletely effective with recurrences that are not rare. Many techniques are described alone or combined with adjuvant treatments. The aim of our work is to evaluate the preliminary outcome of pterygial excision with conjunctival autograft.

**Materials and Methods:** A prospective study was carried out between May 2016 and October 2017 in the ophthalmology department of the Bamako Hospital Infirmary. It included 81 patients who had a primary or recurrent pterygium operated on in the department.

**Results:** The average age was 45.74 years. The sex ratio was 1.13 M/F. Of the 81 pterygions operated on, 14.8% were stage IV and 16% recurrent, with nasal localization in 92.6%. Conjunctival hyperaemia more or less associated with subconjunctival haemorrhage was present until postoperative day 15. We noted 4.9% recurrence.

**Discussion:** There is no consensus in the surgical treatment of pterygions.

The technique of removal of the pterygium associated with conjunctival autograft would induce fewer complications and the least recurrence.

**Conclusion:** Early management of pterygium with the autograft technique remains the best therapeutic choice for this condition.

© 2020 Published by Innovative Publication. This is an open access article under the CC BY-NC license (<https://creativecommons.org/licenses/by-nc/4.0/>)

## 1. Introduction

Pterygium is a progressive and invasive conjunctivo-elastic neoformation that threatens visual acuity.<sup>1</sup> Its tendency to recur is the stumbling block to various surgical techniques.<sup>2</sup> It is a benign ocular disease, the prevalence of which varies from region to region.<sup>1-3</sup> Its main risk factor is ultraviolet radiation.<sup>3</sup> Many techniques are described alone or in combination with adjuvant treatments.<sup>4-6</sup>

In the Middle East, the success rate in 2017 of pterygium surgery using conjunctival autograft was 100%.<sup>7</sup>

In Asia, the authors reported a success rate of 52.85% in 2017.<sup>8</sup>

Between Europe in the years 2000 and 2017, the success rate for the surgical treatment of pterygium with conjunctival autograft ranged from 0% to 14.29%.<sup>9-11</sup>

In Dakar in 2010, the success rate of pterygium surgery using conjunctival autograft was 88%.<sup>12</sup>

The scarcity of literature in West Africa, particularly in Mali, has led to the realization of this study whose aim is to evaluate the preliminary result of pterygium excision with conjunctival autograft at the Infirmary of the Bamako Hospital.

## 1.1. Patients and Methods

We conducted a prospective study lasting 17 months from May 2016 to October 2017 in the ophthalmology department of the Infirmary of the Bamako Hospital. We

\* Corresponding author.

E-mail address: [rodrigueuelien@yahoo.fr](mailto:rodrigueuelien@yahoo.fr) (Elien G Y R R).

included in the study all patients who had a primary or recurrent pterygium operated on in the department, consenting, without distinction of age and sex. Excluded from the study were patients received in consultation for an ocular problem other than pterygium or non-consenting patients. The sampling used was non-probability. The study variables were :

1. Socio-demographic indicators: age, sex and occupational status.
2. Clinical data: type, stage and location of pterygium.
3. Therapeutic data: post-operative follow-up according to the following frequency, D1, D7, D15, M1 and M3 and M6.
4. Factors influencing recurrence: recurrence by the age of the patient, recurrence in relation to the type of pterygium, recurrence in relation to the stage of the pterygium.

The clinical examination allowed us to collect the following information: visual acuity (VA) was taken before and after treatment, the values of the measurement of ocular tone if the stage of the pterygium allowed it, the characteristics of the pterygium (size, seat, vascularisation), the pterygions were classified according to the Vaniscotte classification.

The preoperative blood workup included a blood count (CBC), prothrombin level and kaolin cephalin time (TCK).

The technique of pterygium removal associated with conjunctival autograft was the surgical technique performed by the same well-trained ophthalmologic surgeon. The graft is usually harvested from the same eye in the temporal superior bulbar conjunctiva. The conjunctival flap is positioned vertically so that the vascular axes are parallel to the limb, thus preventing recurrence. It is usual to respect a paralimbic space of 2 mm. This technique is simple in that it does not require the use of any heterologous material, and is easy and quick to perform. Post-operative treatment with topical antibiotics was prescribed for 4 weeks.

Data were collected using pre-tested individual survey sheets.

Data entry was performed using EPI-INFO version 6 software. The statistical test used was the Pearson Chi-2 test.

**2. Results**

The mean age in our series was 45.14 years.

Extremes ranged from 20 to 85 years.

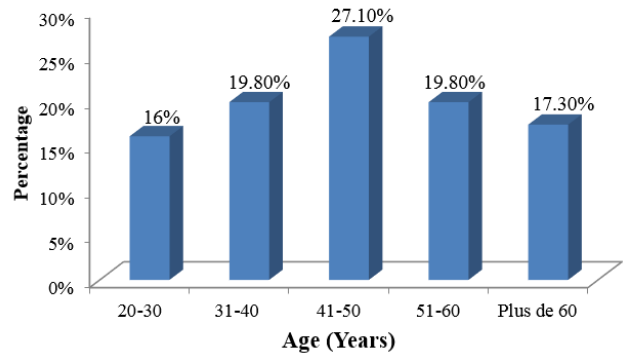
The most common age range was [41-50 years].

There was a male predominance, sex ratio M/F=1.13.

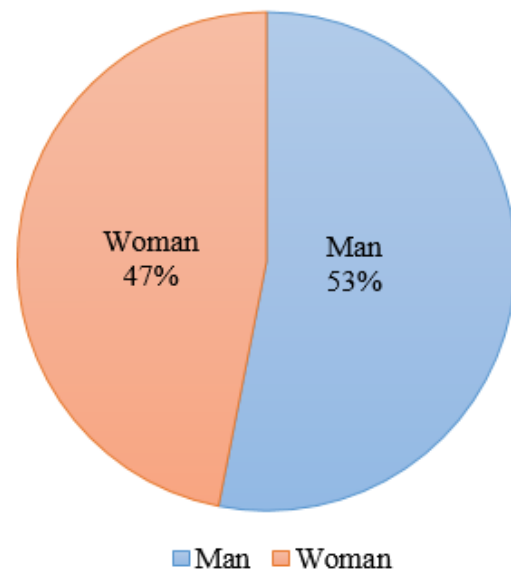
The military dominated the sample at 30.9%, followed by housewives at 19.8%, and labourers and farmers at 12.3% each.

The pterygium was classified at Stage II of the Vaniscottis classification in the majority of cases (56.7%).

The pterygium was of primary type in the majority of cases (84%) and of nasal location in almost all cases (93%).



**Fig. 1:** Age distribution of patients.



**Fig. 2:** Distribution of patients by gender.

**Table 1:** Distribution of patients by profession.

Profession	Number (n)	Percentage (%)
<b>Military</b>	<b>25</b>	<b>30,9</b>
Household	16	19,8
Worker	10	12,3
Cultivator	10	12,3
Retailer	10	12,3
Teachers	05	6,2
student	05	6,2
<b>Total</b>	<b>81</b>	<b>100</b>

**Table 2:** Distribution of Patients by Stage of Pterygium

Stage	Number (n)	Percentage (%)
Stage II	46	56,7
Stage III	23	28,4
Stage IV	12	14,8
<b>Total</b>	<b>81</b>	<b>100</b>

**Table 3:** Distribution of patients by type and location of pterygium.

		Number (n)	Percentage (%)
<b>Type</b>	<b>Primary</b>	<b>68</b>	<b>84</b>
	Recurring	13	16
	<b>Total</b>	<b>81</b>	<b>100</b>
<b>Location</b>	<b>Nasal</b>	<b>75</b>	<b>92,6</b>
	Temporal	02	2,5
	Temporo-nasal	04	4,9
	<b>Total</b>	<b>81</b>	<b>100</b>

The postoperative protocol based solely on the combination of oxytetracycline and dexamethasone ophthalmic ointment (STERDEX®) with morning and evening application in the operated eye was given to all our patients.

Complications observed at the first week of postoperative follow-up were lacrimation (100%), conjunctival hyperhemia (100%) and foreign body sensation (100%). At the second week of postoperative follow-up only subconjunctival hemorrhage (4.9%) and foreign body sensation (12.3%) were observed. At the 3rd and 6th months, there were 04 cases of recurrence (4.9%).

Recurrences were observed in young patients (under 40 years of age).

The recurrence involved pterygions classified as Stage II and above of the Vaniscotte classification.

Pterygium recurrences mainly concerned primary pterygions (3 cases out of 4).

### 3. Discussion

The average age was 45.74%, with extremes ranging from 20 to 85 years. The 41 and 50 year old age group was the most common at 27.1%. The sex ratio was M/F = 1.13. Our results are lower than those found by the authors in Spain<sup>7</sup> and Turkey<sup>8</sup> who found the average age of 55.74 and 55 respectively, and the sex ratio of 1.83 in Spain and 2.69 in Turkey. On the other hand, H KANE et al<sup>12</sup> in Dakar found lower results than ours (mean age = 41.43 ± 14.19 years with extremes of 20 and 80 years. the sex ratio was 0.43). The youthfulness of the African population and the daily exposure of black Africans to ultraviolet rays are thought to be the cause of the early onset of pterygium in melanoderma.

The majority of our patients (87.6%) were in gainful employment, exposing them daily to ultraviolet radiation. This result is consistent with the pathogenesis of pterygium, underlining the primordial role of the cumulative effect of repetitive exposures to ultraviolet radiation.<sup>13</sup>

We noted 56.7% stage II pterygions, 28.4% stage III pterygions and 14.8% stage IV pterygions. Our results

are slightly higher than those found by H KANE et al<sup>12</sup> who observed 58.82% stage II pterygium, 32.36% stage III pterygium and 5.88% stage IV pterygium. The increase in ocular symptoms frequently observed from stage II pterygium would be the cause of the high number of patient consultations at this stage.

There were 68 primary (84%) and 13 recurrent (16%) pterygium pterygions with predominantly nasal location (92.6%). Our observations are identical to those of the authors in Europa<sup>7</sup> but superior to those of H KANE et al<sup>12</sup>, who respectively observed 84.31% and 81.82% primary pterygions and 15.69% and 18.18% recurrent pterygions.

From D1 to D15 postoperatively conjunctival hyperhemia, lacrimation and foreign body sensations were reported in all patients. Subconjunctival hemorrhage, present in 16 patients (19.8%), regressed progressively towards D30 postoperatively. On the other hand, the 2 cases of graft oedema persisted until D60. While Kmiha et al<sup>14</sup> and Kammoun et al<sup>15</sup> reported cases of graft edema, serous cyst of the bulbar conjunctiva, as well as symblepharons associated with recurrences in the order of 10 to 10.3% respectively. Similarly, Tananuvat et al [15] reported cases of ocular hypertonia related to corticosteroid therapy, which was not the case in our study. As with any surgical procedure, surgical treatment of pterygium is not without complications. These complications vary according to the technique used, the clinical conditions of the patient and the dexterity of the surgeon.

In our study, pterygium recurrence was observed in young adult patients (under 40 years of age) and involved primary pterygium from stage II onwards, with recurrence occurring between the 3rd and 6th month of postoperative follow-up. Whereas in Senegal H KAN<sup>12</sup> et al. had observed a mean recurrence time of 30 days postoperatively, this recurrence concerned 12.5% of cases, i.e. 4 pterygions, of which 3 were primary (2 stage IV and 1 stage III) and 1 recurrence (stage II). The high intensity of the cellular phenomena observed during the healing process in the young subject would justify our results.

### 4. Conclusion

Limbo-conjunctival autograft appears to us as the reference surgical technique in the surgical treatment of pterygions. It has the advantage of restoring the most physiological ocular surface possible by bringing limbic stem cells, at the very heart of the physiopathogeny of this condition, and of using an autologous graft without the risk of an immunological rejection reaction.

The results of our study allow us to consider this technique as one of the safest and giving a very low rate of recurrence and fewer post-operative complications.

**Table 4:** Distribution of patients according to post-operative complications

Post opératives complications	D1-7		D8-15		D30		M3-6	
	n	%	n	%	n	%	n	%
Tearing	<b>81</b>	<b>100</b>	00	00	00	00	00	00
conjunctival Hyperhemia	<b>81</b>	<b>100</b>	00	00	00	00	00	00
Hémorrhage s/conjunctival	16	19,8	<b>04</b>	<b>4,9</b>	00	00	00	00
Sensation of foreign body	<b>81</b>	<b>100</b>	<b>10</b>	<b>12,3</b>	00	00	00	00
Graft edema	02	2,5	02	2,5	<b>01</b>	<b>1,2</b>	00	00
Recidivism	00	00	00	00	00	00	<b>04</b>	<b>4,9</b>

**Table 5:** Distribution of patients according to factors influencing pterygial recurrence.

Influencing factors	Recidivism -		Recidivism +		Total
	n	%	n	%	
<b>Age (years)</b>					
20 - 30	<b>11</b>		<b>2</b>		<b>13</b>
31 - 40	<b>14</b>		<b>2</b>		<b>16</b>
41 - 50	22		0		22
51 - 60	16		0		16
60 years and more	14		0		14
<b>Total</b>	<b>77</b>		<b>4</b>		<b>81</b>
<b>Ptérygium Staging</b>					
Stage II	45		1		46
<b>Stage III</b>	<b>22</b>		<b>1</b>		<b>23</b>
Stage IV	<b>10</b>		<b>2</b>		<b>12</b>
<b>Total</b>	<b>78</b>		<b>4</b>		<b>81</b>
<b>Type of pterygium</b>					
Primary	<b>65</b>		<b>3</b>		<b>68</b>
Recurrences	12		1		13
<b>Total</b>	<b>77</b>		<b>4</b>		<b>81</b>

**5. Source of Funding**

IOTA-teaching hospital research fund.

**6. Conflict of Interest**

None.

**References**

1. Szwarcberg J, Flament J, Pterygium. *Encycl Med Chir Ophtalmol*. 2001;21(135):A-10.
2. Ang M, Li X, Wong W, Zheng Y, Chua D, Rahman A, et al. Prevalence of and racial differences in pterygium a multiethnic population study in Asians. *Ophthalmol*. 2012;119(8):1509-15.
3. Luthra R, Nemesure BB, Wu SY. Frequency and Risk Factors for Pterygium in the Barbados Eye Study. *Arch Ophthalmol*. 2001;119:1827-32.
4. Ugurbas S. Comparing techniques for pterygium surgery. *Clin Ophthalmol*. 2008;3:69-74.
5. Sarda V, Gheck L, Ghaine G. *Encycl Med Chir Ophtalmol Paris: Elsevier-Masson*. 2009;21(135):A-10.
6. Huerva V, March A, Martinez-Alonso M, Muniesa MJ, Sanchez C. Pterygium surgery by means of conjunctival autograft: long term follow-up. *Arq Arm Oftalmol*. 2012;75(4):251-5.
7. Bilge AD. Comparison of conjunctival autograft and conjunctival transposition flap techniques in primary pterygium surgery. *Saudi J Ophthalmol*. 2018;32(2):110-3.
8. Gris O, Güell J, Campo ED. Limbal-conjunctival autograft transplantation for the treatment of recurrent pterygium. *Ophthalmol*. 2000;10(7):270-3.
9. Mak RK, Chan TC, Marcet MM, Choy BN, Shum JW, Shih KC, et al. Use of anti-vascular endothelial growth factor in the management of

10. pterygium. *Acta Ophthalmol*. 2017;95:20-7.
10. Kampitak K, Leelawongtawun W, Leeamornsiri S, Suphachearaphan W. Role of artificial tears in reducing the recurrence of pterygium after surgery: a prospective randomized controlled trial. *Acta Ophthalmol*. 2017;95(3):e227-9.
11. Kane H, Roth PN, Sow A, Wane A, Ndiaye JM, Elhakour I. Surgical treatment of pterygium in melanoderma: comparative results between conjunctival autograft versus mitomycin C. *Revue SOAO - N° 01 - 2016*;p. 39-44.
12. Kmiha N, Kammoun B, Trigui A. Contribution of conjunctival autograft in pterygial surgery. About 52 cases. *J Fr Ophtalmol*. 2002;24(7):729-32.
13. Tananuvat N, Martin T. The Results of Amniotic Membrane Transplantation for Primary Pterygium Compared with Conjunctival Autograft. *Cornea*. 2004;23(5):458-63.
14. Kammoun B, Kharrat W, Zouari K. Pterygium: surgical treatment. *J Fr Ophtalmol*. 2001;24(8):823-8.

**Author biography**

**Bakayoko Seydou** Executive Director

**Sidibe Mohamed Kolé** Ophthalmologist

**Elie G Y R R** Resident

**Cite this article:** Seydou B, Kolé SM, Elie G Y R R . **Surgical treatment of pterygium in melanoderma: Preliminary results of the conjunctival autograft at the infirmary of bamako hospital.** *IP Int J Ocul Oncol Oculoplasty* 2020;6(3):175-178.