



## Case Report

# A case report on bilateral retinocytoma

Amritjeet Kaur<sup>1,\*</sup>, Christina Daisy Philips<sup>1</sup>

<sup>1</sup>Dept. of Ophthalmology, Osmania Medical College, Hyderabad, Telangana, India



### ARTICLE INFO

#### Article history:

Received 23-02-2020

Accepted 02-05-2020

Available online 30-06-2020

#### Keywords:

Retinocytoma

Retinoblastoma

Case report

Bilateral retinal tumor

### ABSTRACT

We report a case of a 28 year old female with bilateral retinocytoma diagnosed on evaluation after the diagnosis of her third offspring as having bilateral retinoblastoma.

© 2020 Published by Innovative Publication. This is an open access article under the CC BY-NC license (<https://creativecommons.org/licenses/by-nc/4.0/>)

## 1. Case Report

A 28 year old female; with her three kids diagnosed as retinoblastoma was referred to us for evaluation. She was a mother to 5 kids, 3 girls and 2 boys; out of which 3 kids were affected with retinoblastoma. There was no complaints of retinoblastoma in her siblings and parents.

The patient had no ocular complaints. She had no comorbidities and had never had any prior ocular examinations. Her visual acuity was 6/6 in both the eyes. Anterior segment was normal with normal pupillary reactions. Considering the history of retinoblastoma in her offspring; we decided to do a dilated fundus examination.

On fundoscopy with an indirect ophthalmoscope, right eye showed a 5.5mm×4.5mm translucent whitish lesion on the inferior temporal part of mid peripheral retina. There was a surrounding area of chorioretinal atrophy.

Left eye showed a 8mm×5.5mm juxtapapillary greyish translucent lesion, situated nasal to the disc, with two cottage cheese calcifications. chorioretinal atrophy and surrounding RPE hyperplasia was seen. Optic disc and vessels looked normal and macula (OU) was healthy.(Figures 1 and 2)

IOP was normal and extraocular movements were full and free. Systemic examination was normal.

On B scan ultrasonography, (BE) localised thickening of the retina with irregular spikes was seen. Vitreous cavity was echofree. Figure 3

CT orbits and brain was normal. (Figure 4)

The provisional diagnosis for our patient was bilateral retinocytoma/ retinoma based on , age of presentation, good visual acuity, the characteristic fundus findings described in literature and the imaging findings.

Our patient was advised regular long term follow up and was made aware about the risk to her offspring in future offspring.

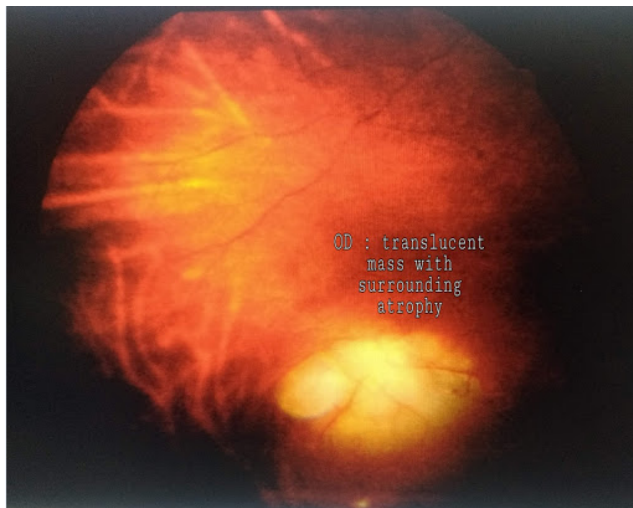
**Table 1:** Common findings on fundus in retinocytoma

Fundus findings in retinocytoma (5,1)

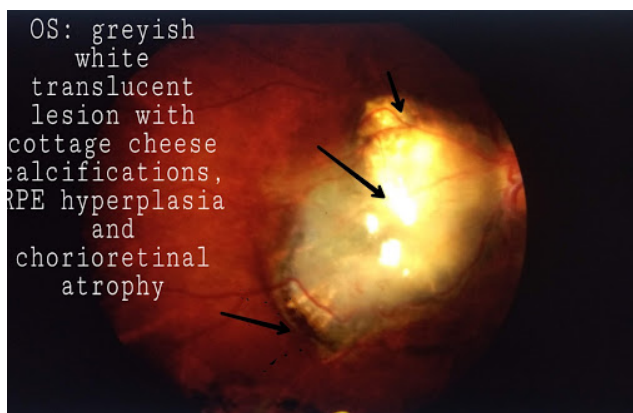
1. Grey translucent color
2. Cottage cheese calcifications
3. RPE hyperplasia
4. Chorioretinal atrophy rare
5. Localised vitreous seeding.

\* Corresponding author.

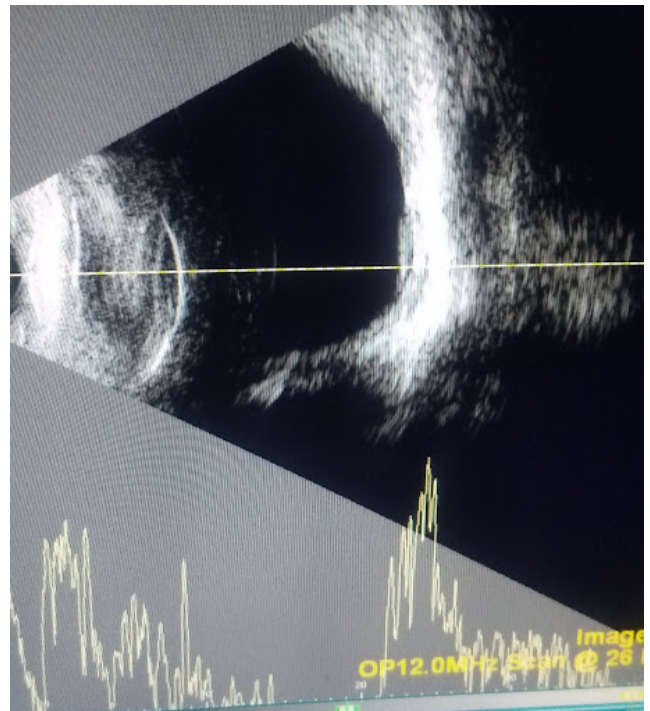
E-mail address: [amritjeetkaur2110@gmail.com](mailto:amritjeetkaur2110@gmail.com) (A. Kaur).



**Fig. 1:** Fundus findings in right eye



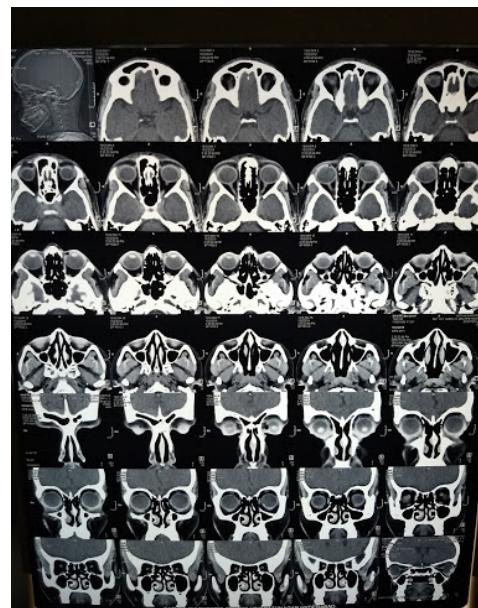
**Fig. 2:** Fundus findings in left eye



**Fig. 3:** B scan findings

## 2. Discussion

Retinocytoma<sup>1</sup>/ retinoma<sup>2</sup> is the benign variant of retinoblastoma; the affected proband of 13q14 involving the RB1 gene remains the same. The clinical features were first described by Gallie and coworkers.<sup>2</sup> It included presence of a translucent grey mass, cottage cheese calcifications<sup>3</sup> and RPE hyperplasia. The fourth clinical feature of chorioretinal atrophy was added later.<sup>4</sup> According to a retrospective case series done on patients with retinocytoma(5); a combination of at least two features was found in 71% and a combination of three features were found in 33% of the cases.<sup>5</sup> Inclusion of chorioretinal atrophy, increased the diagnostic yield for any combination of at least 2 and 3 features.(TABLE -1). Our patient had grey translucent mass, intralesional calcifications in the right eye. The left eye showed additional RPE alteration. Both lesions showed surrounding chorioretinal atrophy that established the diagnosis of bilateral retinocytoma.



**Fig. 4:** CT findings

Histopathologically, retinocytoma comprises of the benign appearing, well differentiated retinal cells without evidence of mitosis and necrosis.<sup>1</sup> Most of the RB1 gene mutations have a high penetrance of 90%. A few mutations however can lead to a low penetrance and lead to the development of retinocytoma.

1. Truncating mutations/missense mutations of the RB1 gene results in RB protein that retains its functioning partially and manifests as retinocytoma<sup>6,7</sup>
2. Survival gene hypothesis: coevolution of MED4/RB1 gene locus proves to be protective against large deletions of the RB1 gene locus. Hence MED4 can be considered an essential survival gene
3. Senescence: A senescence protein (p16INK4A) is capable of arresting the proliferative cells at the G1 phase of the cell cycle. This protein is overexpressed during early stages of the retinoma and its depletion leads to progression to retinoblastoma.<sup>8</sup>
4. Timing of the second hit: Hypothetically the second allelic inactivation (M2) occurs during the later stages of the cell division when the cell is incapable of accumulation adequate genomic instability to progress to the Retinoblastoma.

Malignant transformation of retinocytoma to retinoblastoma is very rare, about 4%.<sup>5</sup> Development of secondary malignant tumors and pineal tumors is also rare due to the similar protective mechanisms that prevent development of malignant retinal tumor.<sup>3,5,9</sup> Nonetheless, long term follow up of patients is necessary to detect early progression to retinoblastoma.

Retinocytoma and retinoblastoma can co exist in the same family.<sup>5</sup> Examination of first degree relatives (parents) is important whenever a new case of retinoblastoma is diagnosed. This has major implications in genetic counselling. Our patient had three out of five kids affected with retinoblastoma and was neither examined nor counselled regarding the risks to her future offspring.

### 3. Source of Funding

None.

### 4. Conflict of Interest

None.

### References

1. Hidayat MC, Kopelman A, Zimmerman J, Retinocytoma LE. A benign variant of retinoblastoma. *Arch Ophthalmol*. 1983;10(1):1519–31.
2. BAellsworth G, Abramson RM, Phillips DH, Retinoma RA. Spontaneous regression of retinoblastoma or benign manifestation of the mutation? *Br J Cancer*. 1982;4(5):513–21.
3. Potter PD, Shields CL, Shields JA. Clinical variations of trilateral retinoblastoma: a report of 13 cases. *J Pediatr Ophthalmol Strabismus*. 1994;34(1):26–31.
4. Balmer A, Munier F, Gailloud C. Retinoma: case studies. *Ophthalmic Paediatr Genet*. 1991;12(3):131–7.
5. Singh AD, Santos M, Shields CL, Shields JA, Eagle RC. Observations on 17 Patients with Retinocytoma. *Arch Ophthalmol*. 2000;118(2):199–205.
6. Onadim Z, Hogg A, Baird PN, Cowell JK. Oncogenic point mutations in exons 20 of the RB1 gene in families showing incomplete penetrance and mild expression of the retinoblastoma phenotype. *Proc Natl Acad Sci*. 1992;89(13):6177–81.
7. Kratzke RA, Otterson GA, Hogg A, Coxon AB, Geradts J, Cowell JK, et al. Partial Inactivation of the RB Product in a Family With Incomplete Penetrance of Familial Retinoblastoma and Benign Retinal Tumors. *Oncogene*. 1994;9(5):321–6.
8. Dimaras H, Corson TW, Cobrinik D, White A, Zhao J, Munier FL, et al. Retinoblastoma. *Nat Rev Dis Primers*. 2015;1:15021.
9. Marcus DB, Seleft G. Trilateral retinoblastoma: insights into histogenesis and management. *Surv Ophthalmol*. 1998;43(1):59–70.

### Author biography

**Amritjeet Kaur** Resident

**Christina Daisy Philips** Resident

**Cite this article:** Kaur A, Philips CD. A case report on bilateral retinocytoma. *IP Int J Ocul Oncol Oculoplasty* 2020;6(2):133-135.