



Original Research Article

Long term evaluation of pterygium excision with conjunctival autografting using autologous blood

Teena Agrawal^{1,*}, Mahesh Agrawal²¹Consultant Ophthalmologist, Centre For Sight, Indore, Madhya Pradesh, India²Dept. of Cataract & Refractive Surgery, Shri Ganesh Netralay, Indore, Madhya Pradesh, India

ARTICLE INFO

Article history:

Received 13-04-2020

Accepted 28-05-2020

Available online 30-06-2020

Keywords:

Conjunctival auto grafting CAG

Sutureless

Glue less

Autologous blood

Graft host junction gap

Pterygium

ABSTRACT

Aim: To evaluate the long term outcome of pterygium excision with conjunctival autografting (CAG) using economically viable autologous blood.

Materials and Methods: This is a retrospective analysis of total 40 patients who underwent Pterygium excision with CAG using autologous blood as per our inclusion and exclusion criterion. After pterygium excision by avulsion method, we put the 1mm oversized CAG using autologous blood oozing on bare sclera and margins were tucked. Gentle massage for 10 minutes was given. The patients were followed for 48 months to measure the outcome.

Results: Our study shows CAG with autologous blood is very effective with zero percent recurrence and retraction of graft. Only in 1 case (2.5%) we have identified gap in graft-host junction as long term complications. This also does not require any intervention as gap was < 1mm.

Conclusion : Our study shows long term safety, success of economically viable CAG with autologous blood following pterygium excision.

© 2020 Published by Innovative Publication. This is an open access article under the CC BY-NC license (<https://creativecommons.org/licenses/by-nc/4.0/>)

1. Introduction

Pterygium is a degenerative sub-conjunctival tissue proliferation along with overlying conjunctiva in a triangular fashion, approaching from limbus to papillary centre. It is well known entity for thousands of year BC. It was first described by the great Indian Physician & Surgeon, also known as father of Plastic surgery, Sushruta.^{1,2}

The etiology or cause of pterygium is largely unknown, 9 but mostly it is attributed to exposure of UV radiation 10 hot air and dusty wind.^{3,4} The medical management is largely oriented towards temporary symptomatic relief to the patient, while Surgery is the mainstay treatment in present scenario.⁵⁻⁸ The scope of surgery varies from traditional Pterygium excision with bare sclera to modern Robotic Pterygium Surgery.⁹ In present era, the most widely accepted technique is Conjunctival Autografting (CAG) with different techniques like suture, fibrin glue, autologous

serum.⁵⁻⁸

This is a retrospective study. All patients had been operated between April 2014 to April 2015. Our aim of the study was to report recurrence and acceptance of graft with complication present, if any.

2. Materials and Methods

This is a retrospective clinical study. We have included total 40 patients in our study matching our inclusion criterion. Our inclusion and exclusion criterion were as follows-

2.1. Inclusion criteria

1. Age group 18-80 Yrs.
2. Symptomatic patients like foreign body sensation, watering, burning, redness in eyes.
3. Grade 2-4 pterygium approaching papillary area.
4. Patient with follow-up of 48 months.

* Corresponding author.

E-mail address: G.teena@hotmail.com (T. Agrawal).

2.2. Exclusion criteria

1. Recurrent Pterygium,
2. Double Head Pterygium,
3. Any other ocular disease except Cataract,
4. Abnormal bleeding profile or patient on Anticoagulant,
5. HIV positive cases,
6. Immunosuppression.

On 48 months follow-up, patient was examined for Graft retraction, rejection, granuloma or any other complication as well as recurrence.

2.3. Pre-Operative Evaluation

All patient underwent routine OPD procedures like complaints and history taking, Vision assessment and Refraction, IOP, Slit lamp examination, 90D. All patients, who met our inclusion criteria and passed on OPD examination, were counseled well before surgery and Informed consent was taken from them and relatives before surgery. We have followed standard guidelines and adhered to the tenets of Declaration of Helsinki.

2.4. Procedure

The eye was anaesthetized using 0.5% Proparacaine solution 3-4 times, 10 minutes apart, preoperatively. The procedure was simple avulsion of pterygium head from corneal bed and thereafter body of pterygium was dissected from sclera and excised. Minor bleeding point was not cauterized while major bleeding point, if any, was cauterized with bipolar cautery. The remnants of conjunctival tissue was scrapped off from cornea using 15 No surgical blade. Bare sclera was measured carefully using Castroviejo calipers. The conjunctival autograft (1mm more from bare sclera size) was taken from supero-temporal quadrant avoiding tenon's tissue. Oozing of blood from minor blood vessels was confirmed and autograft was placed, taking care of limbal orientation. The graft was tucked under the conjunctiva near the margin and was gently ironed with the help of curved suturing forceps for 10 minutes until adherence was confirmed with gentle touch of sponge at the edge of graft. Eye was patched after putting Moxifloxacin and Dexamethasone combination drops. The patients were examined on Post-Operative Day 1, 1 week, 1month, 6 months and 48 months for graft edema, hemorrhage, retraction, loss or rejection. Routine postoperative medication of Moxifloxacin with Dexamethasone eye drop started in tapering dose and continued for 6 weeks.

3. Results

In our study total 40 patients enrolled as per inclusion criterion. The age ranged from 20 yrs. to 77 yrs. of age

with an average age 45.3. In our study male:female ratio is 1:1, i.e. 20 Male & 20 Female. All pterygium was Nasal in location. In 40 patients, 23 Right eyes and 17 Left eyes operated upon. All patients had been operated for cosmesis and various symptoms like redness, burning sensation, pain, headache etc.

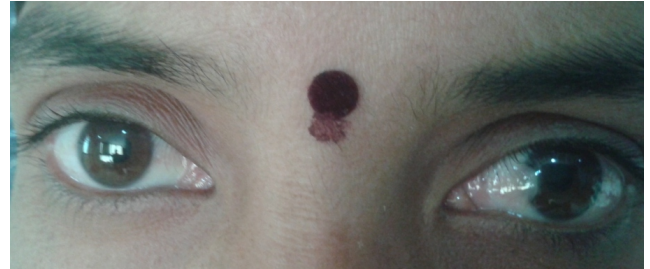

Fig. 1: Female PTR Preop

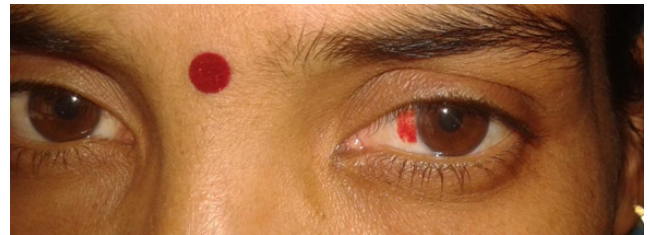

Fig. 2: Graft hemorrhage on 1 week follow-up

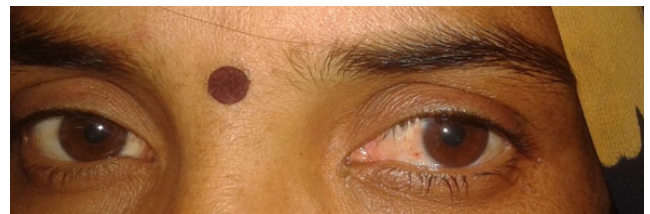


Fig. 3: 1 month follow-up

In our study the maximum number of patients, 34(85%) were between age of 20-60 yrs. of age, and minimum numbers 6 patients (15%) in between 61-80 yrs. of age. In our study 16 patients (40%) were operated in young age between 20-40 yrs. due to cosmetic reason.

Table 2 shows the laterality of pterygium in comparison to age distribution. It is clear that unilateral pterygium is more common in young population without any sex predilection while bilateral pterygium is seen commonly in 41-60 yrs of age group.

From table 3 we can see that, on 1 week follow-up, graft edema was noted in 13 cases (32.5%) with small size graft (5*5mm), which was done mostly in younger age group while retraction was noted in 4 cases (10%) where graft size was large (5*7 mm or more). Also note that there was only 1

Table 1:

Age group	Male	Female	Total
20-40	7	9	16
41-60	9	9	18
61-80	4	2	6
Total	20	20	40

Table 2:

Age group	Unilateral		Bilateral		Grand total
	Male	Female	Male	Female	
20-40	6	9	1	0	16
41-60	1	1	8	8	18
61-80	0	0	4	2	6
Total	7	10	13	10	40

Highlighted number shows higher number of cases in particular group

Table 3:

Graft Size	1ST WEEK			48 MONTHS FOLLOW UP						
	G Edema	G Hhge	G Retraction	G Stability	G Rejection	Any other Complication	G Retraction	G Stability	G Rejection	Any other Complication
5*5	13	0	0	28	0	0	0	28	0	0
5*6	0	1	0	4	0	0	0	4	0	0
5*7	2	1	1	5	0	0	0	5	0	0
7*8	1	1	2	2	0	1#	0	2	0	1#
7*9	1	0	1	1	0	0	0	1	0	0
Total	17	3	4	40	0	1	0	40	0	1

Graft –host junction gap

case (2.5%) of gap in graft-host junction but no intervention was done as gap was less than 1mm and well epithelialised.

On 48 months follow-up, all the 40 cases were having stable graft without any complication except 1 case (2.5%) where a minimal gap (<1mm) was noted between graft and host conjunctival junction in large graft of 7*8mm. No intervention was done for this case as the gap was minimal with no exposed episcleral tissue. Although there are many reported complications⁵⁻⁸ like granuloma formation, graft rejection, recurrence but we have not noted any long term complications except minimal graft-host junction gap in 1 case.

4. Discussion

There are several indications for pterygium surgeries, including cosmesis, watering, redness, burning sensation.¹⁰ Also there are different techniques of conjunctival autografting using Sutures, fibrin glue and autologous serum with different outcomes.^{11,12} There are multiple advantages of using autologous blood for graft adhesion compared to fibrin glue like no risk of acquired infection like Parvovirus and HIV, less chances of inflammation and the most importantly low cost.

In our study, all 40 grafts were stable and well accepted without any graft loss or recurrence, comparable with other studies like Kulthe et al,¹⁰ Sharma et al,¹³ Roopa KS et al.¹⁴ In Kulthe et al¹⁰ study, they studied 79 eyes, Sharma et al studied 25 eyes and Roopa KS et al¹⁴ studied 50 eyes for 6 months with zero recurrence rate. Our study followed the patient for 48 months with zero recurrence rates. Hemlatha BC et al¹² had also reported zero recurrence rate in 6-30 months of follow-up. Thatte S et al¹⁵ had followed cases for 6 months to 5 yrs. and reported recurrence in 3 cases (1.98%) in large and fleshy primary pterygium.

However in our study, we have noted a minimal gap (< 1mm) between graft-host junctions without exposure of underlying episclera, on 48 months follow up as long term complication. In this case, larger graft size of 7*8mm was used. This gap was noted on 1 week follow-up also but no intervention was done as this was minimal and well epithelialized. Suryavanshi MP et al¹⁶ also reported graft-host junction gap in 7 eyes (20%) which healed completely and epithelialised in 1 month. Thatte S et al¹⁵ had not reported any case of graft-host junction gap in their study of 151 eyes.

There are studies reporting graft retraction and graft losses^{10,14} in 6 months follow-up but there was no confined

reason put behind. We tried to improve outcome of CAG by increasing graft size to 1mm and tucking under the host conjunctiva as it gives more mechanical stability, we can hypothesize. On literature search we found similar study done by Roopa KS et al¹⁴ and Kulthe et al,¹⁰ in later study graft size was only 0.5mm oversized. There has not been any study showing advantage or disadvantage of taking oversized graft. Elwan SA¹⁷ reported early retraction of graft in 6 eyes (12%) due to graft edema and chemosis where glue was used for Autografting which was managed well by medical management. Only one case required suturing in their study, though they have not mentioned the graft size in patient who underwent suturing. In our study also there was 1 case (2.5%) with early graft retraction, graft size was 7*9mm, which subsided with medical management after 1 week. Thatte S et al¹⁵ has also reported retraction in 9 case (5.96%) where graft size was bigger (>7-5mm) which correlates well with our study.

Our study also shows similar short term signs and complications like graft edema, graft hemorrhage, early graft retraction as in other studies.^{10,12–14,16} but most of the complications resolved in long term as shown in table 3.

5. Conclusion

Our study confirms the long term success and safety of conjunctival autografting using autologous blood. Moreover it's an economical and risk free method of sutureless, glueless autografting after pterygium excision.

6. Limitations

All retrospective study has the limitation of bias, although we have tried to rule out bias by choosing patients randomly. Also the sample size is small in our study but strength of our study is long term follow-Up. We further suggest prospective, multicentric clinical study of different types of pterygium surgery with long term outcome.

7. Source of Funding

None.

8. Conflict of Interest

None.

References

1. Champaneria MC, Workman AD, Gupta CS. Sushruta: father of plastic surgery. *Ann Plast Surg.* 2014;73(1):2–7.

2. Kansupada KB, Sassani JW. Sushruta: The father of Indian surgery and ophthalmology. *Doc Ophthalmol.* 1997;93(1-2):159–67.
3. Moran DJ, Hollows FC. Pterygium and ultraviolet radiation: a positive correlation. *Br J Ophthalmol.* 1984;68(5):343–6.
4. Nakaishi H, Yamamoto M, Ishida M, Someya I, Yamada Y. Pingueculae and Pterygia in Motorcycle Policemen. *Ind Health.* 1997;35(3):325–9.
5. Malik K, Goel R, Gupta SK, Kamal S, Malik VK, Singh S, et al. Efficacy of sutureless and glue free limbal conjunctival autograft for primary pterygium surgery. *Nepal J Ophthalmol.* 2012;4:230–5.
6. Bhargava P, Kochar A, Joshi R. A novel technique - Pterygium excision followed by sutureless and gluefree conjunctival autografting. *Acta Medica Scientia.* 2015;(6):2.
7. Babu PS, Lavanya TG, Shreeraja P, Praveenkumar Y, Raviprakash D. Autograft technique for pterygium surgery with no glue and no suture -cut and paste: Our experience. *Int J Ocular Oncol Oculoplasty.* 2016;2:186–9.
8. Smolin T. The Cornea – Scientific Foundations and Clinical Practice; Pterygium and its Surgery ;p. 999–1017.
9. Bourcier T, Chammas J, Becmeur PH, Danan J, Sauer A, Gaucher D, et al. Robotically Assisted Pterygium Surgery. *Cornea.* 2015;34(10):1329–30.
10. Kulthe SB, Bhosale A, Patil P, Pandve H. Is the surgical technique of a sutureless and glue-free conjunctivolimbal auto graft after pterygium excision complications free? *Med J DY Patil Univ.* 2015;8(3):308–12.
11. Karandikar S, Shanbag NU, Chen L; Available from: <https://www.semanticscholar.org/paper/Comparison-of-three-different-techniques-for-of-in-Karandikar-Shanbhag/1cc37f9ddbefba7568ab114363f1b7d2f76caef>.
12. Hemalatha B, Pradeep, Shetty S, Malavika K. Comparison between sutureless conjunctival autograft using autologous blood versus sutured limbal conjunctival autograft in primary pterygium surgery. *IP Int J Ocul Oncol Oculoplast.* 2016;2(3):177–80.
13. Sharma A, Raj H, Gupta A, Raina AV. Sutureless and gluefree versus sutures for limbal conjunctival autografting in primary pterygium surgery: A prospective comparative study. *J Clin Diagn Res.* 2015;9:6–9.
14. Roopa KS, Sudha R, Firdous SG, Lakshmi DM, , and. Autologous in situ blood coagulum as bioadhesive in preventing the recurrence of pterygium. *IP Int J Ocul Oncol Oculoplasty.* 2019;5(4):238–42.
15. Thatte S, Dube A, Sharma S. Efficacy of autologous serum in fixing conjunctival autografts of various sizes in different types and grades of pterygium. *J Ophthalmic Vis Res.* 2019;14(2):136–43.
16. Isaac R, Suryawanshi M, Suryawanshi M. Pterygium excision with conjunctival autograft fixed with sutures, glue, or autologous blood. *Oman J Ophthalmol.* 2020;13(1):13.
17. Elwan SAM. Comparison between sutureless and glue free versus sutured limbal conjunctival autograft in primary pterygium surgery. *Saudi J Ophthalmol.* 2014;28(4):292–8.

Author biography

Teena Agrawal Consultant Ophthalmologist

Mahesh Agrawal Director and Consultant Ophthalmologist

Cite this article: Agrawal T, Agrawal M. Long term evaluation of pterygium excision with conjunctival autografting using autologous blood. *IP Int J Ocul Oncol Oculoplasty* 2020;6(2):118-121.