



Original Research Article

PRP in acromio-clavicular joint arthritis – A prospective analysis

Ramesh Raja C¹, Sudhakar T^{1,*}, Jambukeswaran PST¹, Ugeneshwaran M¹, Anil Gowtham Manivannan²¹Dept. of Orthopaedic Surgery, Government Medical College & ESI Hospital, Coimbatore, Tamil Nadu, India²Aradhana Hospital, Pollachi, Coimbatore, Tamil Nadu, India

ARTICLE INFO

Article history:

Received 15-11-2020

Accepted 17-12-2020

Available online 15-01-2021

Keywords:

Acromioclavicular joint (ACJ)

NSAIDs.

ABSTRACT

Background: The acromioclavicular joint pathologies are one of the common causes of shoulder pain. The most common of these is the acromioclavicular joint arthritis. The management can be conservative or surgical. The conservative measures include activity modification, physiotherapy, Non-Steroidal Anti-Inflammatory Drugs (NSAIDs), and Intra-articular Steroid Injections (ISI). ISI has been used with variable success rates and the long-term effects are doubtful.

Materials and Methods: Patients with clinical and radiological evidence of ACJ arthritis and not responding to exercise and NSAIDs for 2 months were enrolled for PRP injection. 1 mL of PRP prepared by the manual double spin method was injected into the ACJ and patients were followed for a minimum period of 6 months. Constant Score was used to measure the functional recovery at 1, 3, and 6 months post-injection therapy.

Results: 13 patients including 16 shoulders were followed up for an average of 8 months (6 to 14 months). 3 patients had bilateral ACJ involvement. 4 had left ACJ involvement and the rest had right side involvement. The mean pre-injection constant score was 45 (range 28-70). The mean score at the end of 1 month follow up was 69 (range 56-89). At the end of 3 months, the mean score was 81 (range 63-93). Both were statistically significant improvements when compared to the pre-injection score (P=0.003, 0.0021 respectively). At the end of 6 months, the score was 89 (range 58-94). This sequential improvement was not however statistically significant.

Conclusion: ACJ arthritis is one of the common causes of shoulder pain. In our pilot study, PRP has been a promising option to treat primary ACJ arthritis. Future RCTs are needed to establish it as a superior option in the management of ACJ arthritis.

© This is an open access article distributed under the terms of the Creative Commons Attribution License (<https://creativecommons.org/licenses/by/4.0/>) which permits unrestricted use, distribution, and reproduction in any medium, provided the original author and source are credited.

1. Introduction

Acromioclavicular joint (ACJ) is regarded as a “forgotten joint”.^{1,2} Though the emphasis has always been on the much larger glenohumeral joint, the acromioclavicular joint pathologies are one of the common causes of shoulder pain.³ The most common of these is the acromioclavicular joint arthritis.⁴ This can be primary or secondary to trauma or sepsis. The diagnosis is crucial. The patient presents with anterior or superior shoulder pain. Glenohumeral

joint pathologies like cuff tear, instability, arthritis, and impingement syndrome should be ruled out.

The management can be conservative or surgical.⁵ There is a lacuna in the literature regarding the exact protocol for their management. Surgery is generally advised if the symptoms do not improve after a trial of conservative management for a period of more than six months.⁶ The conservative measures include activity modification, physiotherapy, Non-Steroidal Anti-Inflammatory Drugs (NSAIDs), and Intra-articular Steroid Injections (ISI). ISI has been used with variable success rates and the long-term effects are doubtful.⁷

* Corresponding author.

E-mail address: mtrs777@yahoo.com (Sudhakar T).

With the advent of Platelet Rich Plasma (PRP), it has been tried in various inflammatory conditions and tendinopathies with promising results.⁸ The results of intra-articular injection of PRP in osteoarthritis of knee and hip have also proven to be useful.⁹ In this study, we have evaluated the results of PRP in ACJ arthritis in patients who failed to respond to exercise and NSAIDs.

2. Materials and Methods

A diagnosis of ACJ arthritis was made based on the clinical and radiological features. A patient with shoulder pain in whom the cuff pathology, instability, and impingement were ruled out, with clinical features of ACJ arthritis, like tenderness on ACJ, positive scarf sign (positive passive adduction compression test), painful abduction beyond 140 degrees, and restricted internal rotation was radiographically evaluated. When there is radiographic correlation, a diagnosis of ACJ arthritis was made. The patients were started on physiotherapy and NSAIDs. Those patients that were not responding for 2 months on this treatment or those that were worsening were counseled for PRP injection. Patients who were willing were enrolled in the study. Patients with pre-existing other shoulder pathologies, those less than 18 years old, and those with inflammatory arthritis were excluded from the study.

The PRP was prepared by manual double spin method according to the institute's protocols. 20 mL of venous blood with sodium citrate was centrifuged at 1000 RPM for 10 minutes followed by 1500 RPM for 10 minutes. 1 mL of PRP was then injected into the ACJ under aseptic precautions.

Patients were evaluated at follow-up using the Constant score at follow up. Statistical analysis was performed using SPSS (IBM version 25). Paired data were analyzed using the paired t-test.

3. Results

14 patients including 17 shoulders were included in the study of which one patient lost to follow up. The remaining 13 patients including 16 shoulders were followed up for an average of 8 months (6 to 14 months). The average age at the time of injection was 51 years (range: 32-63 years). 3 patients had bilateral ACJ involvement, 4 had left ACJ involvement and the rest had right side involvement. 8 were male patients and 5 were females. All patients had primary ACJ arthritis. The mean pre-injection constant score was 45 (range 28-70). The mean score at the end of 1 month follow up was 69 (range 56-89). At the end of 3 months, the mean score was 81 range (63-93). Both were statistically significant improvements when compared with each other and to the pre-injection score ($P=0.003, 0.0021, 0.04$ respectively). At the end of 6 months, the score was 89 range (58–94). This sequential

improvement was not however statistically significant.

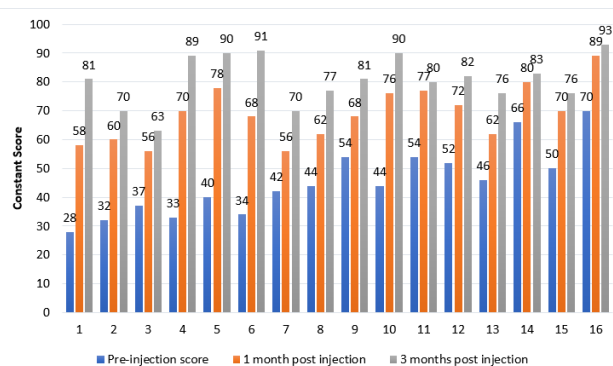


Fig. 1: Comparison of Constant scores of 16 shoulders pre and post-injection

4. Discussion

Arthritis of the ACJ is the common cause of ACJ pain. It results because of the repeated strain at the joint particularly in persons with repeated overhead use of the shoulder involving lifting activities. There are degenerative and osteolytic changes in the distal clavicle.¹⁰ The management involves a conservative trial followed by arthroscopic or open distal clavicular resection in cases with persistent symptoms.⁵

PRP has been the discovery of the last decade in musculoskeletal medicine.^{11,12} It's supposed effectiveness, apparent lack of side effects, autologous nature, low cost, and promising scope has made us try it for various chronic conditions. Starting with tendinopathies it has been tried in managing wound complications and as a means of postponing surgery in degenerative conditions like osteoarthritis of knee.^{13–15}

PRP is a cocktail with supraphysiological levels of platelets.¹⁶ These when activated release a high concentration of various growth factors including but not limited to basic fibroblast growth factor, transforming growth factor, vascular endothelial growth factor, platelet-derived growth factor, and epidermal growth factor among others. These growth factors are purported to have a supra-physiological healing effect on the tissues that they come in contact with. The exact mechanism of such an effect and the exact concentration of growth factors needed are still not clear. Generally, researchers agree that the platelet concentration of five to six times the normal is required.¹⁷ The rationale of the use of PRP in osteoarthritis has been its chondroprotective and regenerative effect.¹⁸ Activated platelets suppress the release of nuclear factor K beta from the chondrocytes halting the disease progress. PRP has shown promising results in osteoarthritis of the knee and hip. This with the excellent safety profile enabled us to try it in ACJ arthritis.

Researchers have suggested a three to six sittings PRP regimen for osteoarthritis of the knee.¹⁹ We had used a single injection of PRP in ACJ arthritis patients. We used the manual double spin method. Method of preparation and the resulting platelet concentration has been attributed to variable results while using PRP. There are several commercially available kits for PRP preparation. However, studies have shown equivalent efficacy between commercially available kits and manual double spin method.²⁰

The results of our pilot study show that PRP can reduce pain and improve the shoulder function rapidly which is at the least maintained for six months. We noticed no significant complications in the study. ISI in ACJ arthritis has not been always reliable. PRP use seems to be more biological. ISI always comes with the slight risk of increased infection rates in future surgeries. These make PRP more ideal than ISI for the treatment of any degenerative arthritis including ACJ arthritis.

Our study is a pilot study with short term follow up. There was no control arm. Future randomized control trials comparing the efficacy of PRP and ISI are needed to establish the superior treatment method.

5. Conclusion

ACJ arthritis is one of the common causes of shoulder pain. In our pilot study, PRP has been a promising option to treat primary ACJ arthritis. Future RCTs are needed to establish it as a superior option in the management of ACJ arthritis.

6. Conflict of Interests

All authors have declared no conflict of interests.

7. Conflict of Interest

None.

References

- Waxman J. Acromioclavicular disease in rheumatologic practice—the forgotten joint. *J La State Med Soc Off Organ La State Med Soc.* 1977;129(1):1–3.
- Krestan C, Pretterklieber B, Pretterklieber M, Kramer J. Acromioclavicular joint : The “forgotten” joint. *Radiol.* 2019;59(3):257–72.
- Zanca P. Shoulder pain: involvement of the acromioclavicular joint. (Analysis of 1,000 cases). *Am J Roentgenol Radium Ther Nucl Med.* 1971;112(3):493–506. doi:10.2214/ajr.112.3.493.
- Östör AJK, Richards CA, Prevost AT, Speed CA, Hazleman BL. Diagnosis and relation to general health of shoulder disorders presenting to primary care. *Rheumatol.* 2005;44(6):800–5. doi:10.1093/rheumatology/keh598.
- Docimo S, Kornitsky D, Futterman B, Elkowitz DE. Surgical treatment for acromioclavicular joint osteoarthritis: patient selection, surgical options, complications, and outcome. *Curr Rev Musculoskeletal Med.* 2008;1(2):154–60. doi:10.1007/s12178-008-9024-5.
- Farrell G, Watson L, Devan H. Current evidence for nonpharmacological interventions and criteria for surgical management of persistent acromioclavicular joint osteoarthritis: A systematic review. *Shoulder Elb.* 2019;11(6):395–410. doi:10.1177/1758573219840673.
- Hossain S, Ayekoloye C, Odumala O, Jacobs L. Intraarticular steroid injection in the treatment of primary acromioclavicular arthritis. an assessment of therapeutic effectiveness. *Orthop Proc.* 2003;85:72. doi:10.1302/0301-620X.85BSUPP_I.0850072c.
- Cruciani M, Franchini M, Mengoli C. Platelet-rich plasma for sports-related muscle, tendon and ligament injuries: an umbrella review. *Blood Transfus Trasfus Sanguie.* 2019;17(6):465–78.
- Andia I, Maffulli N. Platelet-rich plasma for managing pain and inflammation in osteoarthritis. *Nat Rev Rheumatol.* 2013;9(12):721–30. doi:10.1038/nrrheum.2013.141.
- Mall NA, Foley E, Chalmers PN, Cole BJ, Romeo AA, Bach BR, et al. Degenerative Joint Disease of the Acromioclavicular Joint. *Am J Sports Med.* 2013;41(11):2684–92. doi:10.1177/0363546513485359.
- Gupta PK, Acharya A, Khanna V, Roy S, Khillan K, Sambandam SN, et al. PRP versus steroids in a deadlock for efficacy: long-term stability versus short-term intensity—results from a randomised trial. *Musculoskelet Surg.* 2020;104(3):285–94. doi:10.1007/s12306-019-00619-w.
- Dhillon RS, Schwarz EM, Maloney MD. Platelet-rich plasma therapy - future or trend? *Arthritis Res Ther.* 2012;14(4):219. doi:10.1186/ar3914.
- Badsha H, Harifi G, Murrell WD. Platelet Rich Plasma for Treatment of Rheumatoid Arthritis: Case Series and Review of Literature. *Case Rep Rheumatol.* 2020;p. 1–7. doi:10.1155/2020/8761485.
- Chen X, Jones IA, Park C, Vangsness CT. The Efficacy of Platelet-Rich Plasma on Tendon and Ligament Healing: A Systematic Review and Meta-analysis With Bias Assessment. *Am J Sports Med.* 2018;46(8):2020–32. doi:10.1177/0363546517743746.
- Johal H, Khan M, Yung SHP, Dhillon MS, Fu FH, Bedi A, et al. Impact of Platelet-Rich Plasma Use on Pain in Orthopaedic Surgery: A Systematic Review and Meta-analysis. *Sports Health.* 2019;11(4):355–66. doi:10.1177/1941738119834972.
- Foster TE, Puskas BL, Mandelbaum BR, Gerhardt MB, Rodeo SA. Platelet-rich plasma: from basic science to clinical applications. *Am J Sports Med.* 2009;37(11):2259–72.
- Mata JDL. Plasma rico en plaquetas: ¿un nuevo tratamiento para el reumatólogo? *Reumatol Clín.* 2013;9:166–71.
- van Buul G, Koevoet WLM, Kops N, Bos PK, Verhaar JAN, Weinans H, et al. Platelet-Rich Plasma Releasate Inhibits Inflammatory Processes in Osteoarthritic Chondrocytes. *Am J Sports Med.* 2011;39(11):2362–70. doi:10.1177/0363546511419278.
- Kenmochi M. Clinical outcomes following injections of leukocyte-rich platelet-rich plasma in osteoarthritis patients. *J Orthop.* 2020;18:143–9. doi:10.1016/j.jor.2019.11.041.
- Dhurat R, Sukesh MS. Principles and methods of preparation of platelet-rich plasma: A review and author’s perspective. *J Cutan Aesthet Surg.* 2014;7(4):189–97. doi:10.4103/0974-2077.150734.

Author biography

Ramesh Raja C, Assistant Professor

Sudhakar T, Assistant Professor

Jambukeswaran PST, Assistant Professor

Ugeneshwaran M, Assistant Professor

Anil Gowtham Manivannan, Consultant Orthopaedic Surgeon

Cite this article: Raja C R, Sudhakar T, Jambukeswaran PST, Ugeneshwaran M, Manivannan AG. PRP in acromio-clavicular joint arthritis – A prospective analysis. *IP Int J Orthop Rheumatol* 2020;6(2):80-83.