



Original Research Article

Is platelet rich plasma superior to corticosteroid injection for recalcitrant plantar fasciitis? Results of a prospective comparative study

Arun Kumar Somasundaram¹, Jambukeswaran PST^{2,*}, Sathish Muthu³

¹Institute of Orthopaedics and Traumatology, Coimbatore Medical College and Hospital, Coimbatore, Tamil Nadu, India

²Govt. Medical College and ESI Hospital, Coimbatore, Tamil Nadu, India

³Orthopaedic Research Group, Coimbatore, Tamil Nadu, India



ARTICLE INFO

Article history:

Received 08-11-2020

Accepted 22-12-2020

Available online 15-01-2021

Keywords:

Platelet Rich Plasma

Corticosteroid

Plantar Fasciitis

ABSTRACT

Introduction: Plantar Fasciitis is one of the commonest causes of heel pain and can be very challenging for clinicians to treat it successfully in the long run. The results of using autologous platelet-rich plasma (PRP) to treat chronic plantar fasciitis have been very encouraging but there is a dearth of literature comparing its effectiveness with steroid injection in long term for the treatment of chronic plantar fasciitis. This prospective comparative study is conducted to compare the efficacy of PRP over corticosteroids.

Materials and Methods: We conducted this prospective comparative study between PRP and steroid injection by enrolling patients who failed the conservative line of management for 6 weeks period. We sequentially followed up the patient at discharge from the hospital, 6 weeks, 3 months, 6 months, and one year. The preoperative and postoperative function was assessed with The American Orthopaedic Foot and Ankle Society (AOFAS) Score including pain, function, alignment components along with the Visual Analog Scale (VAS) score for pain. Inter and Intragroup comparisons were made with student t-test and paired t-test respectively.

Results: 50 patients with a mean age of 37.2 years were enrolled in the study. In comparison, the PRP group showed a significant improvement in the AOFAS score at 6 months ($p=0.021$) and 1 year ($p=0.001$) compared to the corticosteroid injection. However, the reduction in pain by the VAS score was comparable between the two groups at 6 months ($p=0.542$) and one year ($p=0.224$) respectively.

Conclusion: While both PRP and corticosteroid injection significantly reduces the pain at 1-year follow-up, functional improvement is significantly better in the PRP group compared to the steroids. PRP injection therapy remains more effective compared to steroid injection in the management of recalcitrant plantar fasciitis considering the degenerative component of the disease entity.

© This is an open access article distributed under the terms of the Creative Commons Attribution License (<https://creativecommons.org/licenses/by/4.0/>) which permits unrestricted use, distribution, and reproduction in any medium, provided the original author and source are credited.

1. Introduction

Plantar Fasciitis is one of the commonest causes of heel pain and can be very challenging for clinicians to treat it successfully in the long run.¹ It typically affects both men and women in the age group of 40-70 years and is more predominant in women.^{2,3} It occurs in 10% of the general population and is bilateral in 33% of cases.³ The pathophysiology is still not known but it is basically due to microscopic degeneration of the plantar fascia due to

repetitive microtears and local disruption of the collagen matrix.^{4,5} The presence of zones of hypovascularization and hypervascularization has also been proposed.⁵

Treatment options include plantar fascia stretching exercises, heel cups, night splints, foot contrast bath, weight loss and non-steroidal anti-inflammatory drugs (NSAIDs).⁶⁻¹⁰ Steroids provide excellent short term results.¹¹ But, steroid treatment is associated with complications like rupture of the plantar fascia, heel fat pad atrophy, nerve injury, infection, muscle injury, and skin depigmentation.¹¹

* Corresponding author.

E-mail address: drjambu@yahoo.co.in (Jambukeswaran PST).

Due to the recent advances in regenerative medicine, autologous platelet-rich plasma (PRP) has become the most commonly used orthobiologic to treat musculoskeletal disorders. Platelet-rich plasma is defined as a volume of plasma with a platelet concentration of 10^5 – 10^6 above the baseline.^{12,13} It provides a supra-physiological release of growth factors present in alpha granules of platelets. The bioactive materials in platelets are an admixture of pro-angiogenic, anti-angiogenic, and chemotactic factor which undergo degranulation and induce cellular proliferation, chondrogenesis, angiogenesis, and rejuvenation of degenerated tendons and fascia.^{14,15}

The results of using autologous platelet-rich plasma to treat chronic plantar fasciitis have been very encouraging but there is a dearth of literature comparing its effectiveness with steroid injection in long term for the treatment of chronic plantar fasciitis.¹⁶ This prospective comparative study is conducted to compare the efficacy of the platelet-rich plasma over local injection of corticosteroid.

2. Materials and Methods

A prospective study was conducted with ethical committee approval from November 2018 to November 2019. The study included patients after informed consent who were diagnosed with plantar fasciitis for 6 months and refractory to a conservative line of management for 6 weeks. We excluded patients who had received a corticosteroid injection in the past 3 months or have taken non-steroid anti-inflammatory medications in the past one week before receiving the intervention. We also excluded patients with foot deformities, or history of previous foot surgeries, or established cases of neuropathy.

2.1. Steroid group

Patients in the steroid group received 1 ml of triamcinolone injected at the point of maximal tenderness near the medial calcaneal tubercle following aseptic precautions.

2.2. PRP Group

20 ml of venous blood is collected from the cubital vein following aseptic precautions and 3 ml of sodium citrate is added. The mixture is then divided into 5 vacutainers and centrifuged by a two-spin protocol. Initial soft spin at 1500 rpm for 10 minutes separates the sample into an upper buffy coat and plasma layer and lower red blood cell layer. The upper buffy coat with the plasma layer is transferred into the second set of sterile containers for a second hard spin of 3000 rpm for 10 minutes. This results in the formation of platelet-poor plasma at the upper two-third which is discarded to give the platelet-rich plasma in the lower one-third of the container which is injected at the point of maximum tenderness near medial calcaneal tubercle as shown in Figure 1.

We sequentially followed up the patient at discharge from the hospital, 6 weeks, 3 months, 6 months, and one year. The preoperative and postoperative function was assessed with The American Orthopaedic Foot and Ankle Society (AOFAS) Score including pain, function, alignment components along with the Visual Analog Scale (VAS) score for pain.

Mean and standard deviations were used to denote the descriptive statistics of continuous variables and proportions were used for nominal variables. The between-group comparison was done with a student t-test while within-group analysis was performed with a paired t-test. Statistical analysis was performed with SPSS software version 25. A p-value of less than 0.05 was considered significant.

3. Results

A total of 50 patients of recalcitrant plantar fasciitis not responding to conservative management were included in this study who were allocated randomly into one of the treatment groups. The mean age of the patients enrolled in the study was 37.2 years (SD: 12) The M: F ratio of the patients enrolled in the study was 18:32 with a female preponderance noted.

The general characteristics of the included population were given in Table 1. The mean preoperative AOFAS and VAS scores of the included patients in the steroid and PRP groups were 52.56, 55.72 and 7.32, 7.63 respectively which improved sequentially to 74.92, 85.63 and 3.72, 3.52 respectively at 6 months and 79.92, 89.92 and 2.21, 2.12 respectively a one-year follow-up as shown in Figure 2,3.

Both groups showed significant improvement in mean AOFAS score ($p < 0.001$) and VAS score ($p < 0.001$) compared to the preoperative state at 1-year follow-up. On comparing between the groups no significant difference was noted before injection while at 6 months follow-up PRP group showed a significantly better outcome in the AOFAS score ($p = 0.021$) while pain reduction by VAS score (0.452) was comparable among them. At 1-year follow-up, the PRP group continued to show a significantly better outcome at the AOFAS score ($p = 0.001$) than the steroid group while no significant difference was noted in the VAS score ($p = 0.224$) reduction between them as shown in Table 2. No procedure-related complications were noted in either of the treatment groups.

4. Discussion

Plantar fasciitis means the inflammation of the plantar fascia at the site of its attachment to the calcaneum. But recent studies indicate that it is a condition of degeneration of the plantar fascia rather than true inflammation.^{1,4} Dr. Barrett in 2004 suggested that it was a degeneration of the plantar fascia and called it better as plantar fasciosis. It was also supported by the findings of pathologists that only very

Table 1: Showing the general characteristics of the included population.

Characteristics	Steroid Group	PRP Group
Number of patients	25	25
Mean Age (SD)	34.7 (7.42)	39.4 (8.61)
M:F	10:15	8:17
Preoperative AOFAS Score (SD)	52.56 (11.10)	55.72 (10.72)
Preoperative VAS Score (SD)	7.32 (1.04)	7.63 (1.12)

Table 2: Showing the comparative outcome analysis between steroid group and PRP group

Score	Follow-up	Steroid Group	PRP Group	P value
AOFAS Score	Preoperative	52.56 (11.10)	55.72 (10.72)	0.532
	6 months	74.92 (9.42)	85.63 (10.23)	0.021
	1 year	79.92 (10.83)	89.92 (10.11)	0.001
VAS Score	Preoperative	7.32 (1.04)	7.63 (1.12)	0.643
	6 months	3.72 (1.24)	3.52 (0.92)	0.452
	1 year	2.21 (1.10)	2.12 (0.98)	0.224

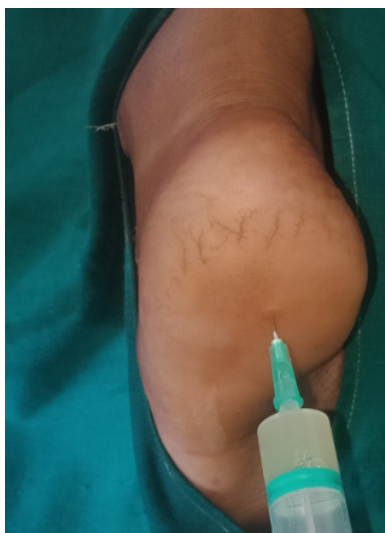

Fig. 1: Showing autologous PRP injection technique for recalcitrant left plantar fasciitis

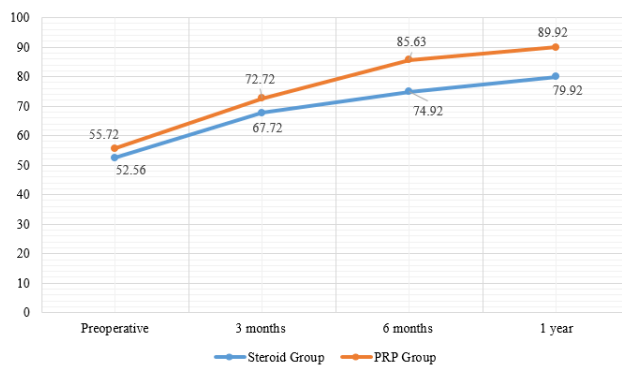


Fig. 3: Showing the comparison of improvement in the AOFAS score between the steroid and PRP groups.

few inflammatory cells were found in specimens received from cases of chronic plantar fasciitis. The pathology passes through a cascade of events including inflammation and degeneration.³ True inflammation is found only in acute cases and in chronic stages, inflammation and degeneration exist together with degeneration dominating the other. This is alike other chronic tendinopathies wherein the features of loss of collagen continuity, increase in ground substance, vascularity and fibroblasts predominate the lesion. Several treatment methods exist for chronic plantar fasciitis which are broadly classified into conservative and invasive. Initially, treatment is begun with a combination of conservative methods including rest, ice pack application, NSAID, footwear modifications including arch supports.^{5,6} Usually multiple sessions of the modalities like ultrasound waves, electrical stimulation, phonophoresis may be required before resolution of the condition can occur. When it is not responsive to the above conservative treatment options, local intra-lesional injections or surgical plantar fascial release can be considered. Local intra-lesional injections of corticosteroids, botulinum toxin,

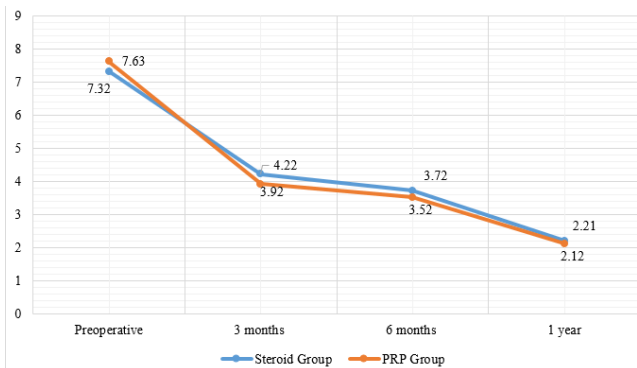


Fig. 2: Showing the comparison of improvement in the VAS score between the steroid and PRP groups.

autologous blood, and platelet-rich plasma can be tried. Several studies indicate the advantages/disadvantages of one treatment option over the other.^{17,18}

Autologous platelet-rich plasma for the treatment of chronic plantar fasciitis exists in the medical literature only for the past decade.¹⁹ Autologous PRP is rich in growth factors (TGF- β , VEGF, PDGF, FGF, EGF), which is released once degranulation of alpha granules of platelets occurs in the pathological site after its activation. PRP possesses anti-inflammatory, anti-bacterial, and pro-regenerating capacity. The presence of various growth factors along with pro-inflammatory cytokines in PRP initiates the healing process of the diseased and degenerated fascia. Once PRP is activated and injected at the pathological site, the growth factors are released in a pulsatile manner to enhance the sustained anti-inflammatory and pro-regenerating effect in the plantar fascia.^{20,21} This might be the reason why our PRP group of patients showed a better response in the AOFAS scores compared to the steroid group.

The smaller sample size of the treatment group in the current study is the limitation and hence larger randomized controlled trials are needed to further validate the results of our study.

5. Conclusion

While both PRP and steroid injection significantly reduces the pain at 1-year follow-up, functional improvement is significantly better in the PRP group compared to the steroids.

PRP injection therapy remains more effective compared to steroid injection in the management of recalcitrant plantar fasciitis considering the degenerative component of the disease entity.

6. Conflicts of Interest

All contributing authors declare no conflicts of interest.

7. Source of Funding

None.

References

- Schwartz EN, Su J. Plantar fasciitis: a concise review. *Perm J*. 2014;18:105–7.
- Cole C, Seto C, Gazewood J. Plantar fasciitis: evidence-based review of diagnosis and therapy. *Am Fam Physician*. 2005;72:2237–42.
- Irving DB, Cook JL, Menz HB. Factors associated with chronic plantar heel pain: a systematic review. *J Sci Med Sport*. 2006;9:11–22.
- Buchbinder R. Clinical practice. Plantar fasciitis. *N Engl J Med*. 2004;350:2159–66.
- Johnson RE, Haas K, Lindow K. Plantar fasciitis: what is the diagnosis and treatment? *Orthop Nurs*. 2014;33:196–204.

- Goff JD, Crawford R. Diagnosis and treatment of plantar fasciitis. *Am Fam Physician*. 2011;84:676–82.
- Dastgir N. Extracorporeal shock wave therapy for treatment of plantar fasciitis. *J Pak Med Assoc*. 2014;64:675–8.
- Neufeld SK, Cerrato R. Plantar Fasciitis: Evaluation and Treatment. *J Am Acad Orthop Surg*. 2008;16(6):338–46. doi:10.5435/00124635-200806000-00006.
- Guatham P, Nuhmani S, Kachanathu SJ. Plantar fasciitis - an update. *Bangladesh J Med Sci*. 2014;14(1):3–8. doi:10.3329/bjms.v14i1.17052.
- Salvi AE. Targeting the plantar fascia for corticosteroid injection. *J Foot Ankle Surg*. 2015;54:683–5.
- Acevedo JI, Beskin JL. Complications of Plantar Fascia Rupture Associated with Corticosteroid Injection. *Foot Ankle Int*. 1998;19(2):91–7. doi:10.1177/107110079801900207.
- Mlynarek RA, Kuhn AW, Bedi A. Platelet-Rich Plasma (PRP) in Orthopedic Sports Medicine. *Am J Orthop*. 2016;45(5):290–326.
- Nguyen RT, Borg-Stein J, McInnis K. Applications of Platelet-Rich Plasma in Musculoskeletal and Sports Medicine: An Evidence-Based Approach. *PM&R*. 2011;3(3):226–50. doi:10.1016/j.pmrj.2010.11.007.
- Grambart ST. Sports Medicine and Platelet-rich Plasma. *Clin Podiatr Med Surg*. 2015;32(1):99–107. doi:10.1016/j.cpm.2014.09.006.
- Martínez-Martínez A, Ruiz-Santiago F, García-Espinosa J. Platelet-rich plasma: Myth or reality? *Radiología*. 2018;60(6):465–75. doi:10.1016/j.rxeng.2018.08.001.
- Yang WY, Han YH, Cao XW. Platelet-rich plasma as a treatment for plantar fasciitis: A meta-analysis of randomized controlled trials. *Med*. 2017;96(44):8475.
- Gupta R, Malhotra A, Masih GD, Khanna T, Kaur H, Gupta P, et al. Comparing the Role of Different Treatment Modalities for Plantar Fasciitis: A Double Blind Randomized Controlled Trial. *Indian J Orthop*. 2020;54(1):31–7. doi:10.1007/s43465-019-00038-w.
- Uğurlar M, Sönmez MM, Uğurlar ÖY, Adıyeye L, Yıldırım H, Eren OT, et al. Effectiveness of Four Different Treatment Modalities in the Treatment of Chronic Plantar Fasciitis During a 36-Month Follow-Up Period: A Randomized Controlled Trial. *J Foot Ankle Surg*. 2018;57(5):913–8. doi:10.1053/j.jfas.2018.03.017.
- Aksahin E, Dogruyol D, Yuksel HY. The comparison of the effect of corticosteroids and platelet-rich plasma (PRP) for the treatment of plantar fasciitis. *Arch Orthop Trauma Surg*. 2012;132:781–6.
- Jain K, Murphy PN, Clough TM. Platelet rich plasma versus corticosteroid injection for plantar fasciitis: A comparative study. *Foot*. 2015;25(4):235–7. doi:10.1016/j.foot.2015.08.006.
- Mahindra P, Yamin M, Selhi HS, Singla S, Soni A. Chronic Plantar Fasciitis: Effect of Platelet-Rich Plasma, Corticosteroid, and Placebo. *Orthop*. 2016;39(2):e285–9. doi:10.3928/01477447-20160222-01.

Author biography

Arun Kumar Somasundaram, Assistant Professor

Jambukeswaran PST, Assistant Professor

Sathish Muthu, Research Associate  <https://orcid.org/0000-0002-7143-4354>

Cite this article: Somasundaram AK, Jambukeswaran PST, Muthu S. Is platelet rich plasma superior to corticosteroid injection for recalcitrant plantar fasciitis? Results of a prospective comparative study. *IP Int J Orthop Rheumatol* 2020;6(2):58-61.