



Review Article

Lumbar Disc Herniation: A review article

Nikhil Jain¹, Mudit Mathur^{2,*}, Saksham Sharma², Saurabh Rawall¹,
Shiv Bhagwan Sharma²

¹Institute of Spine Jaypee Hospital, Noida, Uttar Pradesh, India

²Dept. of Orthopaedics, SRG Hospital and Jhalawar Medical College, Jhalawar, Rajasthan, India



ARTICLE INFO

Article history:

Received 03-04-2020

Accepted 10-05-2020

Available online 17-07-2020

Keywords:

Disc herniation

Low back pain

ABSTRACT

Nearly 80% of the population sustains an episode of low back pain (LBP) once during their lifetime. Within the vast differential of LBP, the most common source is intervertebral disc degeneration leading to degenerative disc disease (DDD) and lumbar disc herniation (LDH). Thus, an effective understanding of LDH, its origins, and how to appropriately treat it is of substantial importance. Through this article we try to dispel some uncertainties about disc herniation and study in detail its aetiology, treatments available, their indications and their clinical outcomes.

© 2020 Published by Innovative Publication. This is an open access article under the CC BY-NC license (<https://creativecommons.org/licenses/by-nc/4.0/>)

1. Introduction

Lumbar intervertebral disc prolapse and sciatic pain has been in a focus since many years. Though Mixter and Barr in 1932 published it as only one cause of sciatic pain and gave surgical disc excision as treatment, sciatica still continues to perplex many physicians who proclaim a bulging disc as the cause of radicular symptoms, but find no obvious herniated fragment on surgical exploration. It occurs because physicians overlook other findings on a MRI scan which can also present clinically similar to sciatica. (Figure 1)

Spine surgery has advanced many folds in the past few decades but the complexity to arrive at the right diagnosis has not become simpler. Even in the presence of advanced radiological techniques like MRI (with or without contrast) and CT (with and without myelogram) the incidence of failed back surgeries is increasing. Through this article we try to dispel some uncertainties about disc herniation and study in detail its aetiology, treatments available, their indications and their clinical outcomes.

Etiology of disc herniation

* Corresponding author.

E-mail address: muditmathur2690@gmail.com (M. Mathur).

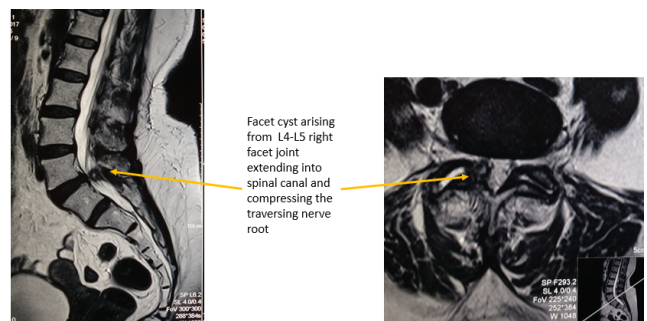


Fig. 1: 64 years male presenting with facet cyst at L4-L5 level along with L4-L5 disc bulge. Patient had right leg radiculopathy. Performing only discectomy in this case will lead to no relief in patient's symptoms.

1. Men (especially in their 3rd to 4th decades of life)^{1,2}
2. Obesity (especially BMI > 30²)
3. Diabetes mellitus and hyperlipidaemia (affect microcirculation of the disc)³
4. Smokers (affect microcirculation of the disc and frequent coughing increase strain on the annulus)⁴
5. Driving for long hours, physically demanding work, manual labour and prolonged sitting (increased

- twisting, bending and vibration from machinery)⁵
6. Genetic predisposition (positive family h/o disc herniation)⁶
 7. Acute trauma⁷
 8. Mobility (lumbar spine is the most common site of disc herniation while thoracic spine is least involved)⁸

1.1. Anatomy & biochemical structure of an intervertebral disc

Intervertebral disc (IVD) is the largest avascular, anural and alymphatic organ of our body.⁹ A single intervertebral disc is composed of 3 components:

1. Two cartilaginous end plates on either side, adjoining the adjacent vertebrae
2. Nucleus pulposus: a gelatinous pulpy core
3. Annulus fibrosus: a tough fibrous layer which holds the gelatinous pulp in its place¹⁰

These structure act synergistically to convert shock loads on the vertebral bodies to a smooth movement.

1.2. Biomechanics of loading forces on an intervertebral disc

Forces acting on a disc produced by loading can mainly be divided into three groups

1. Vertical compression
2. Torsion
3. Bending

Annulus is a highly resilient structure. It takes very high forces for nucleus to rupture an intact young annulus and herniate out of its periphery.¹¹ But since many patients give history of only a trivial trauma like lifting weight or an unbalanced fall, high energy trauma cannot be the sole factor for disc herniation.

Disc failure has been studied to occur through follow ways

1. Annulus integrity breaks from inside progressing to its outer border. This happens when the extracellular matrix becomes altered and weak in a degenerating disc.
2. Forces acting on annulus exceed its tensile strength and break its outer borders. The crack subsequently progresses inwards towards the nucleus with further movements and injuries.

Repetitive loads along with the degenerative cascade, over years lead to gradual breakdown of annular fibres. Posterolateral region is inheritably the weakest area in the annulus and henceforth becomes the most common site of nucleus herniation. It is important to note that for a nucleus should be well hydrated to herniate through the cracked annulus. Therefore disc herniation is more common in individuals in their 3rd and 4th decades of life.

2. Investigations

Of all the radiological investigations MRI plays the most important role as it helps delineate the soft tissue structures exceptionally well. (Figure 2)

High quality 3 Tesla MRI helps to:

1. Confirm the diagnosis of disc herniation and rule out other pathologies
2. Shows the size of the herniated disc
3. Shows the morphology of herniation: symmetric disc bulge, asymmetric disc bulge (not considered as disc herniation but can cause radicular symptoms), focal protrusion, broad based protrusion, extrusion, and sequestration.¹¹
4. Shows the location of herniation: central, paracentral/subarticular, foraminal, extraforaminal
5. Shows if the disc herniation is contained or non-contained
6. Shows migration of fragments: superior, inferior, axillary, intradural^{12,13}
7. Assess the extent of nerve root compromise¹⁴
8. Assess the health status of other discs
9. Assess the size of intervertebral neural foramina
10. Decide if the patient can be managed conservatively or will need decompression
11. Decide the surgical approach to the procedure

2.1. Electrophysiological tests

In cases where MRI does not correspond to clinical findings, electrophysiological testing (EMG & NCV) is a useful tool to investigate metabolic, central neurological and peripheral neurological causes for radiculopathy besides nerve root compression at disc level.

2.2. Blocks

In cases where MRI shows multiple level disc herniation, it can be difficult to identify the right pathological level. In such cases epidural, selective nerve root injections and intraarticular injections in the facets and SI joints can be used as diagnostic tools to locate the pathology.

2.3. Treatment

2.3.1. Non operative treatment

When the patient presents with sciatica for the first time in the outpatient department, in the absence of the following indications the patient can always be started on a non-operative trial

1. H/o significant trauma
2. C/o loss of bowel or bladder control
3. C/o saddle anaesthesia
4. C/o bilateral lower limb weakness
5. C/o rapidly progressing neurological deficit

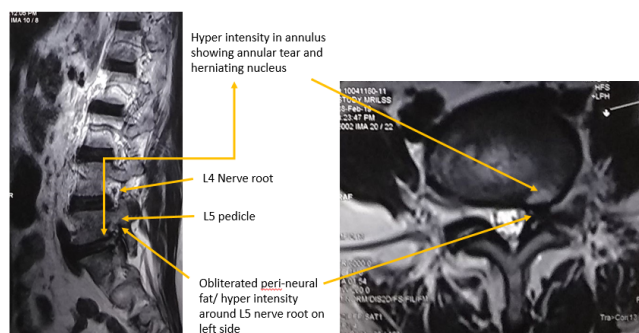


Fig. 2: A 67 year old female presented with left L5 radiculopathy. MRI showed left L5-S1 foraminal disc herniation showing obliterated peri-neural fat & narrowing of the IV foramina with compressed exiting nerve root (L5)

The patient should be managed non-operatively with:

1. Reassurance
 2. Short period of bed rest (2-3 days) especially in a semi-fowler position It helps by unloading the spine¹¹ (Figure 3)
 3. Nonsteroidal anti-inflammatory drugs (NSAIDS)
It helps by decreasing inflammation at the disc and nerve root interface
 4. Muscle relaxants if required
Help relieve the loading from lumbar spasm
 5. Heat massage/ ice therapy
Potentiate the actions of muscle relaxants and NSAIDS
 6. Analgesics (acetaminophen preferred Avoid nephrotoxic drugs)
 7. Anticonvulsants
- Gabapentin and pregabalin have been found to have a beneficial role in neuropathic pain¹⁵

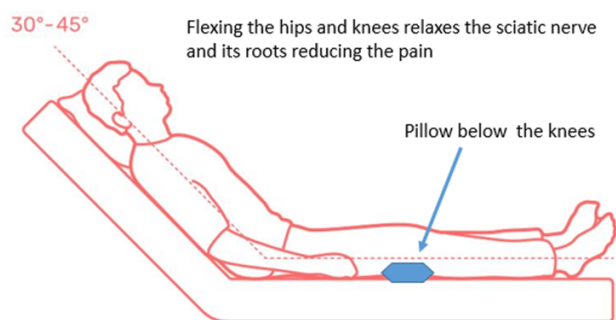


Fig. 3: Semi- Fowler positon: Patient lies relaxed with hips and knees flexed. This position can also be achieved in lateral decubitus by maintaining flexion at hips and knees.

The patient should be followed weekly and repeat physical and neurological examination should be performed at every visit. If there is adequate pain relief and no

further neurologic deficit, the patient can be started on physiotherapy. This includes back stretching, back strengthening and back schools. The type of exercise depends on how long the patient has been disabled and on the grade of muscle atrophy. The patient should be advised modification of his/ her activities which includes to avoid prolonged sitting, forward bending and lifting heavy weights. Most of the patients recover in 4-6 weeks and are allowed to get back to their daily routine life with above mentioned precautions.¹⁶

If there is no improvement from the non-operative management at the end of 4-6 weeks or if there is a progressive neurological deficit or if there is cauda equina syndrome, the patient is advised urgent radiological investigations. Of all the radiological investigations MRI plays the most important role as it helps delineate the soft tissue structures exceptionally well.

2.4. Epidural and selective nerve root block (SNRB)

This procedure is a part of the non-operative management besides being a diagnostic aid. The block is a mixture of a local anaesthetic (0.25% bupivacaine or 0.5% lignocaine) and a corticosteroid (triamcinolone acetate or methylprednisolone) which is delivered at the target level (herniated disc) under fluoroscopic guidance to help relieve the acute radicular pain by its anesthetic and anti-inflammatory action. (Figure 4)

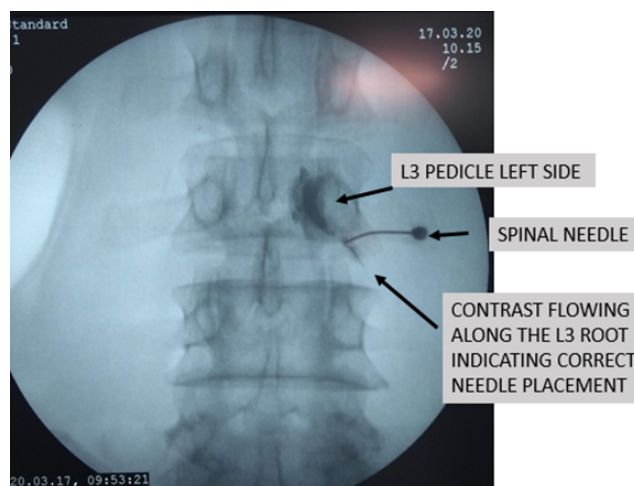


Fig. 4: Fluoroscopic image of epidural root block being given at L3 level left side.

2.4.1. Indications for the SNRB include

1. Patient with herniated disc with a severe root compression not willing to undergo surgery
2. Disc morphology not correlating to the clinical symptoms : it helps confirm if the cause of the radicular pain is the same herniated disc or something else

(Figure 5)

3. Predict the outcome: a patient getting relief from the SNRB will have a favourable outcome if treated surgically.
4. Atypical extremity pain¹⁷

A single shot of epidural or SNRB provides short term relief of around 3 months. It is proven that a patient can delay his her surgery for a few years if they respond well to SNRB or epidural blocks. A patient can have a maximum of 4 injections in a year. Each injection must have a gap of 1-2 weeks in between.^{18,19}

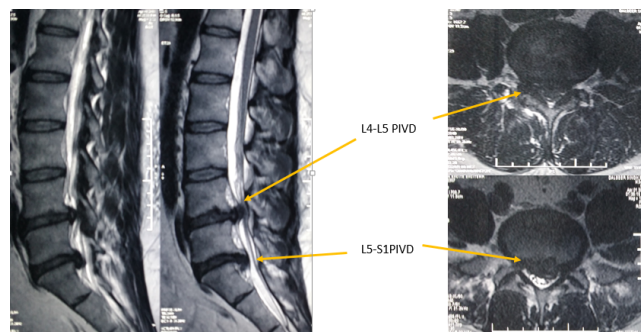


Fig. 5: 34 years old man presented with bilateral lower limb radiculopathy. MRI showed disc herniation at both L4-L5 and L5-S1 levels. The pathological level can be confirmed by giving selective nerve root block to avoid surgical failure.

2.5. Operative Treatment

2.5.1. Indications

All the patients with acute disc herniation:

1. Who have failed a non-operative and epidural/ SNRB trial for 3 -4 months, do not have waddle signs or symptoms and are not involvement in workers compensation litigation.²⁰
2. Have cauda equina syndrome
3. Have progressive neurological deficit
4. Have severe extremity pain^{21,22}
5. Have severe extremity pain^{21,22}

2.6. Chemonucleolysis

Chymopapain is proteinase enzyme extracted from papaya fruit. It has high activity over nucleus pulposus. It breaks the proteoglycan chain and decreases the water holding capacity of the nucleus. Henceforth the nucleus shrinks and the compression is relieved. But it has poor action in extruded/ sequestered disc herniation (because they have lower proteoglycan and higher collagen content), calcified disc herniation, bony canal/ foramen stenosis and instability.

It can pose some serious complications (hypersensitivity, anaphylaxis, subarachnoid haemorrhage and transverse myelitis). Therefore it is not a very popular procedure.

2.7. Surgery

Currently we have following options if a patient is decided for a surgical discectomy

1. Open discectomy/ conventional open discectomy
2. Microscopic discectomy
3. Endoscopic discectomy

2.8. Conventional open discectomy

2.8.1. The technique

The patient is given general endotracheal anaesthesia and placed in a prone position in a Jackson (OSI) table or Andrews spine frame. The target disc space and inter spinous space is identified by palpating the landmarks (iliac crest is at L4-L5 inter spinous space). Same is confirmed on fluoroscopy. A midline incision about 3-5 cm is placed at the target level from rostral to the caudal spinous process. The subcutaneous tissue is dissected and the deep dorsolumbar fascia is incised. Sub periosteal dissection of the para spinal muscles is performed using a bovie from the tip spinous process to its base (the spino-laminar junction). Now using blunt dissection the muscles are retracted laterally with a Cobbs retractor without violating the facet joint capsule. The target inter laminar space is exposed and is confirmed on fluoroscopy before proceeding further. A Taylor retractor is placed lateral to the facet joint. Using curettes, Kerrison rongeurs, nerve and dura retractors the overlying tissue, ligamentum flavum and lamina bone is removed. Medial facetectomy without compromising the stability of the facet joint (not more than 1/3rd of the facet should be resected) is performed. Dura and the traversing roots are visualised. The nerve root is retracted medially and the disc is identified. The annulus is cut and the target fragment is extirpated. Adequate decompression is confirmed if the angled hooks can be passed above and below the root in the neural foramina, nerve root is mobile and there are no visible fragment inside the canal. Hemostasis is achieved and the wound is closed in layers.

The extent of removal of bone from lamina of 3 types:

1. Laminectomy
2. Hemilaminectomy
3. Fenestration/ laminotomy

For a large central disc herniation, cauda equine syndrome and intra-dural migrated disc laminectomy (entire lamina from medial border of one facet to medial border of opposite facet) is performed.

For superiorly or inferiorly migrated disc and lateral recess stenosis hemi laminectomy (from medial border of one facet to the base of spinous process) is adequate.

For rest all cases minimal bone resection (fenestration/ laminotomy) is enough to expose the root and the lateral border of dura.²³

2.9. Micro discectomy

Microsurgery using magnification from microscopes were innovations that limited these surgical insults with equally effective decompression.²⁴ (Figure 6) Specialised burr drills give freedom to remove bone effectively with minimal hand movement in the limited space. (Figure 7) The surgical technique is same as the standard open procedure. The differences are

1. Smaller incision (2-3cm)
2. Minimal damage to soft tissue
3. Microscope magnifies the structures in view allowing
 - a. To undercut the posterior arch without removing it totally
 - b. To view the contralateral pedicle and neural structure by angling the microscope and turning the patient.
 - c. More accurately identify neural structures and protect them from unwanted manipulation
 - d. To record and store the surgical procedure performed
4. Minimises risk of postoperative instability and back pain as the bone and soft tissue are preserved to maximum.
5. Minimal blood loss
6. Reduced postoperative hospital stay
7. Faster post-operative recovery

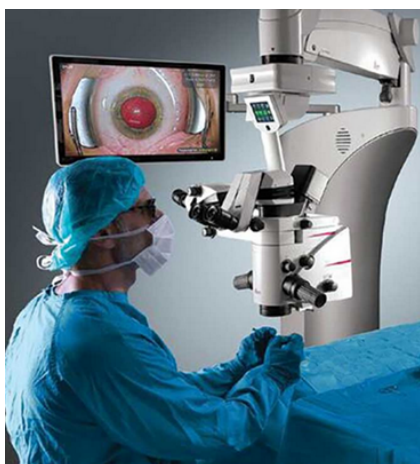

Fig. 6: Surgical microscope

2.10. Endoscopic discectomy

Endoscopic discectomy is a step further to reduce the skin incision length and minimize soft tissue injury. This method was first introduced by Kambin and Hijikata.^{21,25} Currently there are four techniques to do it

1. Micro endoscopic discectomy using tubular retractors
2. The Destandau technique
3. Full endoscopic inter laminar discectomy
4. Full endoscopic posterior transá foraminal discectomy




Fig. 7: Specialized burrdrill tool

2.11. Micro endoscopic discectomy using tubular retractors

This technique was given by Foley and Smith in 1997.²⁶ Tubular retractors split the muscles and radially dilate the muscle fibers. The trick is to not cut through the muscle fibers. This reduces the muscle injury. Specialized serial dilating tubes and retractors are used which have attached light sources. This allows for smaller incisions with excellent view of the underlying structures. (Figure 8)

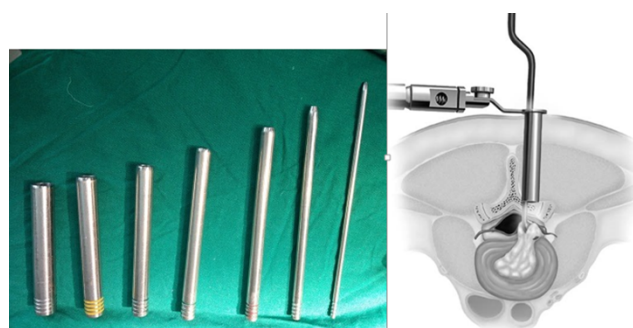


Fig. 8: Tubular retractors

2.12. The technique

With patient in prone position, an AP shot is taken on the C-arm machine and ipsilateral inferior pedicle of the target level is identified and marked. Lateral view is taken to confirm the target level. For a left sided L4-L5 disc, left side L5 pedicle is marked. A 1-2 cm incision is made in the skin and the underlying dorso-lumbar fascia. Specialized serial dilators are then progressed with a rotatory motion that allows separation and serial dilation of muscle fibers.

The dilators are docked onto the inferior L4 facet and confirmed radiologically. After a satisfactory position is achieved specialized expandable retractors are inserted and serial dilators are removed. The retractor system is fixed to a flexible arm rigidly fixed to the operating table. The light source is attached.

The rest of the procedure is same as microscopic discectomy using specialized bayoneted instruments and burr drill.

2.13. The Destandau technique

This technique was described by Jean Destandau in 1999. He developed a specialized endoscopic spine system (Endospine) and approached the spine via the posterior inter laminar approach.^{26,27}

This specialized endospine system consists of two detachable tubes: outer tube and inner tube along with an endoscope. The inner tube has 4 built in channels, each for endoscope, suction, working instruments and nerve root retraction.(Figure 9)



Fig. 9: Endospine system

2.14. The technique

Under endotracheal anaesthesia the patient is placed in knee chest position.

The target inter laminar space is marked under fluoroscopy. A para median 1-1.5 cm long incision, about 1 cm from midline towards the affected side is made. Skin and underlying dorso- lumbar fascia is incised and the para spinal muscles are lifted subperiosteally off the spinous process and lamina. The outer tube is placed and docked at the target inter laminar space. Then the inner tube is placed. The endoscope is passed through its channel. The rest of the decompression is same as microscopic discectomy using its specialised instruments.

2.15. Full endoscopic inter laminar discectomy

In this technique endoscopes has angled lenses. Angled endoscopic lenses allow for greater field of vision. These endoscopes have built in channels for working instruments and light source. These endoscopes are passed through a working cannula and docked at the target inter laminar.

2.16. The technique

With patient in endotracheal anaesthesia and in prone position, the target inter laminar space is marked on AP and lateral fluoroscopy view. An 8-10 mm incision is

made close to the midline. Skin and dorso-lumbar fascia is incised. Blunt tipped dilators are inserted and docket over the target inter laminar space. After confirmation a bevelled working cannula is introduced and the dilator is removed. The position is again confirmed on fluoroscopy. After confirming the level, the endoscope is introduced. Using the specialised long instruments through the channels in endoscopes, the decompression is performed similar to as in microscopic discectomy.

2.17. Full endoscopic trans foraminal discectomy

Also called percutaneous trans foraminal endoscopic discectomy (PTED). The procedure can be performed in endotracheal and local anesthesia as per the comfort of the physician. (Figure 10)

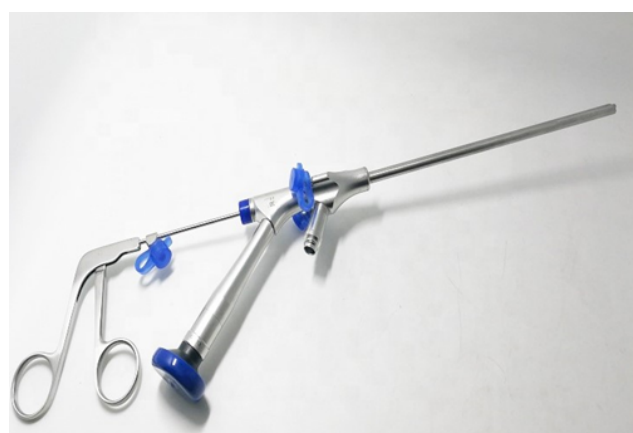


Fig. 10: Percutaneous Trans-foraminal Endoscopic Device

Here the disc is approached posterolaterally through the intervertebral foramen. This technique was given by Kambin in 1992.²⁸ He described a safe pathway for endoscope and its instruments called as 'Kambin's triangle'. It is a zone bounded with the following boundaries (Figure 11)

1. Anterolateral: exiting nerve root
2. Posteromedial: superior facet of caudal vertebra
3. Inferior: superior end plate of caudal vertebra

Accessing the disc through this zone involves minimal risk to neural structures. The equipment involves angled endoscope with an irrigation channel and working channel, long spinal needles, bunt guidewires, dilators, beveled cannula, specialized long handled discectomy instruments and a radiofrequency probe.

2.18. The technique

The procedure can be performed in both local and endotracheal anesthesia as per the comfort of the physician. The most crucial step of this procedure is marking the right

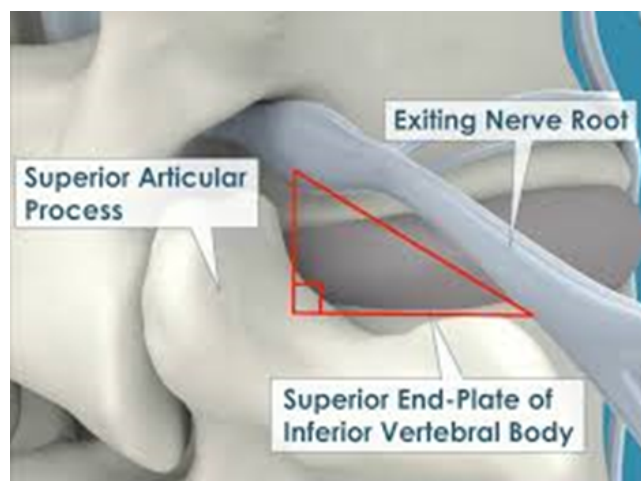


Fig. 11: Kambin's triangle

entry point. With the patient in prone position the abdomen is made free of pressure. Next, under fluoroscopic guidance, two lines are marked on the skin using the AP view of the target disc space.

1. With pedicle equidistant from spinous processes midline of lumbar spine joining the spinous processes. (line A)
2. Midline of target intervertebral disc space with line parallel to the end plates of adjoining vertebra. (line B)

Additional lines are drawn on the skin using the lateral fluoroscopic view of the target disc space

1. Midline of target intervertebral disc space with line parallel to the end plates of adjoining vertebra (line C)
2. Line joining the posterior borders of the facets of lumbar spine (line D)
3. Iliac crest border is marked using finger palpation (line E) The entry point lies in the area enclosed between lines B, C and D

The needle is inserted and directed towards the target disc space at an angle of 20 degrees to the floor. The needle is advanced under fluoroscopic guidance. Keeping the kambin's triangle boundaries in mind, the needle is proceeded to the medial border of the pedicle on AP view and posterior vertebral line in of target disc space on lateral fluoroscopic view.

Now the annulus is pierced and disc is entered. Now discography is performed and indigo carmine dye is injected through the needle into the disc. The dye stains the nucleus blue. Now the needle is replaced with guidewire and over it dilator, beveled cannula and finally the endoscope are progressed. Next step is to access the herniated fragment. Using specialized shavers, drills, curettes and other instruments discectomy is performed.

2.19. Electro thermal annuloplasty

Procedure was initially introduced to relieve the patients of the pain in sciatica. It involves introducing an electro thermal coil into the outer annulus via posterolateral approach. The heat cauterizes the nerve endings and contracts the collagen fibers.

2.20. Coablation Nucleoplasty

Indicated only for contained herniation, using a posterolateral approach a needle is inserted into the target nucleus pulposus and radiofrequency waves are delivered to dissolve the soft nucleus and decompress the nerve.

2.21. Percutaneous Laser disc decompression

Using posterolateral approach laser energy is used through a needle to vaporize the water in the nucleus and shrink the disc fragment. The results have been limited and many cases required discectomy at a later stage.²⁸

2.22. Ozone nucleolysis

Indicated for contained disc herniation ozone is delivered to the target nucleus through the 'kambin's triangle' zone via the transforaminal route. Ozone reacts with nucleus water and generates peroxide and hydroxyl ions. These ions break the nucleus and reduce its size.

2.23. Gelified ethanol, infliximab (anti TNF x) and collagenase

Ethanol mixed with ethyl-cellulose and radiopaque material for treating lumbar disc herniation has been presented in literature.²⁹ Similarly infliximab and collagenase have been tried but the long term results of these methods have been equivocal.^{30,31}

2.24. Special situations

2.24.1. Migrated disc herniation

Disc migration has been classified by Lee et al into

1. Zone 1: far up: from inferior margin of superior pedicle to 3mm below
2. Zone 2: near up : within 3mm of inferior end plate of rostral vertebral body
3. Zone 3: near down: from superior end plate of caudal vertebral body to centre of inferior pedicle
4. Zone 4: far down: from centre of inferior pedicle to inferior border of inferior pedicle.³²

Another classification system has been given Ahn et al. They coined the terms low grade up and down for zone 2 and zone 3 respectively, high grade up and down for zone 1 and zone 4 respectively. They introduced one more grade:

Very high grade: when the disc fragment migrated beyond the inferior margin of the pedicle on either rostral or caudal side.³³ (Figures 12 and 13)

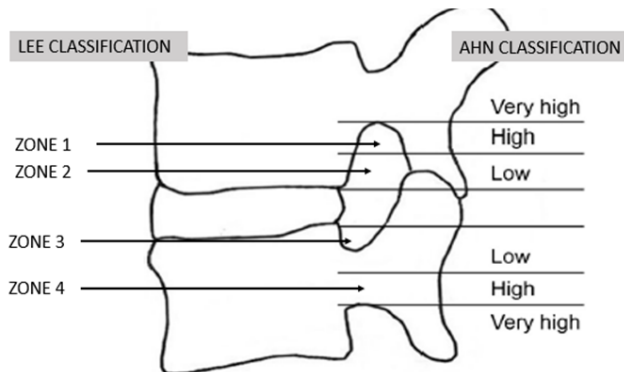


Fig. 12: Lee and Ahn classification systems schematic diagram

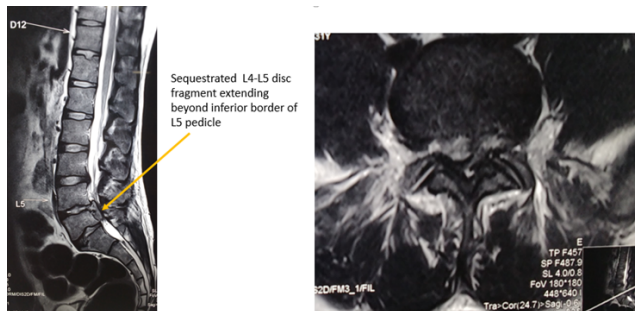


Fig. 13: 32 year old male presenting with right leg radiculopathy and inferiorly sequestered disc very high grade down (beyond inferior pedicle)

2.25. Open/ microscopic technique

When using open or microscopic techniques, for very high grade migration it is recommended to approach from the superior border of the lamina of the pedicle where the fragment is residing.

For low and high grade migrations resecting extra bone using open or microscopic approaches is required. Care should be taken to avoid too much bone removal leading to instability.

2.26. Endoscopic techniques

2.26.1. Transforaminal

Lee et al advise 'half and half technique' for low grade (zone 2 and 3) and 'epiduroscopic technique' along with foraminoplasty for high grade (zone 1 and 4) migrations.

2.27. Interlaminar

Similar to microscopic techniques. Due to freedom of mobility the endoscopes can be angled and flexible instruments can be used to retrieve the migrated fragment. If any difficulty is faced, converting the procedure to microscopic technique is the prudent answer.

2.28. Foraminal disc herniation

2.28.1. Microscopic technique

This can be approached by surgeon standing on the opposite side of the disc herniation and angling the view under the medial border of the facet at the involved side.

2.29. Endoscopic techniques

Transforaminal approach from ipsilateral side is very good procedure for such herniation.

Interlaminar approach can use flexible instruments from the contralateral side. Requires very high expertise for the same.

Extra foraminal/ far lateral disc herniation (Figure 14)

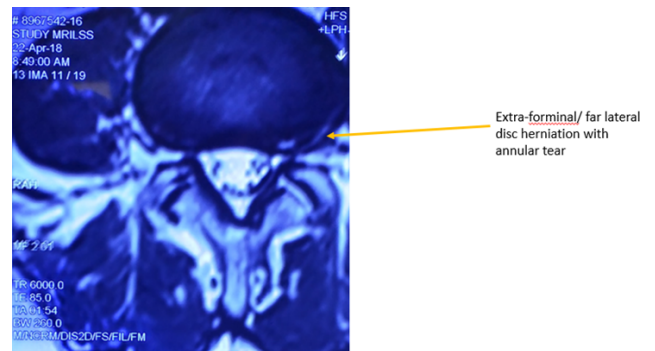


Fig. 14: 68 years old male presented with left leg L4 radiculopathy. MRI showed L4-L5 left extraforaminal disc herniation compressing the exiting L4 nerve root.

2.30. Open/ microscopic technique

Using a paramedian muscle splitting (Wiltse) approach is advised.

2.31. Endoscopic techniques

Transforaminal approach is best suited for such case scenarios while interlaminar approach should be avoided.

2.32. Recurrent disc herniation (Figure 15)

A patient presenting with a recurrence of similar signs and symptoms after a symptom free interval post primary discectomy surgery should be evaluated with contrast MRI. Epidural fibrosis, arachnoiditis and postoperative

granulation tissue should be excluded. After the recurrent fragment has been identified on the MRI scan the patient can be taken up for revision micro discectomy. The fragment appears as hypo intense on T2WI.

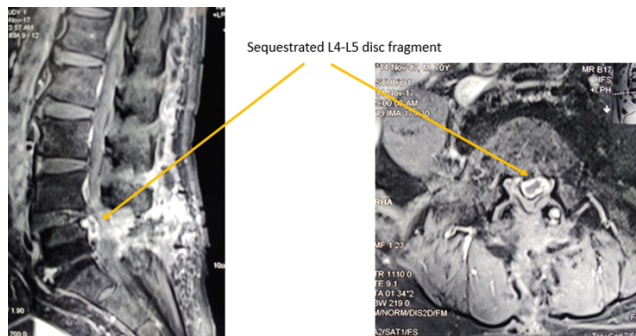


Fig. 15: 70 year old male presented with recurrent disc herniation. The contrast MRI showed low signal core with hyper-intense margins due to peripheral neovascularisation of sequestered disc fragment. (Contrast MRI is the modality of choice to diagnose recurrent disc herniation).

The dura is thinned out due to recurrent herniation and it is easily possible to have a dural tear. These surgeries are best performed using microscopes and wide decompression.³⁴

2.33. Cauda equina syndrome (Figure 16)

Emergency surgical decompression within 48 hours of onset of symptoms is advised.^{35,36} Surgery requires wide decompression (laminectomy + discectomy) using either open or microscopic approach. Endoscopic/ mini open approaches are contraindicated.^{37,38} Postoperative physiotherapy including pelvic floor exercises and multidisciplinary approach plays an important role in the recovery and rehabilitation of the patient.³⁹

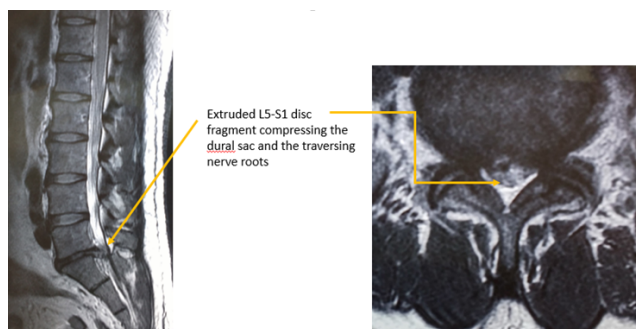


Fig. 16: 48 years old male presented with sudden onset urinary retention and saddle anaesthesia and bilateral lower limb radiculopathy. Diagnosis of cauda equina syndrome was made. MRI revealed extruded L5-S1 disc.

2.34. Fusion

We advocate fusion only if preoperative or postoperative instability is suspected. Discectomy alone produces best results in absence of instability.^{40,41}

2.35. Clinical outcomes

2.35.1. Non operative management vs Surgery

Surgical excision of the disc herniation is as obvious as removing a thorn stuck in the foot. Long term results of over 39000 patients were analysed and showed success rate of 78.9% over an average period of 6 years. This study gave good/excellent results for open discectomy in 78.3% patients, for microscopic discectomy in 84.3% patients and for endoscopic discectomy in 79.5% patients.⁴² SPORT trial (RCT study) followed patients for 8 years and compared the results of operated vs non-operatively managed patients using SF-36 and ODI scores. The results showed clinically significant improvements in the operated patients and there was no degradation in their symptoms over the next 8 year period.⁴³ Maine lumbar spine study reported greater improvement at one year in surgically treated patients.⁴⁴ Spetzger showed 93% success rate following surgery. A 5 year study by Rish L found out of the total patients who were treated with conservative surgery, 41% patients required surgery. In carefully selected patients they found the success rate of surgery was more than 90%.⁴⁵

2.36. Open vs microscopic discectomy

Well performed decompression in carefully selected patients with proper indication for surgery had similar clinical outcomes in terms of pain relief, neurological recovery, complications: dural tear, root injury, reoperation rate and patient satisfaction. Micro discectomy had longer learning curve and longer operative time but was superior in terms of lesser blood loss, lesser tissue damage, lesser post-operative back pain, early mobilisation, shorter hospital stay and early patient recovery.⁴⁶⁻⁴⁹

2.37. Microscopic vs tubular vs fully endoscopic inter laminar discectomy

Outcome measure were ODI, VAS back and leg pain, Modified McNab criterion, and serum CPK levels pre op and post op. As per modified McNab criterion all three groups showed good to excellent results in > 90% patients. VAS and ODI improved significantly in all three groups and their results were similar. But endoscopic and tubular techniques had lesser post op back pain compared to the micro discectomy group. Post-operative MRI showed that dura expansion in all three groups was similar. The blood loss was least in endoscopic and maximum in microscopic group. The endoscopic group had shortest hospital stay period. Endoscopic group had least rise in serum CPK

levels post op. The disadvantage was longer operative time and longer learning curve for tubular and endoscopic techniques.⁵⁰ Similar results have been supported in many other studies.⁵¹

Many studies support smaller incision leads to minimal soft tissue dissection and minimal blood loss leading to less muscle injury, less iatrogenic denervation and less back pain.⁵²⁻⁵⁸

3. Conclusion

It is important to note that discectomy performed in patients with non-contained disc herniation (sequestration/trans ligamentous extrusion) show best relief from surgery followed by contained but ruptured disc herniation (sub ligamentous extrusion) and contained non-ruptured disc herniation (focal protrusion). The poorest results are for patients who are operated for broad based disc protrusion/bulge which are not true herniation though they can compress upon a nearby nerve root in a pre-existing foraminal/ lateral recess stenosis. In the former case scenarios at the time of surgery if a window is cut into the annulus the nucleus will extrude spontaneously and the pathological fragment will be removed. But same does not happen for broad based protrusions or disc bulges as the pathological fragment cannot be located and the exploration turn out to be negative.⁵⁹ This is how the term concealed fragment crept into the literature.⁶⁰

The takeaway message is to study the MRI films, both the axial and sagittal images carefully. Focussing only on a disc with expanded borders beyond its normal contour can make the physician miss the real cause and lead to a futile trip of the patient to the operation theatre. In carefully identified patients, surgery has excellent results. The surgical technique should depend on the expertise of the treating physician as the clinical outcomes in terms of pain relief and neurological recovery are equally good in all well performed techniques.

Minimally invasive techniques show faster and better post-operative recovery but only in hands of well-trained physicians.

4. Source of Funding

None.

5. Conflict of Interest

None.

References

- Cummins J, Lurie JD, Tosteson TD. Descriptive epidemiology and prior healthcare utilization of patients in the Spine Patient Outcomes Research Trial's (SPORT) three observational cohorts: disc herniation, spinal stenosis, and degenerative spondylolisthesis. *Spine*. 1976;31(7):806-14.
- Weiler C, Lopez-Ramos M, Mayer HM, Korge A, Siepe CJ, Wuertz K, et al. Histological analysis of surgical lumbar intervertebral disc tissue provides evidence for an association between disc degeneration and increased body mass index. *BMC Res Notes*. 2011;4(1):497.
- Sakellaridis N. The influence of diabetes mellitus on lumbar intervertebral disk herniation. *Surg Neurol*. 2006;66(2):152-4.
- Jordan J. Herniated lumbar disc. *BMJ Clin Evid*. 2011;.
- Sorensen IG, Jacobsen P, Gyntelberg F, Suadicani P. Occupational and other predictors of herniated lumbar disc disease-a 33-year follow-up in the Copenhagen male study. *Spine (Phila Pa 1976)*. 2011;36:1541-6.
- Kawaguchi Y, Kanamori M, Ishihara H, Ohmori K, Matsui H, Kimura T. THE ASSOCIATION OF LUMBAR DISC DISEASE WITH VITAMIN-D RECEPTOR GENE POLYMORPHISM. *J Bone Joint Surg Am*. 2002;84(11):2022-8.
- Suri P, Hunter DJ, Jouve C, Hartigan C, Limke J, Pena E, et al. Inciting events associated with lumbar disc herniation. *Spine J*. 2010;10(5):388-95.
- Jordan J. Herniated lumbar disc. *BMJ Clin Evidence*. 2009;.
- Oegema TR. Biochemistry of the intervertebral disc. *Clin Sports Med*. 1993;12:419-39.
- Humzah MD, Soames RW. Human intervertebral disc: Structure and function. *Anat Rec*. 1988;220(4):337-56.
- Donegan DJ, Chin KR. Nomenclature and classification of lumbar disc pathology: Recommendations of the Combined Task Forces of the North American Spine Society, American Society of Spine Radiology, and American Society of Neuroradiology. *Spine*. 2001;26:E93-113.
- Lurie JD. Reliability of magnetic resonance imaging readings for lumbar disc herniation in the Spine Patient Outcomes Research Trial (SPORT). *Spine*. 2008;33(9):991-8.
- D'Andrea G, Trillò G, Roperto R, Celli P, Orlando ER, Ferrante L, et al. Intradural lumbar disc herniations: the role of MRI in preoperative diagnosis and review of the literature. *Neurosurg Rev*. 2004;27(2):75-80.
- Pfirmsmann CWA, Dora C, Schmid MR, Zanetti M, Hodler J, Boos N, et al. MR Image-based Grading of Lumbar Nerve Root Compromise due to Disk Herniation: Reliability Study with Surgical Correlation. *Radiol*. 2004;230(2):583-8.
- Donegan JD, Chin KR. Lumbar Microdiscectomy" in Gowne and Gloved orthopaedics: introduction to common procedures. 2009;.
- Dolgun H, Turkoglu E, Kertmen H, Gurer B, Yilmaz ER, Comoglu SS, et al. Gabapentin versus pregabalin in relieving early post-surgical neuropathic pain in patients after lumbar disc herniation surgery: a prospective clinical trial. *Neurol Res*. 2014;36(12):1080-5.
- Keeler KA, Buchowski JM. Evaluation of thoracic and lumbar radicular pathology. Who is a surgical candidate and who isn't" in The Textbook of Spinal Surgery. Philadelphia: Wolters Kluwer Health/Lippincott Williams & Wilkins; 2011. p. 367-75.
- Huston CW, Slipman CW. Diagnostic selective nerve root blocks: indications and usefulness. *Phys Med Rehabil Clin N Am*. 2002;13(3):545-65.
- Riew KD, Park JB, Cho YS, Gilula L, Patel A, Lenke LG, et al. Nerve Root Blocks in the Treatment of Lumbar Radicular Pain. *J Bone Joint Surg Am*. 2006;88(8):1722-5.
- Riew KD, Yin Y, Gilula L, Bridwell KH, Lenke LG, Laurusen C, et al. The effect of nerve- root injections on the need for operative treatment of lumbar radicular pain. A prospective, randomized, controlled, double-blind study. *J Bone Joint Surg Am*. 2000;82-A:1589-93.
- Kambin P, Brager MD. Percutaneous posterolateral discectomy. Anatomy and mechanism. *Clin Orthop Relat Res*. 1987;(223):145-54.
- Fritz JM, Wainner RS, Hicks GE. The Use of Nonorganic Signs and Symptoms as a Screening Tool for Return-to-Work in Patients With Acute Low Back Pain. *Spine*. 2000;25(15):1925-31.
- Diwan A, Sabnis A. The timing of surgery in lumbar disc prolapse: A systematic review. *Indian J Orthop*. 2014;48(2):127-35.
- Blamoutier A. Surgical discectomy for lumbar disc herniation: Surgical techniques. *Orthop Traumatol Surg Res*. 2013;99(1):S187-S196.

25. Caspar W, Papavero L, Sayler MK, Harkey HL. Precise and limited decompression for lumbar spinal stenosis. *Acta Neurochir* . 1994;131(1-2):130-6.
26. Foley KT, Smith MM. Microendoscopic discectomy. *Tech Neurosurg*. 1997;3:301-7.
27. Destandau J. A special device for endoscopic surgery of lumbar disc herniation. *Neurol Res* . 1999;21(1):39-42.
28. Kambin P. Arthroscopic microdiscectomy. *Arthroscopy: J Arthroscopic Related Surg*. 1992;8(3):287-95.
29. Brouwer PA, Brand R, Marle MEVD. Percutaneous laser disc decompression versus conventional microdiscectomy for patients with sciatica: Two- year results of a randomised controlled trial. *Interv Neuroradiol*. 2017;23(3):313-24.
30. Korhonen T, Karppinen J, Paimela L, Malmivaara A, Lindgren KA, Bowman C, et al. The Treatment of Disc Herniation-Induced Sciatica With Infliximab. *Spine*. 2006;31:2759-66.
31. Sussman BJ. Injection of Collagenase in the Treatment of Herniated Lumbar Disk. *JAMA*. 1981;245(7):730-2.
32. Lee S, Kim SK, Lee SH. Percutaneous endoscopic lumbar discectomy for migrated disc herniation: classification of disc migration and surgical approaches. *Eur Spine J*. 2007;16(3):431-7.
33. Ahn Y, Jeong TS, Lim T, Jeon JY. Grading system for migrated lumbar disc herniation on sagittal magnetic resonance imaging: an agreement study. *Neuroradiol*. 2018;60(1):101-7.
34. David LS. "Surgical treatment of lumbar disc herniation" in *The Textbook of Spinal Surgery*. Philadelphia: Wolters Kluwer Health/Lippincott Williams & Wilkins; 2011. p. 387-93.
35. Kostuik JP, Harrington I, Alexander D, Rand W, Evans D. Cauda equina syndrome and lumbar disc herniation. *J Bone Joint Surg Am*. 1986;68(3):386-91.
36. Kapetanakis S, Chaniotakis C, Kazakos C, Papathanasiou JV. Cauda Equina Syndrome Due to Lumbar Disc Herniation: a Review of Literature. *Folia Med*. 2017;59(4):377-86.
37. McLaren AC, Bailey SI. Cauda equina syndrome: a complication of lumbar discectomy. *Clin Orthop Relat Res*. 1986;(204):143-9.
38. Gitelman A, Hishmeh S, Morelli BN. Cauda equina syndrome: a comprehensive review. *Am J Orthop*. 2008;37:556-62.
39. Shivji F, Tsegaye M. Cauda equina syndrome: the importance of complete multidisciplinary team management. *BMJ Case Rep*. 2013;2013(mar 15 1).
40. Kotilainen E, Valtonen S. Clinical instability of the lumbar spine after microdiscectomy. *Acta Neurochir* . 1993;125:120-6.
41. Gibson JNA, Waddell G. Surgical Interventions for Lumbar Disc Prolapse. *Spine*. 2007;32(16):1735-47.
42. Dohrmann GJ, Mansour N. Long-Term Results of Various Operations for Lumbar Disc Herniation: Analysis of over 39,000 Patients. *Med Princ Pract*. 2015;24(3):285-90.
43. Lurie JD. Surgical versus nonoperative treatment for lumbar disc herniation: eight-year results for the spine patient outcomes research trial. *Spine*. 2014;39(1):3-16.
44. Atlas SJ, Deyo RA, Keller RB, Chapin AM, Patrick DL, Long JM, et al. The Maine Lumbar Spine Study, Part II. 1-year outcomes of surgical and nonsurgical management of sciatica. *Spine*. 1976;21:1777-86.
45. Spetzger U, Bertalanffy H, Naujokat C, v Keyserlingk DG, Gilsbach JM. Unilateral laminotomy for bilateral decompression of lumbar spinal stenosis. *Acta Neurochir* . 1997;139(5):392-6.
46. Rish BL. A Critique of the Surgical Management of Lumbar Disc Disease in a Private Neurosurgical Practice. *Spine*. 1984;9(5):500-3.
47. Calikoglu C, Cakir M. Open Discectomy vs. Microdiscectomy: Results from 519 Patients Operated for Lumbar Disc Herniation. *Eurasian J Med*. 2018;50(3):178-81.
48. Caspar W, Campbell B, Barbier DD, Kretschmmer R, Gotfried Y. The Caspar Microsurgical Discectomy and Comparison with a Conventional Standard Lumbar Disc Procedure. *Neurosurg*. 1991;28(1):78-87.
49. Ryang YM, Oertel MF, Mayfrank L, Gilsbach JM, Rohde V. Standard open microdiscectomy versus minimal access trocar microdiscectomy: Results of a prospective randomized study. *Neurosurg*. 2008;62:174-81.
50. W C, Wullenweber R, Brock M, Hamer J, Klinger M, Spoerri O, et al. A New Surgical Procedure for Lumbar Disc Herniation Causing Less Tissue Damage Through a Microsurgical Approach. In: *Lumbar Disc Adult Hydrocephalus*. vol. 4. Springer; 1977. p. 74-80.
51. Lee CW, Yoon KJ, Ha SS. Comparative Analysis between 54.Three Different Lumbar Decompression Techniques (Microscopic, Tubular, and Endoscopic) in Lumbar Canal and Lateral Recess Stenosis: Preliminary Report. *Bio Med Res Int*. 2019;.
52. Zhang B, Liu S, Liu J. Transforaminal endoscopic discectomy versus conventional microdiscectomy for lumbar discherniation: a systematic review and meta-analysis. *J Orthop Surg Res*. 2018;13(1):169.
53. Kim M, Lee S, Kim HS, Park S, Shim SY, Lim DJ, et al. A Comparison of Percutaneous Endoscopic Lumbar Discectomy and Open Lumbar Microdiscectomy for Lumbar Disc Herniation in the Korean: A Meta-Analysis. *Bio Med Res Int*. 2018;2018:1-8.
54. Kawaguchi Y, Matsui H, Tsuji H. Back muscle injury after posterior lumbar spine surgery: part 2: histologic and histochemical analyses in humans. *Spine*. 1976;19:2598-2602.
55. Kim KT, Lee SH, Suk KS, Bae SC. The quantitative analysis of tissue injury markers after mini-open lumbar fusion. *Spine*. 2006;31:712-6.
56. Datta G, Gnanalingham KK, Peterson D, Mendoza N, O'Neill K, Dellen JV, et al. BACK PAIN AND DISABILITY AFTER LUMBAR LAMINECTOMY: IS THERE A RELATIONSHIP TO MUSCLE RETRACTION? *Neurosurg*. 2004;54(6):1413-20.
57. Chao Z, Yue Z, Tong-Wei C. Microendoscopic discectomy, a less traumatic procedure for lumbar disk herniation. *Chin J Traumatol*. 2007;10:311-4.
58. Shin DA, Kim KN, Shin HC. The efficacy of microendoscopic discectomy in reducing iatrogenic muscle injury. *J Neurosurg Spine*. 2008;8:39-43.
59. Sihvonen T, Herno A, Paljärvi L, Airaksinen O, Partanen J, Tapaninaho A, et al. Local Denervation Atrophy of Paraspinal Muscles in Postoperative Failed Back Syndrome. *Spine*. 1993;18(5):575-81.
60. Styf JR, Willén J. The Effects of External Compression by Three Different Retractors on Pressure in the Erector Spine Muscles During and After Posterior Lumbar Spine Surgery in Humans. *Spine*. 1998;23(3):354-8.

Author biography

Nikhil Jain Consultant

Mudit Mathur Post Graduate Resident

Saksham Sharma Post Graduate Resident

Saurabh Rawall Consultant

Shiv Bhagwan Sharma Senior Professor and Unit Head

Cite this article: Jain N, Mathur M, Sharma S, Rawall S, Sharma SB. **Lumbar Disc Herniation: A review article.** *IP Int J Orthop Rheumatol* 2020;6(1):1-11.