



## Original Research Article

## Wood's lamp an antique but precious diagnostic tool: A descriptive observational study of fluorescence pattern with wood's lamp in clinically diagnosed patients with pityriasis versicolor

Arumugakani V<sup>1</sup>, P K Kavirasan<sup>1</sup>, Kannambal K<sup>1</sup>, Poorana B<sup>1</sup>, Abhirami C<sup>1,\*</sup>

<sup>1</sup>Dept. of Dermatology, Venerology and Leprosy, Rajah Muthaiah Medical College, Chidambaram, Tamil Nadu, India



## ARTICLE INFO

## Article history:

Received 05-11-2020

Accepted 11-11-2020

Available online 05-12-2020

## Keywords:

Fluorescence

Pityriasis Versicolor

Wood's lamp

## ABSTRACT

**Background:** Although Pityriasis Versicolor(PV) may be virtually recognized by their characteristic clinical appearance. It is very difficult to diagnose atypical pityriasis versicolor occurring in uncommon sites especially flexural areas and extremities. Uncommon variant type such as plaque type of PV is difficult to differentiate from morphologically similar clinical conditions. Recurrence correlates with the extent of the skin lesions. All these clinical difficulties is overwhelmed by the effective basic tool Wood's lamp.

**Materials and Methods:** This study was an observational descriptive study, totally comprised of 100 clinically diagnosed cases of PV attending Dermatology Outpatient Department over a period of 1 year (October 2019 to October 2020) at Rajah Muthaiah Medical College. Ethical clearance was sought from Institutional Ethical Committee. After obtaining written informed consent detailed history was taken in relation to age, sex, duration of illness, and recurrent infections. Clinical examination of lesion includes site, types of lesions, and scaling. All the PV patients were evaluated under Wood's lamp examination.

**Aims and Objectives:** To study the fluorescence pattern in clinically suspected cases of Pityriasis Versicolor.

**Results:** Out of 100 cases categorized into new and recurrent of PV cases were studied. Patients presented with achromic lesions 76 (76%), chromic were 20 (20%), combined chromic and achromic skin lesions were 4 (4%). Wood's lamp yellow fluorescence were observed in 66(86.8%) among 76 chromic PV cases, 18(90%) patients among achromic 20 cases and the all the four cases of combined variant of PV(4%). We observed yellow fluorescence under Wood's lamp in 88 cases (88%) out of 100 cases.

**Conclusion:** Wood's lamp adds a diagnostic value to find out the extent of PV early, and provides a valuable therapeutic tool to choose the mode of antifungal therapy to avoid recurrence and hypopigmentation thereby ensure complete clearance of PV by follow up Wood's lamp examination. It was also useful to differentiate the similar morphological conditions.

© This is an open access article distributed under the terms of the Creative Commons Attribution License (<https://creativecommons.org/licenses/by/4.0/>) which permits unrestricted use, distribution, and reproduction in any medium, provided the original author and source are credited.

### 1. Introduction

Pityriasis versicolor (PV) is an innocuous, superficial non invasive fungal infective dermatosis in the worldwide. It is associated with alterations in pigmentation caused by normal inhabitant of skin flora named as *Malassezia*, a lipophilic dimorphic fungus. This fungus can cause disease when it converts to its pathogenic mycelia form

under certain predisposed environmental, genetic, and immunological factors.<sup>1</sup>

Pityrialactone and pityriaanhydride are the fluorochromes, primarily products of bisindolylcyclopentenetriones, unprecedented metabolites of *Malassezia furfur*. The first identified metabolite compound pityrialactone is a new fluorochrome bisindolyl compound which has both a bisindole and a lactone structure. Tryptophan is the main nitrogen molecular source of *M. furfur*, for the formation of fluorochromes. It was produced when *M. furfur* was

\* Corresponding author.

E-mail address: [abhiramisundari87@gmail.com](mailto:abhiramisundari87@gmail.com) (Abhirami C).

incubated at 32 C for 14 days on a pigment inducing medium, and with the agar extract producing pale yellow compound eluting from the column which react with 22% acetonitrile and is found to exhibit a strong green-yellow fluorescence.<sup>2</sup>

Pityrialactone appears to be responsible for the green-yellow fluorescence of pityriasis versicolor lesions under Wood's light. Its maximum absorption spectrum appears to be in the wavelength of 352, 292, 276 and 224 nm respectively. Pityriaanhydride which has not yet been described as a natural product but is a known intermediate in the total synthesis of bisindolylmaleimides.<sup>2</sup>

The individual color variation in fluorescence pattern of PV lesions, which may be explained interestingly by the variation does occurs in excitation spectrum and by the property of pityrialactone whether it was dissolved in water or acetonitrile. It fluorescence pale yellow in watery environment and blue in lipophilic milieu. As the skin contains both the solvents such as water and fats, the fluorescence varies.<sup>2</sup>

### 1.1. Woods light physics

The Wood's light ("black light"), first described in 1903, in early 20th century, by an American Baltimore physicist Robert Williams Wood (1868–1955). Though several types of Wood's lamps are available, the most inexpensive ones being the hand models with batteries and small fluorescent tubes, with a high-intensity 100-watt mercury vapor bulb and power supply. It work on the basic principle of fluorescence.<sup>3</sup> The first reported use of this lamp in dermatology occurred in 1925, being recommended for the detection of fungal infection of the hair done by Margarot and Deveze.<sup>4</sup>

When subjecting the skin to wood's lamp examination, a high-pressure mercury arc generate long-wave UV radiation (UVR), the arc is fitted with a compounded filter made of barium silicate with 9% nickel oxide, the so-called 'Wood's filter which is opaque to all generated light except for a band between 320 and 400 nm with a peak at 365 nm. This generated shorter wavelengths is absorbed in the diseased skin and radiation of longer wavelengths (400-700nm) usually visible light, is emitted from the skin and finally fluorescence of tissue occurs. The output of Wood's lamp is generally low.<sup>5</sup> As tissue autofluorescence appears to derive mainly from constituents of elastin (fluorophore unknown), collagen (pyridinoline crosslinks), aromatic amino acids (predominantly tryptophan and its oxidative products), nicotinamide adenine dinucleotide (NAD), and perhaps precursors or products of melanin causing bluish fluorescence.<sup>6</sup>

## 2. Materials and Methods

This study was an observational descriptive study, conducted in 100 clinically suspected cases of Pityriasis Versicolor who attended the department of Dermatology, Venereology and Leprosy at Rajah Muthaiah Medical College, over a period of 1 year (October 2019 to October 2020). Ethical clearance was sought from Institutional Ethical Committee. Written informed consent was obtained, the relevant epidemiological data was taken in relation to age, sex, duration of illness and recurrent infections. Clinical examination of lesion included number, site, types of lesions and scaling. All the PV patients were evaluated under Wood's lamp examination with the fulfilment of a few requirements. The first and foremost obvious requirement is a completely darkened room for the investigation. Second, the user should be aware that the human eye needs some time to adjust to the low light environment in which the investigation takes place. Wood's lamp should be on 20 sec to one minute and kept at the distance of four inches from examination site.

### 2.1. Exclusion criteria

1. Those who have applied topical oil, turmeric, medicated onintments.
2. Those who are on treatment with specific anti fungal therapy less than 4 weeks duration.

## 3. Observations and Results

The study group was comprised of 100 clinically diagnosed cases of Pityriasis Versicolor. Among the 100 patients, 53 were males and the remaining 47 were females with a male to female ratio of 1.12:1.

In our study majority of the age group with PV were observed 11-20 were 30 (30%), followed by 21-30 were 28 (28%), less than one year and 10 years were 18 (18%), 31-40 years were 9(9%), 41-50 years were 9(9%), 51-60 years were 6(6%).

Patients presented with duration of 1–6 months 64(64%), 6 months to 1 year were 24(24%), one year to one and half years were 12(12%). Patients presented with itching were 15(15%), remaining were not have itching. Patients presented with scaling were 87(87%), 13 cases were not with scales. There was a history of family members having similar complaints in 13(13%), and in 87(87%) there was no family history.

## 4. Discussion

In our study, the lesions were most commonly seen in the age group of 11-20 (30%) years, as has been reported by other authors. Ghosh et al<sup>7</sup> found the incidence to be 32.37(32.37%) in young adults in the age group 12-21 years, and Rao et al<sup>8</sup> found in their study that 30% of the patients

**Table 1:** Age and sex wise distribution in the study participants

Age in years	Sex		No of cases	Percentage
	male	Female		
Less than 1-10	6	12	18	18%
11-20	19	11	30	30%
21-30	17	11	28	28%
31-40	3	6	9	9%
41-50	4	5	9	9%
51-60	4	2	6	6%
	53	47	100	100%

**Table 2:** Region wise distribution of skin lesions in the study participants

site of skin lesions	Number of sites
Upper chest	45
Back	39
Face	38
Neck	17
upper extremities	11
Flexural	3
lower extremities	3

**Table 3:** Type of skin lesions among new and recurrent cases of PV.

Type of skin lesions	Total no of cases	percentage	New cases	percentage	Recurrence	percentage
Achromic	76	76%	47	47%	29	29%
Chromic	20	20%	11	11%	9	9%
Both	4	4%	2	2%	2	2%
Total	100	100%	60	60%	40	40%

**pityriasis versicolor**

■ achromic ■ chromic ■ combined

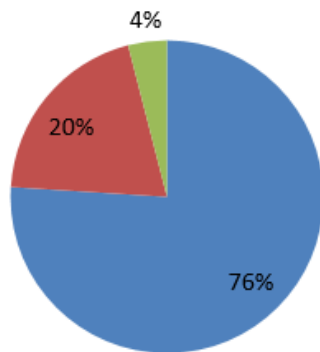
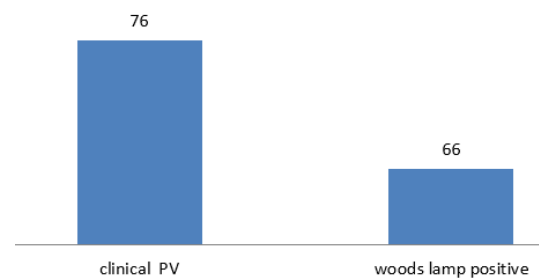


Chart 1: Type of skin lesions in the study participants

belonged to the age group of 21-30 years. The disease may occur at any age, but it is more common during adolescence and in young adults due to an increase in the sebaceous activity and hormonal changes. The present study showed a pre-dominant involvement of males (53%) as compared to

**Achromic PV**

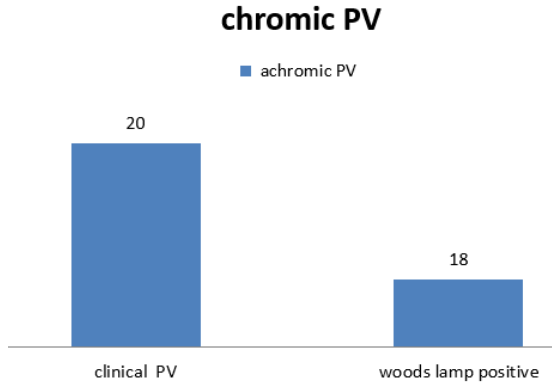
■ chromic



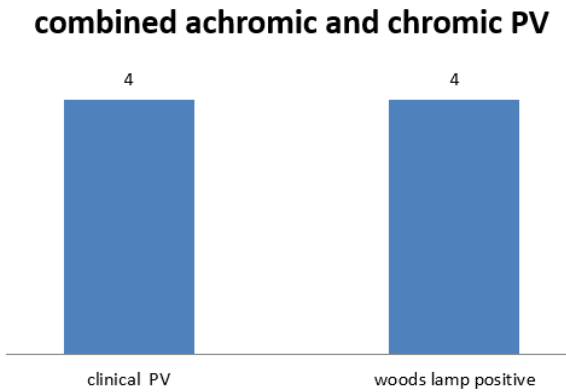
Graph 1: Yellow fluorescence among chromic PV in the study participants.

females(47%) with the ratio of 1.12:1 correlated with Ghosh et al.<sup>7</sup> The higher incidence of Pityriasis versicolor in males may be due to their outdoor activities.

The type of lesions were more achromic (76%) than chromic(20%), which was similar to the study of Rao et al.<sup>8</sup> The distribution of the skin lesions commonly occurred over the chest (45%), and the upper back (39%). These observations were not in conformity with the findings



Graph 2: Yellow fluorescence among chronic PV in the study participants.



Graph 3: Yellow fluorescence among combined variant type of PV in the study participants.

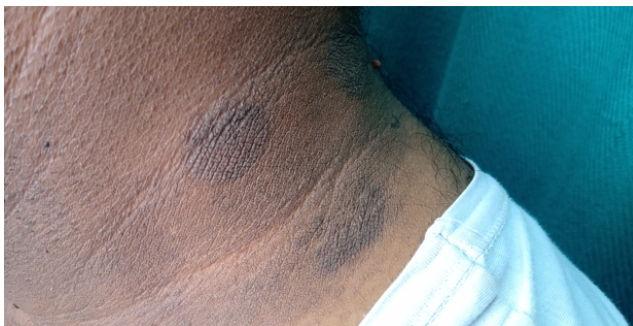

Fig. 1: Acanthosis like chronic Pityriasis Versicolor




Fig. 2: Yellow fluorescence in acanthosis like chronic Pityriasis Versicolor

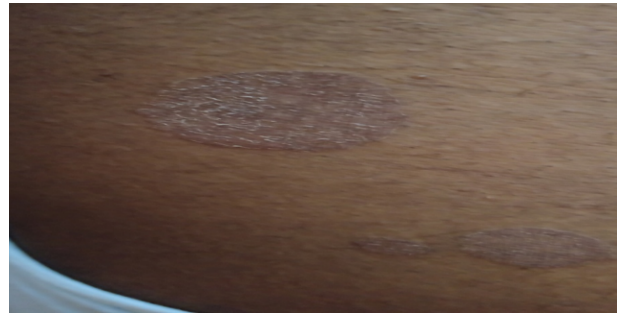

Fig. 3: Plaque type of chronic PV

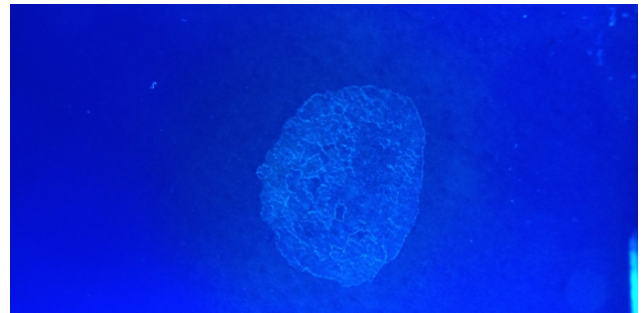


Fig. 4: Yellow fluorescence under Wood's lamp

of Rao et al<sup>8</sup> who found that the lesions were seen commonly over the back (70%) and the chest (58.30%). The distribution of the lesions generally parallels the density of the sebaceous gland distribution, with a greater occurrence on the chest and the back.

In our study yellow fluorescence observed in patients who were clinically suspected case of Pityriasis Versicolor which was concordance with previous literature yellow fluorescence in PV reported by Robert Williams<sup>9</sup> and many authors. In our study 86(86%) of patients showed PV yellow fluorescence under Wood's lamp examination, as has been reported by Remya et al<sup>10</sup> who compared Wood's lamp examination with KOH wet mount in patients with PV. They concluded that Wood's lamp positive in 86.2% of the PV lesions studied.

Wood's lamp examination for showing yellow-orange fluorescence was found to be positive in 70% of the cases reported by Deshpande SA et al.<sup>11</sup>

There was no fluorescence detected in 10(10%) cases of infants less than 1 year and children upto 3 years who were included in the study. Fahimeh et al<sup>12</sup> reported that Wood's lamp observation in infantile pityriasis versicolor some lesions of hypopigmented areas showed yellowish fluorescence .

In these group face was the commonest site which was similar to the previous study conducted by Terragni et al.<sup>13</sup> Hypochromic was the commonest clinical presentation in paediatric Pityriasis Versicolor which was similar to the study reported by Bouassida et al.<sup>14</sup>

Wood's lamp is equally effective in detecting new and recurrent cases of PV. Intensity or brightness of yellow fluorescence detected highly in chronic PV skin lesions than achromic PV under Wood's lamp may be the reason due to increased number of spores and hyphae, abnormally large melanosomes and melanin granules, and induction of melanogenesis.<sup>15</sup> Wood's lamp negativity 14 cases (14%) may be explained by different species of malassezia<sup>15</sup> and the variation in the production of fluorochromes.

## 5. Conclusion

Though the mycological study in Pityriasis versicolor by doing Potassium hydroxide mount or by other conventional methods is simple, it is impossible to do in the situations like non scaly and atypical presentation without suspicious of Pityriasis versicolor. We can easily avoid misdiagnosis by usage of Wood's lamp in daily out patient department.

## 6. Limitations

Chance of unwarranted diagnosis by wrong interpretation of scales which fluoresce normally as bluish white. Total removal of scales in infective conditions abolishes the fluorescence pattern and may give false negative results. So we need a experience to interpret the results.

## 7. Source of Funding

No financial support was received for the work within this manuscript.

## 8. Conflict of Interest

The authors declare they have no conflict of interest.

## References

- Renati S, Cukras A, Bigby M. Pityriasis versicolor. *BMJ*. 2015;350(apr07 1):h1394. doi:10.1136/bmj.h1394.
- Mayser P, Stapelkamp H, Krämer HJ, Podobinska M, Wallbott W, Irlinger B, et al. Pityrialactone- a new fluorochrome from the tryptophan metabolism of *M. alassezia furfur*. *Antonie Van Leeuwenhoek*. 2003;84(3):185–91. doi:10.1023/a:1026042903354.
- Ruocco E, Baroni A, Donnarumma G, Ruocco V. Diagnostic procedures in dermatology. *Clin Dermatol*. 2011;29(5):548–56. doi:10.1016/j.clindermatol.2010.09.023.
- Margarot J, Deveze P. Aspect de quelques dermatoses en lumie're ultraparaviolette. Note pre'liminaire. *Bull Soc Sci Med Biol Montpellier*. 1925;6:375–8.
- Caplan RM. Medical Uses of the Wood's Lamp. *J Am Acad Dermatol*. 1967;20(11):1035–8.
- Asawanonda P, Taylor CR. Wood's light in dermatology. *Int J Dermatol*. 1999;38(11):801–7. doi:10.1046/j.1365-4362.1999.00794.x.
- Ghosh SK, Dey SK, Saha I, Barbhuiya JN, Ghosh A, Roy AK. Pityriasis versicolor: A clinicomycological and epidemiological study from a tertiary care hospital. *Indian J Dermatol*. 2008;53(4):182–5. doi:10.4103/0019-5154.44791.
- Rao GS, Kuruvilla M, Kumar P, Vinod V. Clinico Epidemiological studies on tinea versicolor. *Indian J Dermatol Venereol Leprol*. 2002;68:208–9.
- Sharma S, Sharma ARW, Wood. Robert Williams Wood: pioneer of invisible light. *Photodermatol Photoimmunol Photomed*. 2016;32:60–5.
- Remya VS, Arun B. Diagnostic Efficacy of Wood's Lamp Examination Compared with Koh Wet Mount for Diagnosis of Pityriasis Versicolor Cases. *Int J Hea Sci Research*. 2019;9(4):27–30.
- Deshpande SA, Sunita D, Amladi S, Shastri J. The role of mycological investigations in the diagnosis of Pityriasis Versicolor and Seborrheic dermatitis. *Ind J Bas App Med Research*. 2014;4(1):315–23.
- Abdollahimajd F. Infantile hypopigmented pityriasis versicolor: two uncommon cases. *Türk Pediatri Arşivi*. 2019;54(4):277–80. doi:10.14744/turkpediatrics.2018.62134.
- Terragni L, Lasagni A, Oriani A, Gelmetti C. Pityriasis Versicolor in the Pediatric Age. *Mycoses*. 1991;34(7-8):345–7. doi:10.1111/j.1525-1470.1991.tb00831.x.
- Bouassida S, Boudaya S, Ghorbel R, Meziou TJ, Marrekchi S, Turki H, et al. Pityriasis versicolor de l'enfant: étude rétrospective de 164 cas Pityriasis versicolor in children: a retrospective study of 164 cases. *Ann Dermatol Venereol*. 1998;125(9):581–4.
- Thappa DM, Gupta D. The enigma of color in tinea versicolor. *Pigment Int*. 2014;1(1):32–5. doi:10.4103/2349-5847.135440.

## Author biography

**Arumugakani V**, Post Graduate

**P K Kavirasan**, Professor and HOD

**Kannambal K**, Associate Professor

**Poorana B**, Assistant Professor

**Abhirami C**, Assistant Professor

**Cite this article:** Arumugakani V, Kavirasan PK, Kannambal K, Poorana B, Abhirami C. Wood's lamp an antique but precious diagnostic tool: A descriptive observational study of fluorescence pattern with wood's lamp in clinically diagnosed patients with pityriasis versicolor. *IP Indian J Clin Exp Dermatol* 2020;6(4):313-317.