



## Original Research Article

## Variations in mandibular coronoid process-A morphometric treatise

Sukhman Kahlon<sup>1</sup>, Gaurav Agnihotri<sup>1,\*</sup><sup>1</sup>Dept. of Anatomy, Government Medical College, Amritsar, Punjab, India

## ARTICLE INFO

## Article history:

Received 08-08-2020

Accepted 27-09-2020

Available online 23-11-2020

## Keywords:

Mandible  
Coronoid process  
Rounded  
Triangular  
Hook.

## ABSTRACT

**Introduction:** The Coronoid process is a triangular upward projection from antero-superior part of ramus of mandible giving attachment to two important muscles of mastication.**Aims:** The aim of our study was to observe the variations in shape and size of coronoid process and establish the morphometric profile in Indian population.**Materials and Methods:** The material for this study comprised of 500 adult human mandibles. The shape of coronoid process was observed and its height and length were measured.**Results:** Three variants of coronoid process were observed (round, triangular and hook) with incidence percentage 46, 42 and 12 respectively. The mean value of height and length of coronoid process came out to be 60.62 mm and 12.53 mm respectively.**Conclusions:** This morphometric treatise provides valuable inputs relevant for anthropological comparisons, forensic investigations and reconstructive procedures.© This is an open access article distributed under the terms of the Creative Commons Attribution License (<https://creativecommons.org/licenses/by/4.0/>) which permits unrestricted use, distribution, and reproduction in any medium, provided the original author and source are credited.

## 1. Introduction

Coronoid process in Greek means “like a crown”. In lower animals, separate coronoid bones are present which articulate with the splenial, angular and supra angular bones to form a common “dentary bone” which is homologous to mandible in humans.<sup>1</sup>

The coronoid process of mandible is of clinical significance for maxillofacial surgeons for reconstructive purposes as it is used as graft for reconstruction of osseous defects in oral and facio-maxillary region.<sup>2</sup> Anatomical variations in the coronoid process can result in extremely narrow vestibular space due the close proximity of the medial aspect of the coronoid process to the distal molar.<sup>3</sup>

The present morphometric treatise focuses on variant anatomy of the coronoid process in Indian population. The study provides baseline data for Indian population which has clinical implications and repercussions.

## 2. Materials and Methods

The material for the present study comprised of 500 adult human mandibles. These mandibles were obtained from the different medical colleges in the state of Punjab. Any mandible broken or dysmorphic were excluded from the study.

The coronoid height was measured as distance between the coronoid and most protruding portion of inferior border of the ramus of mandible (Figure 1).

The length of coronoid process was taken from the line tangential to the deepest part of mandibular notch to apex of the coronoid process (Figure 2).

## 3. Results

The shape of coronoid process was classified into 3 types: (Figure 3)

1. Triangular: Tip pointing directly upwards.
2. Rounded: Tip rounded.
3. Hook: Tip pointing backwards.

\* Corresponding author.

E-mail address: [anatomygaurav@yahoo.com](mailto:anatomygaurav@yahoo.com) (G. Agnihotri).

Three incidence percentage for round, triangular and hook shaped coronoid processes came out to be 46, 42 and 12 respectively. The mean value of height and length of coronoid process was determined to be 60.62 mm and 12.53 mm respectively. (Tables 1 and 2 )

#### 4. Discussion

The coronoid process develops as a discrete entity within the mass of the temporalis muscle anlage, subsequently it unites with the main portion of mandibular ramus at approximately eight weeks of age.<sup>4</sup>The largest portion of temporalis muscle is attached to the apex, whole of the medial surface and anterior part of lateral surface of coronoid process. The remaining part of lateral surface provides attachment to anterior fibres of masseter. These two are important muscles of mastication which show morpho functional dependence.

Several authors have described the various shapes of coronoid process. According to which, some processes are triangular, hook shaped and rounded<sup>5-7</sup> whereas others have described it as beak shaped.<sup>8</sup> The shape and size of coronoid process is influenced by dietary habit, genetic constitution, hormonal and mainly by temporalis muscle activity.<sup>9</sup> In the present study, the incidence of the rounded shape was the highest followed by the triangular shape. In most studies in India the triangular shape was most commonly observed. In previous studies in Turkish population<sup>10</sup> and Bangladeshi population<sup>11</sup> the most common shape observed was the hook shape. (Tables 3 and 4)

The coronoid process projects upwards and slightly forwards. It has a top border and is convex in shape, while its lower part is concave in shape. Its margins and medial surface provide attachment to temporalis muscle. The coronoid process is suitable for paranasal augmentation. Its clinical application is also favourable because its size and morphology fits into the paranasal region, with the additional advantages of biocompatibility, availability, and reduced operation time for harvesting.<sup>12,13</sup> The present study focuses on the height and length of coronoid process of mandible with the aim to characterize the morphological profile of the coronoid process in Indian population. This will benefit dental surgery, anthropological and forensic practice.

Coronoid process enlargement may be seen in some pathological conditions like osteochondroma, exostosis, osteoma and other developmental anomalies. Though fracture of mandible is common, but incidence of coronoid fracture is rare (2%) and requires no treatment unless impingement on the zygomatic arch is present. Coronoid process hyperplasia is a very rare cause of mandibular hypomobility. So, it is usually underdiagnosed, but a thorough background anatomical knowledge can help in examining the patient clinically and radiologically.<sup>14,15</sup> This ultimately will help in the line of management and a better clinical outcome.<sup>16</sup>

The coronoid process can be removed intra-orally without any functional deficiency and facial disfigurement. It is expected that a knowledge of the morphometric profile of the coronoid process in different populations will aid the clinician in reconstruction procedures such as those pertaining to orbit floor, alveolar defects, paranasal sinus augmentation, non union fracture mandible, osseous defects reconstruction and other repair procedures in cranio-maxillo facial surgeries.<sup>17,18</sup>

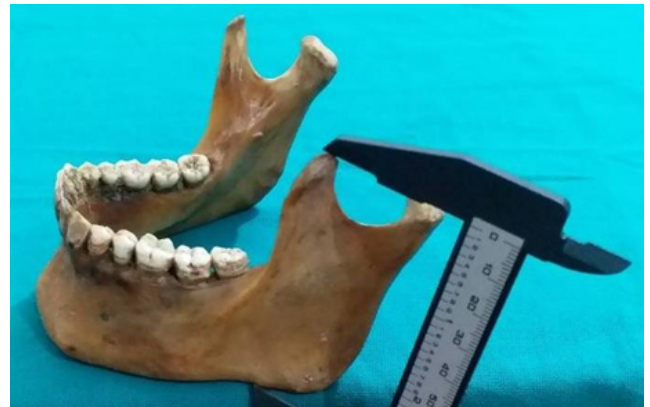

Fig. 1: Showing measurement procedure for coronoid height

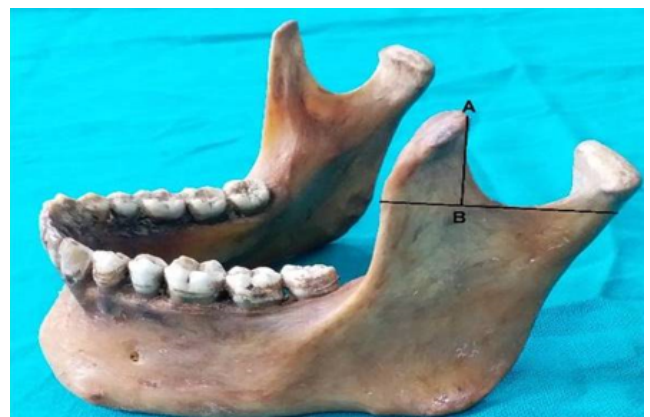

Fig. 2: AB is length of coronoid process

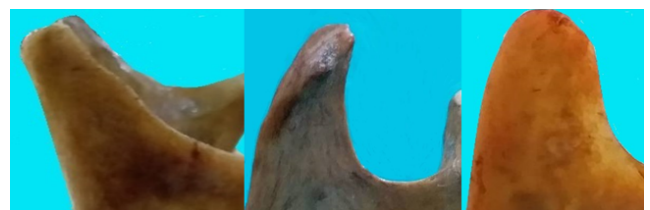


Fig. 3: Showing the triangular, hook shaped and rounded coronoid processes (left to right)

**Table 1:** Showing variations of shape of coronoid process in mandible

Shape	Number of mandibles	Percentage incidence
Triangular	210	42%
Hook Shaped	060	12%
Rounded	230	46%

\* The coronoid process was rounded in the majority of cases (46%)

**Table 2:** Showing metric parameters related to coronoid process of mandible

Parameters	Mean value	Standard deviation
Height	60.62	5.95
Length	12.53	2.75

\* Identifies the morphometric correlates pertaining to the coronoid process in the study sample

**Table 3:** Comparison of shape of coronoid process in different populations

Authors (Year)	Population	Triangular	Hook shaped	Rounded
Khan TA and Sharieff JH <sup>5</sup> (2011)	South India	67%	30%	3%
Prajapati VP et al <sup>6</sup> (2011)	Western Indians	54.17%	21.25%	24.58%
Desai VC et al <sup>7</sup> (2014)	South-west Indians	136 (68%)	48 (24%)	16 (8%)
Pradhan S et al <sup>1</sup> (2014)	Eastern Indians	86 (46.73%)	33 (17.93%)	65 (35.3%)
Present study (2020)	Indians	210 (42%)	60 (12%)	230 (46%)

**Table 4:** Showing comparison of coronoid height of mandible in different populations

Authors (Year)	Population	Mean ± SD
Koyama M <sup>12</sup> (1965)	Japanese	98.27±5.2 (male) 91.85±5.6 (female)
Kumar MP and Lokanadham S <sup>13</sup> (2013)	South-east Indians	59.37±5.03
Sandeepa NC et al <sup>14</sup> (2017)	Saudi	74.18±5.78 (male) 63.28±5.06 (female)
Present study (2020)	Indians	60.62±5.95

## 5. Conclusions

Our study of coronoid process suggest that round shape is the most common presentation(46%) followed by triangular(42%) and then hook shaped(12%). This morphometric treatise provides valuable inputs relevant for anthropological comparisons, forensic investigations and reconstructive procedures.

## 6. Source of Funding

None.

## 7. Conflict of Interest

None.

## References

- Pradhan SS, Bara D, Patra S, Nayak S, Mohapatra C. Anatomical Study of Various Shapes of Mandibular Coronoid Process in Relation to Gender & Age. *IOSR J Dent Med Sci.* 2014;13(8):09–14.
- Choung PH, Kim SG. The coronoid process for paranasal augmentation in the correction of midfacial concavity. *Oral Surg Oral Med Oral Pathol Oral Radiol Endod.* 2001;91(1):28–33.
- Mintz SM, Ettinger A, Schmakel T, Gleason MJ. Contralateral coronoid process bone grafts for orbital floor reconstruction: An anatomic and clinical study. *J Oral Maxillofac Surg.* 1998;56(10):1140–4.
- Spyropoulos MN. The morphogenetic relationship of the temporal muscle to the coronoid process in human embryos and fetuses. *Am J Anat.* 1977;150(3):395–409.
- Khan TA, Sharieff JH. Observation on morphological features of human mandibles in 200 South Indian subjects. *Anatomical Karnataka.* 2011;5(1):44–53.
- Prajapati VP, Malukar O, Nagar SK. Variations in the morphological appearance of the coronoid process of human mandible. *National J Med Res.* 2011;1(2):64–70.
- Desai VC, Desai SD, Shaik HS. Morphological study of mandible. *J Pharm Sci Res.* 2014;6(4):175–77.
- Schafer EA, Thane GD. Quain's Elements of Anatomy: The bones of the head. 10th ed. London: Longmans, Green & Co; 1890.
- Kausar H, Tripathi A, Raizaday S, Bharti S, Jain S, Khare S, et al. Morphology and Morphometry of Coronoid Process of Dry Mandible- A Comprehensive Study. *Journal of Evidence Based Medicine and Healthcare.* 2020;7(15):773–6.
- Bakirci S, Ari I, Kafa IM. Morphometric characteristics and typology of coronoid process of the mandible. *Acta Med Mediterr.* 2013;29(4):683–6.
- Hossain A, M S, Hossain M, Banna SM, Famh. Variations in the shape of the coronoid process in the adult human mandible. *Bangladesh J Anat.* 2011;9(2):75–83.
- KOYAMA M. An Anthropological Study on the Mandible in the Japanese, especially Measurements in Relation to the Construction of an Articulator. *J Nihon Univ Sch Dent.* 1965;7(1):51–59.
- Kumar MP, Lokanadham S. Sex determination & morphometric parameters of human mandible. *Int J Res Med Sci.* 2013;1(2):93–6.
- Sandeepa NC, Ganem AA, Alqhtani WA, Mousa YM, Abdullah EK, Alkhayri AH. Mandibular indices for gender prediction: A retrospective radiographic study in Saudi population. *J Dent Oral Health.* 2017;3(9):1–7.
- Nayak S, Patra S, Singh G, Mohapatra C, Rath S. Study of the size of the coronoid process of mandible. *J Anatomical Soc India.* 2016;65(6):S2–3.
- Nayak S, Pradhan S, Bara DP, Patra S. Bilateral elongated coronoid process: A case report. *IOSR J Dent Med Sci.* 2015;14(5):61–4.
- Amrani S, Anastassov GE, Montazem AH. Mandibular Ramus/Coronoid Process Grafts in Maxillofacial Reconstructive Surgery. *J Oral Maxillofac Surg.* 2010;68(3):641–6.
- Clauser L, Curioni C, Spanio S. The use of the temporalis muscle flap in facial and craniofacial reconstructive surgery. A review of 182 cases. *J Craniomaxillofac Surg.* 1995;23(4):203–14.

**Author biography**

**Sukhman Kahlon**, Junior Resident

**Gaurav Agnihotri**, Associate Professor

**Cite this article:** Kahlon S, Agnihotri G. Variations in mandibular coronoid process-A morphometric treatise. *J Dent Spec* 2020;8(1):9-12.