



## Original Research Article

## Evaluation of efficacy of ultrasound guided erector spinae plane block and oblique subcostal transversus abdominis plane block for postoperative analgesia in laparoscopic cholecystectomy

Sidharth Sraban Routray<sup>1</sup>, Ramakanta Mohanty<sup>2</sup>, Kamalakanta Pradhan<sup>1</sup>, Soveena Pani<sup>1,\*</sup>

<sup>1</sup>Dept. of Anaesthesiology and and Critical Care, SCB Medical College, Cuttack, Odisha, India

<sup>2</sup>Dept. of Surgery, F. M Medical College, Balasore, Odisha, India



## ARTICLE INFO

## Article history:

Received 24-03-2020

Accepted 06-06-2020

Available online 26-08-2020

## Keywords:

Cholecystectomy

Laparoscopic

Pain management

Erector spinae plane block

Oblique subcostal transversus abdominis plane block

## ABSTRACT

**Aim & Objective:** Laparoscopic cholecystectomy (LC) is a commonly performed minimally invasive surgery. LC can cause moderate to severe postoperative pain due to small keyhole entries on the abdominal wall. The oblique subcostal transversus abdominis plane block (OSTAP) has been used for postoperative analgesia after LC but found not so effective. Our aim is to compare the effectiveness of erector spinae block with OSTAP block for postop analgesia after LC.

**Materials and Methods:** This prospective, randomized study was conducted at a tertiary care hospital. Seventy patients, 18 to 65 years old posted for LC were divided into two equal groups of 35 each. Erector spinae plane block was performed in the ESP group and oblique subcostal transversus abdominis plane block was performed in the OSTAP group. Postoperative rescue analgesic consumption, time to 1<sup>st</sup> rescue analgesia, numerical rating score (NRS), and any complications in 1<sup>st</sup> 24 hrs between the groups were compared.

**Results:** Postoperative rescue analgesic (paracetamol) consumption was  $1.9 \pm 0.85$  gm in ESP group and  $2.84 \pm 0.29$  gm in OSTAP group which was statistically significant. Time to 1<sup>st</sup> rescue analgesia request was  $360.34 \pm 28.94$  mins in ESP group and  $280.51 \pm 45.66$  mins in OSTAP group which was statistically significant. Although NRS scores at almost all time-points were lower in the ESP group compared to OSTAP block, the difference was significant in 1<sup>st</sup> 6 hrs.

**Conclusion:** Ultrasound guided ESP block reduced postoperative rescue analgesic consumption and pain scores more effectively than OSTAP block after laparoscopic cholecystectomy surgery.

© 2020 Published by Innovative Publication. This is an open access article under the CC BY-NC license (<https://creativecommons.org/licenses/by-nc/4.0/>)

## 1. Introduction

Laparoscopic cholecystectomy (LC) is the most common minimally invasive surgery in which intraoperative access is provided with small keyhole entries on abdominal wall. LC causes moderate to severe postoperative pain which has different components; incisional pain from the trocar site (somatic pain), and local visceral pain (deep abdominal pain).<sup>1</sup> Many patients ALSO suffer from shoulder pain which is due to subdiaphragmatic irritation,

transmitted by phrenic nerve causing referred pain in C4 dermatome. Multimodal approaches with nonsteroidal anti-inflammatory drugs, dexamethasone, gabapentinoids, opioids, local anesthetic infiltration to port sites, epidural analgesia and transversus abdominis plane block (TAP) have been used to attenuate postoperative pain caused after LC.<sup>2</sup> Hebbard et al.<sup>3</sup> described the subcostal approach of TAP block for postoperative analgesia for upper abdominal surgeries. Many studies have reported that ultrasound guided oblique subcostal abdominis plane (OSTAP) blocks reduced postoperative pain scores and opioid consumption in the first 24 hrs after LC.<sup>4,5</sup> Although OSTAP block

\* Corresponding author.

E-mail address: [drsidharth74@gmail.com](mailto:drsidharth74@gmail.com) (S. Pani).

provides analgesia for somatic pain, it is ineffective in relieving visceral pain. Forero et al<sup>6</sup> described the ultrasound guided ESP block which is a novel technique targeting the ventral rami, dorsal rami, and rami communicantes of the spinal nerves there by effective against both somatic and visceral pain. Also after injection of the local anesthetic agent, spread of drug extend cranially and caudally over several dermatomal levels producing widespread analgesia. Few studies have reported that ESP block provided analgesia after different abdominal, thoracic, breast and spinal surgeries.<sup>7,8</sup> The present study was aimed to evaluate the analgesic efficacies of ultrasound-guided ESP block and OSTAP block after laparoscopic cholecystectomy surgeries. Our primary endpoint was the comparison of the total rescue analgesia consumption at the postoperative 24th hour between the two groups. The secondary endpoints were time of 1<sup>st</sup> rescue analgesia request, comparisons of NRS score at different time points, and complications in 1<sup>st</sup> 24 hrs.

## 2. Materials and Methods

This is a single blinded, prospective, randomized controlled study conducted at a tertiary care hospital after approval of institutional ethical committee between Sept 2018 and Sept 2019. All patients gave written informed consent for inclusion into this study. Patients aged 18–65 years with an American Society of Anesthesiologists (ASA) physical status classes of I and II who were scheduled to undergo elective LC were included in this study. Patients who refused enrolment, known allergy to regional anesthesia, those with bleeding diathesis, presence of severe kidney disease, BMI > 30 kg/m<sup>2</sup> and infection at the site of needle puncture were excluded from the study. Randomization was performed according to computer-generated random number tables, and allocation to treatment group was done using the sealed opaque envelope technique. According to randomization, patients were divided into two groups to receive either ultrasound guided ESP block or OSTAP block.

General anesthesia was administered to all patients in both groups. Standard monitoring procedures included pulse oximetry, electrocardiography, bispectral index and noninvasive arterial pressure. Ringers lactate (15 ml/kg) started after putting a 20 G iv cannula. All patients were premedicated with intravenous (i.v.) midazolam 0.04 mg/kg and fentanyl 2 mcg/kg. Induction was performed using propofol 2–3 mg/kg and vecuronium bromide 0.01 mg/kg and maintained with 0.6 minimum alveolar concentration sevoflurane with target BIS 40–60. Pneumoperitoneum was evacuated in all patients at the end of surgery and blocks were performed by the same anaesthesiologist. For all blocks, a GE Logiq F<sup>TM</sup> (General Electric Healthcare, Little Chalfont, United Kingdom) ultrasound with a high frequency (6–15 MHz) 38mm L6–12 linear probe and a Stimuplex<sup>(R)</sup> A 50mm (B Braun HNS 11-12218,

Stockert GmbH, Botzinger Strabe 72, D-79111 Freiburg, Germany) were used. 20 ml of bupivacaine 0.375% was administered to each side in each block. Then patients were extubated and transferred to the postoperative recovery room. Recovery room and ward follow up was performed by anaesthesiologist who were blinded to the group.

### 2.1. Erector spinae plane block

Patients were placed on their left side so that their right side was superior. The linear ultrasound transducer was placed in a longitudinal parasagittal orientation 2.5–3 cm lateral to the T9 spinous process. The erector spinae muscles were identified superficial to the tip of the T9 transverse process. A 21G 10-cm needle (B. Braun) was inserted using an out of plane approach. The tip of the needle was placed into the fascial plane on the deep (anterior) aspect of the erector spinae muscle. The location of the needle tip was confirmed by visible fluid spread lifting the erector spinae muscle off the bony shadow of the transverse process on ultrasonographic imaging. A volume of 20 mL of bupivacaine 0.375% was injected. Due to reports that ESP blocks visceral pain especially that of peritoneal distention, and as at least one trocar is placed in the midline, the same procedure was repeated for the opposite side.

### 2.2. Oblique subcostal transversus abdominis plane block

Blocks were performed in the supine position using a high frequency linear transducer with the in plane technique. The transducer was placed immediately below the costal margin on the oblique plane. The rectus abdominis, transverse abdominis, and internal oblique and external oblique muscles were identified. A 21G 10-cm needle (B. Braun) was inserted using an in plane approach from medially to laterally. 20 ml of bupivacaine 0.375% was injected between the fascia immediately above the rectus abdominis muscle.

Postoperative pain was evaluated using the numerical rating score (NRS). The NRS is a segmented numeric version of the Visual Analog Scale (VAS) in which a respondent selects a whole number (0–10) that best reflects the intensity of his/her pain. It is considered a one dimensional measure of pain intensity in adults. The 11-point numeric scale ranges from 0 representing no pain to 10 representing extreme pain. Changes in NRS at rest and on movement were recorded at different time intervals. During the 1<sup>st</sup> 24 hr postoperative period, Paracetamol 1 gm was given if Numeric Rating Scale score (NRS) > 4. Total consumption of paracetamol in 1<sup>st</sup> 24 hrs and time to 1<sup>st</sup> rescue analgesia was measured in both groups.

NRS pain scores was recorded at the 1st, 3rd, 6th, 9th, 12th, 15<sup>th</sup>, 18th, 21st and 24th hr both at rest and when coughing. Shoulder pain during the first 24 h and presence of postoperative nausea and vomiting were noted.

The severity of nausea was assessed by patients on a 4-point scale (none, mild, moderate, and severe). Sample size was calculated based on a pilot study with 10 patients in each group. 20% reduction in consumption of rescue analgesia in postoperative 24 hr was considered to be clinically significant. The mean Paracetamol consumption in ESP block group was  $2.08 \pm 0.9$  gm and  $2.9 \pm 0.64$  gm in OSTAP block group. Our study hypothesis was that, there was significant difference in rescue analgesia consumption in 1<sup>st</sup> 24 hr postoperatively as ESP block produces lower NRS score compared to OSTAP block.

Using power of 0.90 and significance level of 0.05. minimum sample size was calculated to be 28 patients for two groups each. Considering the possibility of dropouts, we decided to include 35 patients for each group.

Statistical Package for the Social Sciences version 16.0 statistical package program (SPSS Inc., Chicago, IL, USA) was applied for statistical analysis. Descriptive statistics were expressed as mean  $\pm$  standard deviation. For univariate analysis of means between the groups a 2 sample, independent t-test assuming equal variances were used. For data without normal distribution, Mann–Whitney U test was used. Ratios were compared using Chi square test and Categorical variables were compared using Fisher's exact test. Continuous variable was tested for normality via the Shapiro–Wilk test.  $P < 0.05$  was considered statistically significant.

### 3. Results

Seventy patients scheduled to undergo LC were evaluated for inclusion in this study. Two patients for coagulopathy, two for infection at block site, two for CRF, one for  $BMI > 25 \text{ kg/m}^2$  were excluded from the study. (Figure 1)

64 patients were included for randomisation. Two patients in each group were again excluded as LC was converted to open cholecystectomy. 60 patients completed the study. Average age, male to female ratio, ASA scores, average surgical time, block performing time and body mass index were similar in all groups. (Table 1)

Mean paracetamol consumption in 1<sup>st</sup> 24 hrs postoperatively was  $1.9 \pm 0.85$  gm in ESP group and  $2.84 \pm 0.29$  gm in OSTAP block which was statistically significant. ( $p < 0.05$ ) Time to 1<sup>st</sup> rescue analgesia was  $360.34 \pm 28.94$  min in ESP group and  $280.51 \pm 45.66$  min in OSTAP block which was statistically significant. ( $p < 0.05$ ) In ESP group 12 patients required rescue analgesia in 1<sup>st</sup> 12 hrs compared to 25 in OSTAP group which was statistically significant (Table 2).

In 1<sup>st</sup> 6hrs NRS score both at rest and on coughing was lower in ESP group than OSTAP group which was statistically significant ( $p < 0.05$ ). After 6 hrs NRS score was comparable in both groups. (Tables 3 and 4) No patient had right shoulder pain in either group. There was no statistical difference in complications in both groups. 4 patients in

ESP group and 6 patients in OSTAP group had nausea and vomiting which was not statistically significant. 2 patients in both group developed sedation. (table 5)

### 4. Discussion

In the current study Paracetamol consumption was significantly lower in the ESP group at 24 hr postoperatively compared to OSTAP group. Time to 1<sup>st</sup> rescue analgesia was prolonged in ESP group compared to OSTAP block which was statistically significant. Moreover, the NRS scores at rest and after coughing were significantly lower in the ESP group compared to OSTAP block. Larger no of patients in OSTAP block group required rescue analgesia compared to ESP group. There was no significant difference between the groups in postoperative complications. Acute pain following LC has different components: incisional pain from the trocar site, local visceral pain, parietal pain, and referred shoulder pain. Bisgaard et al.<sup>9</sup> reported that parietal pain due to a skin incision contributed more to laparoscopic pain than did other components. Recent studies evaluated the effect of OSTAP block for post-operative analgesia after LC.<sup>4,5,10</sup> Few studies have reported that TAP/OSTAP block provided analgesia for somatic pain and parietal pain of almost the entire anterior abdomen and effectively reduced postoperative pain.<sup>11</sup> Oksar et al.<sup>12</sup> compared the effects of intercostal-iliac TAP block, OSTAP block, and intravenous multimodal analgesia after LC, and they found that OSTAP block was more effective than the other methods in reducing postoperative pain scores. Similarly, Basaran et al.<sup>13</sup> reported that OSTAP block successfully reduced postoperative pain and improved respiratory function after LC. In a recent study, ultrasound guided OSTAP block was shown to provide effective analgesia in the entire anterior abdominal wall; however, TAP block was less effective over the lateral abdominal wall and there was almost no analgesic efficacy at the posterior abdominal wall. The authors reported that OSTAP block gradually weakened from the anterior to the posterior of the abdominal wall. Ramkiran et al.<sup>14</sup> compared the effectiveness of a rectus sheath block-OSTAP block combination, OSTAP block alone, and conventional port site infiltration in alleviating postoperative pain after LC. They reported that pain scores were significantly lower in the combination group at the second postoperative hour. In addition, opioid consumption in the postoperative 24 h was significantly lower in the combination group. Despite the reported successful outcomes of previous studies, the patchy pattern of sensory block over the lateral and posterior abdominal walls may cause discomfort in some patients after LC treated with OSTAP block. Visceral pain that occurs due to tissue trauma during gall bladder resection is generally accepted as the most predominant component after LC. Although OSTAP block can affect somatic and parietal components of postoperative pain after LC; however, the lack of a

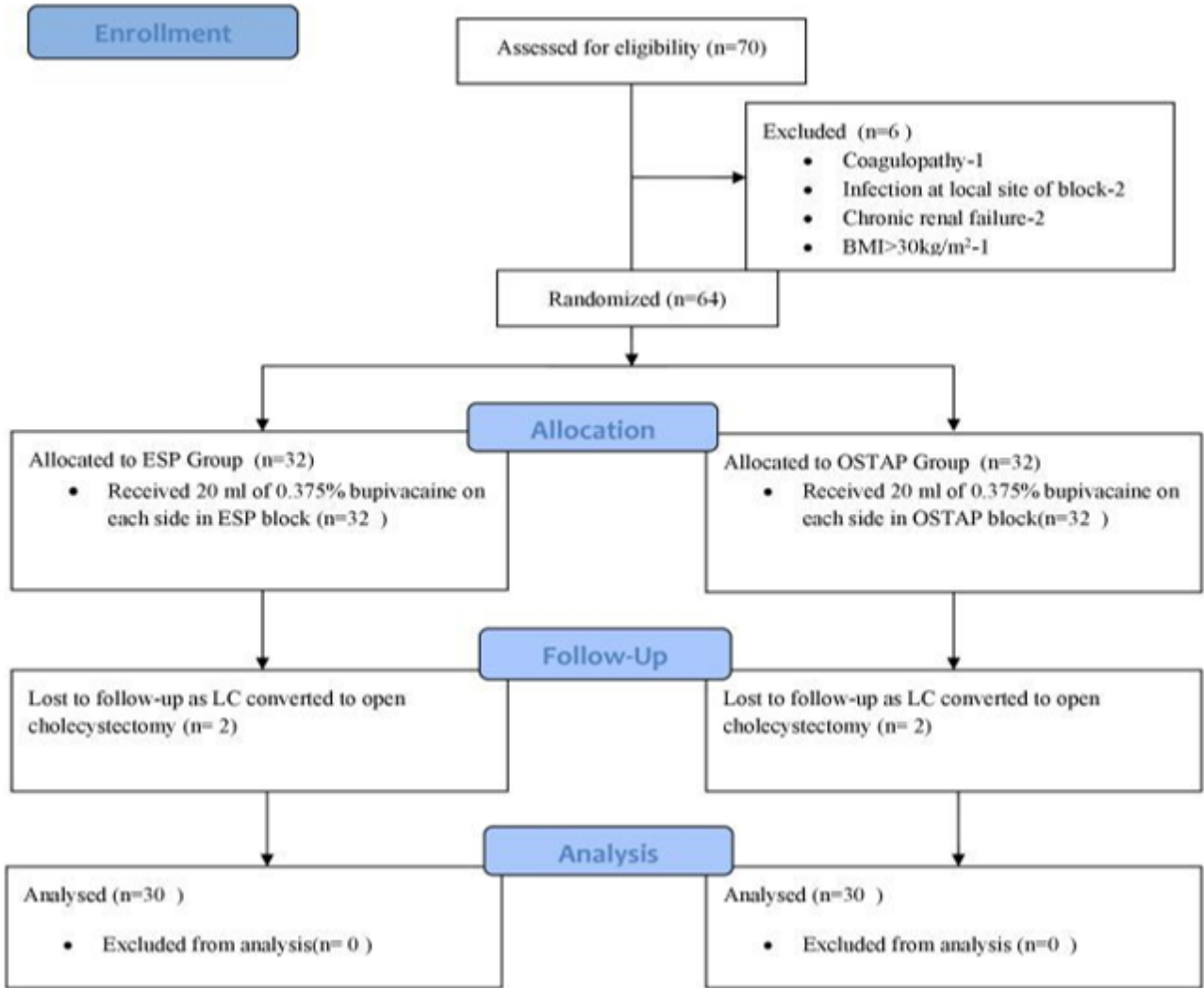


Fig. 1: Flow chart of study

Table 1: Descriptive variables of groups

	Group ESP(n=30 )	Group OSTAP (n=30)	P value
Age(years)	50.45±13.65	50.9±12.90	0.943
Female: Male(n)	18:12	16:14	0.789
ASA I/II (n)	16/14	15/15	0.684
Surgical time (mins)	48.84±8.45	52.6±7.81	0.360
Block performing time (mins)	7.85±1.43	7.2±1.81	0.473
BMI (kg/m <sup>2</sup> )	26.84±4.55	27.8±5.14	0.691

Table 2: Total analgesic consumption in 24 hrs and time to first analgesia request

Parameters	Group ESP(n=30)	Group OSTAP(n=30)	P value
Total analgesic consumption(Paracetamol in gm)	1.9±0.85	2.84±0.29	0.015
Time to 1 <sup>st</sup> rescue analgesia (mins)	360.34±28.94	280.51±45.66	0.028

**Table 3:** Evaluation of numeric rating scalescores at rest

Times of Measurement	Group ESP(n=30 )	Group OSTAP (n=30)	P value
20th min	1.15±2.64	2.4±2.50	0.014
40th min	1.95±1.68	2.75±1.94	0.017
1st h	1.98±1.4	2.85±1.1	0.019
3rd h	1.35±1.29	2.98±0.9	0.047
6th h	1.8±1.95	2.2±1.12	0.031
9th h	1.4±1.47	2.15±0.81	0.515
12th h	2.1±1.7	2.8±1.89	0.486
15 <sup>th</sup> h	2.4±0.9	2.90±1.10	0.495
18th h	2.16±1.31	2.65±1.81	0.510
21 <sup>st</sup> h	2.41±0.85	2.84±1.79	0.616
24th h	3.15±0.81	3.69±0.90	0.715

**Table 4:** Evaluation of numeric rating scale scores during coughing/movement

Time of measurement	Group ESP(n=30 )	Group OSTAP (n=30)	P value
20th min	1.16±2.15	2.84±2.34	0.016
40th min	1.99±2.31	2.81±2.16	0.011
1st h	1.94±2.10	2.98±2.23	0.014
3rd h	1.64±2.01	2.78±2.85	0.024
6th h	2.15±1.58	2.81±1.43	0.031
9th h	2.04±1.93	2.9±1.64	0.154
12th h	2.54±1.61	3.1±1.02	0.231
15 <sup>th</sup> h	2.81±1.04	3.43±1.49	0.196
18th h	2.95±1.05	3.47±1.61	0.178
21st h	3.01±1.15	3.04±1.19	0.179
24th h	3.10±1.14	3.16±1.80	0.211

**Table 5:** Incidence of PONV and sedation

	Group ESP (n=30)	Group OSTAP (n=30)	P value
Nausea	3	4	0.569
Vomiting	1	2	0.315
Sedation	2	2	0.492

visceral component may cause inadequate analgesia in some patients. Thus, an alternative approach to attenuating visceral pain as part of multimodal analgesia may be needed after LC. Ultrasound guided ESP block is an easily performed anesthesia technique, which leads to the blockage of both visceral and somatic nerve fibers making it excellent choice for postoperative analgesia.<sup>15</sup> ESP block has the potential to block the rami communicantes that transmit fibers to and from the sympathetic ganglia. Few studies are there in literature showing efficacy of ESP block for postoperative pain management after LC.<sup>15</sup> Tulgar et al.<sup>16</sup> described multimodal analgesia protocols in three patients who had endoscopic retrograde cholangiopancreatography, followed by LC. They performed ultrasound guided ESP block at the level of T8 with 10 ml of 0.5% bupivacaine 5 mL of 2% lidocaine and 5 mL of isotonic saline following anesthesia induction. They reported that the NRS scores of the patients were under 3/10 in an ambulatory surgical setting. In a recent study, Tulgar et al.<sup>17</sup> evaluated the effect of ultrasound guided ESP block on

postoperative pain scores and analgesic consumption after LC in a randomized controlled trial. In their study, they reported that they increased the bupivacaine concentration to 0.375% due to block failure and insufficient sensorial block. Aksu et al.<sup>18</sup> described the cases of three pediatric patients who received ESP block and IV paracetamol (15 mg/kg) for pain management after LC. They performed ESP blocks at the level of T7 with 0.5 mL.kg<sup>-1</sup> of 0.25% bupivacaine (maximum dose: 20 ml per each side) and found that none of the patients required rescue analgesia in the first postoperative 48 hours. Aksu C et al concluded that bilateral ESP block provides effective analgesia in pediatric LC.

Altıparmac et al<sup>19</sup> in their study concluded that ultrasound guided ESP block reduced the postoperative opioid consumption, pain scores, and intraoperative fentanyl requirements of patients more effectively than OSTAP block after LC surgery.

The ideal concentration of local anesthesia for ESP block in thoracic and abdominal surgeries was yet to

be determined. In a study by Kashani et al, 3.6 ml of local anaesthetic per vertebral level was reported to be adequate in ESP block.<sup>20</sup> However, spread of local anesthesia at different thoracic or lumbar vertebral levels may differ. So local anesthesia volume and concentration may vary according to patients' age and type of surgery to be performed.<sup>21</sup> Few studies have reported that, 20 ml of local anesthesia applied at T4 has been shown to spread caudal and cephalad for three to seven vertebral levels.<sup>22</sup> Though ideal concentration of local anesthetic for ESP block has yet to be decided, we in our study used 20 mL 0.375% bupivacaine. The most important reason for this difference is that ESP blocks facilitate greater dermatomal spread of local anesthetic agent in the fascial plane than does OSTAP block. The subcostal approach of TAP produces sensory blockade between the T6-T10 dermatomes. Therefore, OSTAP block provides analgesia especially for upper abdominal surgeries.

Vidal et al in a cadaveric study opined that ESP block produced epidural, neural foraminal, and intercostal spread of local anesthetic agent.<sup>23</sup> This more extensive spread of local anesthetic agent might have covered a larger dermatomal area than the OSTAP block. Also when ESP block was performed at a lower thoracic level, the local anesthetic was shown to spread anteriorly and enter the thoracic paravertebral space which may be the reason for producing wide spread analgesia. Thoracic epidural analgesia, thoracic paravertebral block, and quadratus lumborum block are the alternative approaches that can block both somatic and visceral pain. However, these approaches are not only difficult and time consuming but they can produce potential complications. Thoracic epidural analgesia was shown to be associated with longer hospital stay when compared with conventional analgesia.<sup>24</sup> Similarly, ultrasound guided thoracic paravertebral block can produce complication like pneumothorax.<sup>25</sup> But ultrasound guided ESP block can be performed simply and quickly with easily identified ultrasound landmarks which can provide the same benefits with less risk when compared with the alternative block techniques.<sup>26</sup> Limitation of our study was that, no data was collected to assess the success of both blocks. So we may have missed some block failure.

## 5. Conclusion

Ultrasound guided ESP block performed at the end of LC decreased consumption of analgesic in first 24 h and delayed the time of 1<sup>st</sup> analgesia request when compared to OSTAP block. But the volume and concentration of local anesthesia is still not clear which will provide adequate analgesia. So further studies are required to determine the ideal volume and concentration to produce quality analgesia in ESP block.

## 6. Source of Funding

None.

## 7. Conflict of Interest

None.

## 8. Acknowledgement

We are very thankful for the statistician for helping us in analysing the records.

## References

1. Abdelsalam K, Mohamdin OW. Ultrasound-guided rectus sheath and transversus abdominis plane blocks for perioperative analgesia in upper abdominal surgery: A randomized controlled study. *Saudi J Anaesth*. 2016;10(1):25–8.
2. Mitra S, Khandelwal P, Roberts K, Kumar S, Vadivelu N. Pain Relief in Laparoscopic Cholecystectomy-A Review of the Current Options. *Pain Pract*. 2012;12(6):485–96.
3. Hebbard PD, Barrington MJ, Vasey C. Ultrasound-Guided Continuous Oblique Subcostal Transversus Abdominis Plane Blockade. *Reg Anesth Pain Med*. 2010;35(5):436–41.
4. Breazu CM, Ciobanu L, Hadade A, Bartos A, Mitre C, Mircea PA. The efficacy of oblique subcostal transversus abdominis plane block in laparoscopic cholecystectomy-A prospective, placebo controlled study. *Rom J Anaesth Intensive Care*. 2016;23:12–8.
5. Shin HJ, Oh AY, Baik JS, Kim JH, Han SH, Hwang JW. Ultrasound guided oblique subcostal transversus abdominis plane block for analgesia after laparoscopic cholecystectomy: A randomized, controlled, observer-blinded study. *Minerva Anestesiol*. 2014;80(2):185–93.
6. Forero M, Adhikary SD, Lopez H, Tsui C, Chin KJ. The erector spinae plane block a novel analgesic technique in thoracic neuropathic pain. *Reg Anesth Pain Med*. 2016;41(5):621–7.
7. Hannig KE, Jessen C, Soni UK, Borglum J, Bendten TF, Presentation C. Erector spinae plane block for elective laparoscopic cholecystectomy in the ambulatory surgical setting. *Case Rep Anesthesiol*. 2018;p. 5492527.
8. Altıparmak B, Tokar K, Uysal M, Turan Aİ, M, Demirbilek G, et al. Efficacy of ultrasound-guided erector spinae plane block for analgesia after laparoscopic cholecystectomy: a randomized controlled trial. *Rev Bras Anestesiol*. 2019;69(6):561–568.
9. Bisgaard T. Analgesic Treatment after Laparoscopic Cholecystectomy. *Anesthesiol*. 2006;104(4):835–46.
10. Ma J, Jiang Y, Tang S, Wang B, Lian Q, Xie Z. Analgesic efficacy of ultrasound-guided subcostal transversus abdominis plane block. *Med (Baltimore)*. 2017;96(10):6309.
11. Chen Y, Shi K, Xia Y, Zhang X, Papadimos TJ, Xu X. Sensory assessment and regression rate of bilateral oblique subcostal transversus abdominis plane block in volunteers. *Reg Anesth Pain Med*. 2018;43:174–9.
12. Oksar M, Koyuncu O, Turhanoglu S, Temiz M, Oran MC. Transversus abdominis plane block as a component of multimodal analgesia for laparoscopic cholecystectomy. *J Clin Anesth*. 2016;34:72–8.
13. Basaran B, Basaran A, Kozanhan B, Kasdogan E, Eryilmaz MA, Ozmen S. Analgesia and respiratory function after laparoscopic cholecystectomy in patients receiving ultrasound-guided bilateral oblique subcostal transversus abdominis plane block: A randomized double-blind study. *Med Sci Monit*. 2015;21:1304–12.
14. Ramkiran S, Jacob M, Honwad M, Vivekanand D, Krishnakumar M, Patrikar S. Ultrasound-guided combined fascial plane blocks as an intervention for pain management after laparoscopic cholecystectomy: A randomized control study. *Anesth Essays Res*. 2018;12(1):16–23.
15. Chin KJ, Adhikary S, Sarwani N, Forero M. The analgesic efficacy of pre-operative bilateral erector spinae plane (ESP) blocks in patients having ventral hernia repair. *Anaesth*. 2017;72(4):452–60.

16. Tulgar S, Selvi O, Kapakli MS. Erector Spinae Plane Block for Different Laparoscopic Abdominal Surgeries: Case Series. *Case Rep Anesthesiol*. 2018;doi:10.1155/2018/3947281.
17. Tulgar S, Kapakli MS, Senturk O, Selvi O, Serifsoy TE, Ozer Z. Evaluation of ultrasound-guided erector spinae plane block for postoperative analgesia in laparoscopic cholecystectomy: A prospective, randomized, controlled clinical trial. *J Clin Anesth*. 2018;49:101-6.
18. Aksu C, Gurkan Y. Ultrasound-guided bilateral erector spinae plane block could provide effective postoperative analgesia in laparoscopic cholecystectomy in paediatric patients. *Anaesth Crit Care Pain Med*. 2019;38:87-8.
19. Altıparmak B, Toker MK, Uysal AI, Kuşçu Y, Demirebilek SG. Ultrasound-guided erector spinae plane block versus oblique subcostal transversus abdominis plane block for postoperative analgesia of adult patients undergoing laparoscopic cholecystectomy: Randomized, controlled trial. *J Clin Anesth*. 2019;57:31-6.
20. Kashani HH, Grocott HP. Clarity needed as to the optimal dose and volume of local anesthetic for erector spinae plane blockade for posterior rib fractures. *Am J Emerg Med*. 2018;36(6):1102-3.
21. Cassai AD, Tonetti T. Local anesthetic spread during erector spinae plane block. *J Clin Anesth*. 2018;48:60-1.
22. Ivanusic J, Konishi Y, Barrington MJ. A Cadaveric Study Investigating the Mechanism of Action of Erector Spinae Blockade. *Reg Anesth Pain Med*. 2018;43(6):567-71.
23. Vidal E, Giménez H, Forero M, Fajardo M. Erector spinae plane block: A cadaver study to determine its mechanism of action. *Rev Esp Anestesiología Reanim*. 2018;65(9):514-9.
24. Halabi WJ, Kang CY, Nguyen VQ, Carmichael JC, Mills S, Stamos MJ, et al. Epidural Analgesia in Laparoscopic Colorectal Surgery. *JAMA Surg*. 2014;149(2):130-6.
25. Park JS, Kim YH, Jeong SA, Moon DE. Ultrasound-guided aspiration of the iatrogenic pneumothorax caused by paravertebral block -a case report. *Korean J Pain*. 2012;25(1):33-7.
26. El-Boghdady K, Pawa A. The erector spinae plane block: plane and simple. *Anaesth*. 2017;72(4):434-8.

### Author biography

**Sidharth Sraban Routray** Associate Professor

**Ramakanta Mohanty** Associate Professor

**Kamalakanta Pradhan** Assistant Professor

**Soveena Pani** Resident

**Cite this article:** Routray SS, Mohanty R, Pradhan K, Pani S. Evaluation of efficacy of ultrasound guided erector spinae plane block and oblique subcostal transversus abdominis plane block for postoperative analgesia in laparoscopic cholecystectomy. *Panacea J Med Sci* 2020;10(2):128-134.