



Case Report

Oral submucous fibrosis- The disease of a betel quid chewer

Ramaraj P N¹, Vijaya Lakshmi G^{1,*}, Sneha Kulkarni¹, Nithin V M¹,
Ajeya Ranganathan¹

¹Dept. of Oral and Maxillofacial Surgery, KVG Dental College and Hospital, Sullia, Karnataka, India



ARTICLE INFO

Article history:

Received 19-08-2020

Accepted 28-08-2020

Available online 10-10-2020

Keywords:

Oral Submucous fibrosis

Coronoidectomy

Stage III OSF

Buccal fat pad

ABSTRACT

Oral Submucous Fibrosis (OSF) is a potential premalignant condition, mainly associated with the chewing of areca nut and is prevalent in South Asian population. In this paper we describe a case of oral submucous fibrosis treated surgically with bilateral excision, coronoidectomy and reconstruction with buccal fat pad and collagen. Early diagnosis and management reduces the need for surgical intervention. However due to advances in the surgical field, management is not cumbersome as earlier. This case report briefs about the management of a stage III case of OSF, and a protocol for management of the disease as a whole.

© 2020 Published by Innovative Publication. This is an open access article under the CC BY-NC license (<https://creativecommons.org/licenses/by-nc/4.0/>)

1. Introduction

Pindborg (1966) defined Oral Submucous Fibrosis (OSF) as “A chronic progressive scarring disease of oral cavity and oropharynx characterized by epithelial atrophy and juxtaepithelial inflammatory reaction with progressive fibrosis of lamina propria and deeper connective tissues resulting in stiffness of oral mucosa and causing progressive decrease in mouth opening”.¹ OSF is a potential premalignant condition with an incidence of oral cancer in 3-7.6% cases.² It is principally associated with areca nut chewing, an additive of betel quid, and is widespread in South Asian populations. The constituents of areca nut are alkanoids (Arecoline, Arecaidine, Arecolidine, Guyacoline, Guacine) and flavanoids (Tannins and Catechins) which increase the collagen production and decrease the collagen degradation in the oral mucosa leading to fibrosis. Other factors include genetic, nutritional deficiencies and immunologic predisposition.³ Initially patients present with burning sensation in the oral mucosa, which eventually progresses to visible bands in the labial and buccal mucosa, soft palate, faucial pillars leading to severe trismus

in the later stages of the disease.¹ Depending on the clinical and functional stage, various medical and surgical modalities of treatments are available for management of OSF. The mild cases can be treated conservatively with medications and physiotherapy, however with increase in the severity of disease, surgical excision of bands and releasing fibrosis with/without coronoidectomy benefits the mainstay for management.

The purpose of this paper is to describe a case of oral submucous fibrosis surgically managed with local wide excision of fibrotic bands bilaterally and bilateral coronoidectomy, followed by reconstruction with pedicled buccal fat and collagen performed under general anaesthesia.

2. Case Report

A 32-year-old female came to the department of OMFS, KVGDC with a chief complaint of difficulty in opening mouth in the last 3-4 years. On elucidating history of presenting illness, mouth opening reduced gradually over past 2 years. History of burning sensation was present in the past 2 years and was associated with pain which was gradual in onset, severe, intermittent, aggravated on having food and

* Corresponding author.

E-mail address: drvijaya247@gmail.com (V. Lakshmi G).

no relieving factor. No relevant previous medical history. Patient underwent intralesional hyaluronidase injection for the same 2 months ago. Patient had history of chewing areca nut for last 16 years and had quit from 1 month.

On clinical examination, extraoral inspection, facial asymmetry was present, interincisal opening (IO) was inadequate (15 mm) (Figure 1), TMJ bilaterally palpable and non-tender. Intraoral inspection, marble like blanching was present bilaterally in buccal mucosa extending till retromolar trigone. Lateral border of tongue was ulcerated and de-papillated. Uvula was shrunken. Intraoral palpation, vertical fibrotic bands were palpable bilaterally in buccal mucosa, RMT, palate and upper labial mucosa (Figure 2).

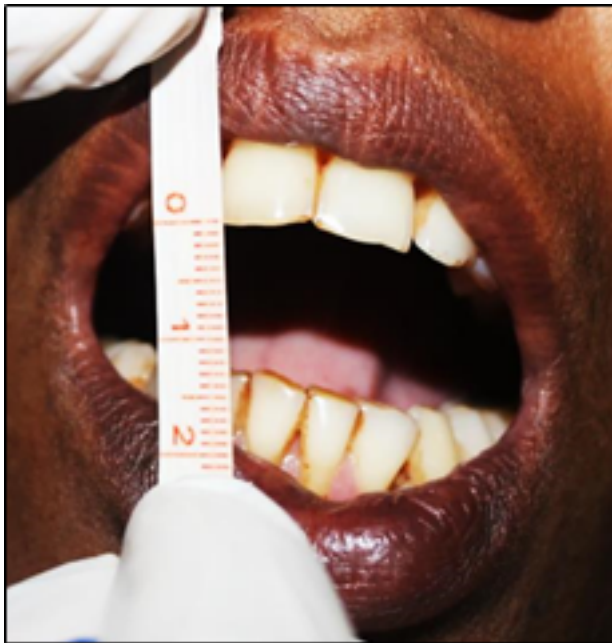

Fig. 1: Pre-op IO

Incisional biopsy was performed and confirmed as oral submucous fibrosis. Final diagnosis was made as OSF grade III.

3. Surgical Technique

Written informed consent was obtained from the patient for the proposed surgery under general anaesthesia. Incision was placed circumorally and fibrotic bands were excised. At the level of occlusion, incision was placed bilaterally and fibrotic bands were excised bilaterally (Figure 3). Incision was extended posteriorly; anterior border of ascending ramus and coronoid process was identified, temporalis muscle attachments were relieved and coronoidectomy was performed bilaterally (Figure 4). Mouth opening was evaluated and was 30 mm. Reconstruction was done with buccal pad of fat harvested bilaterally and advanced into the defect, covered with collagen membrane and secured

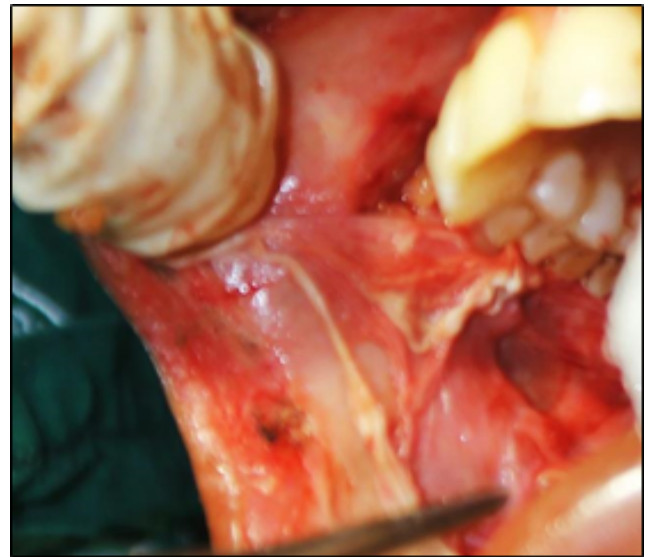


Fig. 2: Fibrous bands oriented vertically in buccal mucosa, labial mucosa and RMT region

using 3-0 vicryl sutures intermittently. Intraoral bolus was placed over the collagen membrane bilaterally and was secured with 2-0 silk suture, which was removed on 3rd post-operative day (Figure 5).

Vigorous mouth opening exercises were carried out using ice-cream sticks (Figure 6) and Ferguson's mouth gag to prevent fibrosis and to maintain adequate mouth opening.

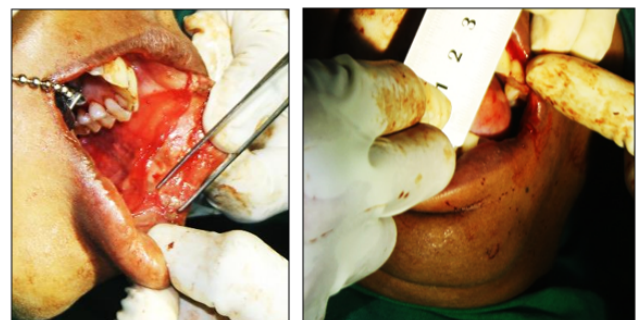


Fig. 3: Excision of fibrous bands and measuring inter incisal mouth opening (IO)

4. Discussion

OSF is significantly related to the disturbance in collagen metabolism and one of the most common aetiological factors being areca nut chewing habit. Flowchart 1 depicts the etiology and mechanism of action progressing to the disease. The continuous chewing of quid also leads to increased activity of the muscles used in mastication, depletion of glycogen, and muscle fatigue. The reduced blood supply following fibrosis which further promotes

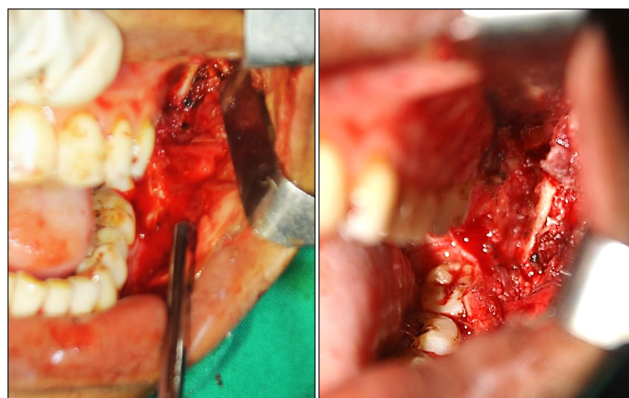


Fig. 4: Temporalis myotomy and coronoidectomy performed bilaterally

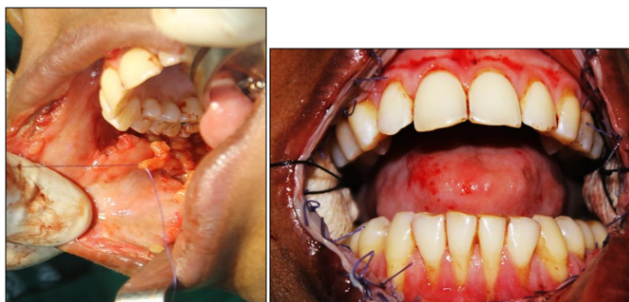


Fig. 5: Reconstruction of the defect with buccal fat pad and collagen membrane. Intra oral bolus placed

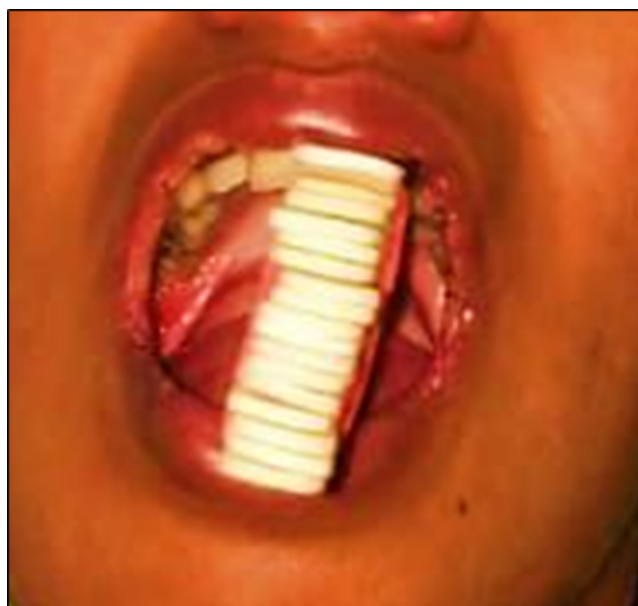

Fig. 6: Post-operative mouth opening exercises using ice-cream sticks

muscle fatigue and causes substantial degeneration and fibrosis in the muscles.⁴ Occurrence of OSF in genetically susceptible individuals due to raised expression of HLA (Human Leukocyte Antigen) and SCE (Sister Chromatid Exchanges) has also been suggested.⁵

In the initial stage of the disease, most patients present with burning sensation or intolerance to spicy food and vesicles most commonly over the palatine mucosa.⁴ As the disease progresses, there is dryness of mouth, followed by fibrosis of the oral mucosa, leading to rigidity of the lips, tongue, and palate and trismus. Clinically, visible blanched, slightly opaque and white oral mucosa and fibrous bands appear giving a characteristic marble like appearance. The disease progresses usually symmetrically. The fibrous bands in the buccal mucosa run in vertical direction. The fibrous bands in the soft palate have a scar like appearance. The uvula, involved in the later stages - shrinks and appears as a small fibrous bud followed by shortening and thickening of faucial pillars which harden with time.¹ Changes in the integrity of the epithelium and its maturity are affected due to iron deficiency and may lead to the malignant transformation of the condition. The trace elements and the variable levels of lipids also contribute to the scenario and progression.⁵

The treatment modalities are based on the stage of the disease and are divided into conservative and surgical mode of treatment.⁶ Stage I (IO ≥ 35 mm), II (IO 26-35 mm) and mild cases of Stage III (IO 20-25mm) can be treated conservatively with physical therapy and medical treatment. However severe cases of stage III (IO 15-20mm) and all the cases in stage IV (IO ≤ 15 mm) should be managed both surgically, followed by a physical therapy and medical treatment.⁶ Table 1 explains about the management of OSF.

With the advances in surgery and various experimental studies, there are several modes of surgical management of OSF but begin with the excision of the fibrotic bands and releasing the fibrosis. Excision may be performed with scalpel, electro cautery or LASER. Though laser gives precision in cutting, it can be used only in scenarios where adjuvant treatment is not advised. The reconstruction options vary from covering the mucosal defect with collagen membrane, split skin graft, use of locally advanced flaps to free flaps and can be opt based on the patient's general health and economic condition.¹⁰ In our case report, reconstruction was done with buccal pad of fat, due to proximity to the operated site and native vascularity. Yeh, first reported the use of Buccal Fat pad with minimal donor site morbidity and excellent outcome, where it eventually transforms into normal mucosa.¹¹ Literature also supports using tongue flap, but postoperative difficulty in speech and mastication affect the individual's lifestyle. Extraoral flaps like nasolabial and temporalis fascia flap can be used for reconstruction. Nasolabial flap provides easy access with a healthy vascular pedicle and non-involvement of

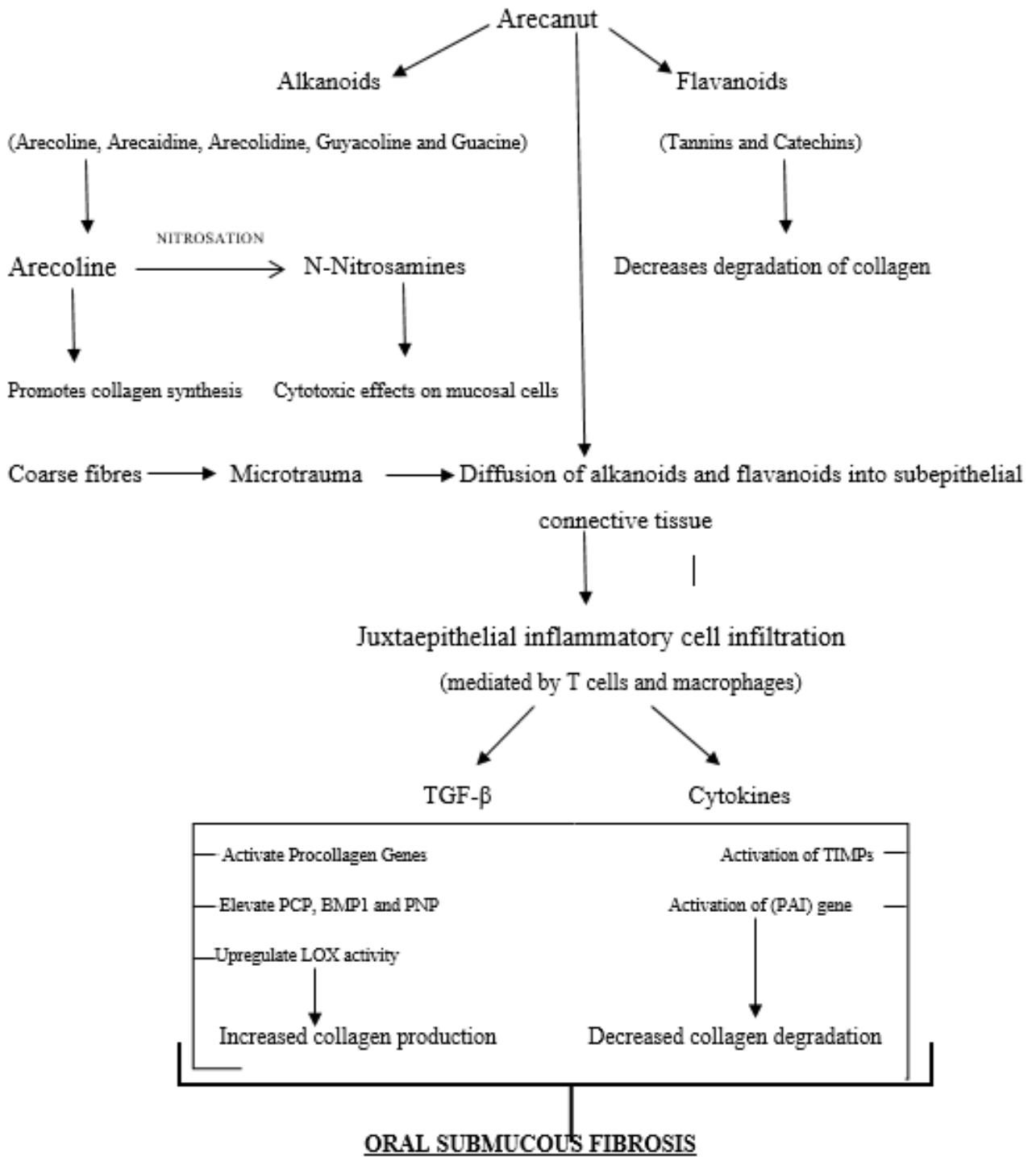


Chart 1: Etiopathogenesis of Oral Submucous Fibrosis(OSF)
 (TGF-β- Transforming Growth Factor Beta; TIMPs –Tissue Inhibitors of Metalloproteinases; PCP- procollagen C-proteinase; PNP-procollagen N-proteinase; PAI- plasminogen activator inhibitor)

Table 1: Management of Oral Submucous Fibrosis (OSF)

Conservative Management ⁶		
	Objective	Treatment
Physical Therapy	Tissue remodelling using movement	Regular exercises Physiotherapy Intra oral splints Localised heat Microwave diathermy
Medical treatment (oral, topical, submucosal injections)	<ul style="list-style-type: none"> • Alleviate burning symptoms in oral mucosa • Try to reverse pathological process 	<p>Modulation of inflammation and immunity-</p> <ul style="list-style-type: none"> • Steroids • Interferon γ • Colchicine • Immunised milk • Placental extract • Levamisole <p>Promotion of oral mucosal blood flow</p> <ul style="list-style-type: none"> • Pentoxifylline • Buflomedil hydrochloride • β-adrenergic agnoist drugs (Nylidrin hydrochloride,) <p>Anti-oxidants, nutrients, micronutrients therapy (AONMT)</p> <ul style="list-style-type: none"> • Beta-carotene • Lycopene⁷ • Tea pigments • Vitamin and mineral supplements⁸ <p>Fibrinolytic therapy</p> <ul style="list-style-type: none"> • Hyaluronidase • Chymotrypsin • Collagenase <p>Other drugs</p> <ul style="list-style-type: none"> • Anti-TGF β • Agents, • Copper chelators, • Borneol, • Garlic extracts, • Oxitard, • Danuxan Koukung, • Aloe vera, • Pirfenidone • Turmeric or curcumin longa Linn
Surgical Management ⁹		
Physical division of fibrosed tissue with post-operative maintenance of gap created by muscle release	<p>improve mouth opening</p> <ul style="list-style-type: none"> - restore articulation - mastication - oral hygiene -surveillance for early cancer diagnosis 	<p>Masticatory muscle myotomy Coronoidectomy- unilateral/contralateral Resurfacing of surgical defect</p>

the flap in the disease condition. Facial scarring, deformed nasolabial fold, hair development on the flap and restricted width of the flap have limited its use in OSF. Though temporalis fascia flap can be used in extensive cases with good results, it is the farthest local flap and the need to cover the flap with skin graft, temporal hollowing make it the least popular flap. Radial free fore arm flap and anterolateral thigh flap are some of the free flaps used in extensive cases and high esthetic outcomes, but are rarely used for mere treatment of OSF. Use of grafts like split skin graft, artificial dermis, human placenta, amnion, collagen

membrane provide passive coverage, however innate steroid therapy and collagen degradating enzymes in the placenta and amnion is of therapeutic benefit. The adjuvant therapy is performed when intraoperative mouth opening achieved is not adequate. In our case, temporalis muscle myotomy and bilateral coronoidectomy was performed. This helped in achieving adequate mouth opening in short duration of time. The maintenance of mouth opening is achieved by physiotherapy, but lack of cooperation and pain due to vigorous mouth opening, as observed in our patient, should be managed with frequent consolation and benefits of the

treatment.¹⁰ Use of prosthetic devices, like oral stents in the maintenance of the postoperative oral opening is also reported.⁹

5. Conclusion

Oral submucous fibrosis is a potential premalignant condition prevalent in South Asian population. Early diagnosis and management reduces the need for surgical intervention. However, treatment modalities for the terminal stage of the disease forms an integral part of the management protocol and hence should be given importance. This case report briefs about the management of a stage III case of OSMF, and a protocol for management of the disease as a whole.

6. Source of Funding

None.

7. Conflict of Interest

None.

References

1. Pindborg JJ, Sirsat SM. Oral submucous fibrosis. *Oral Surg Oral Med Oral Pathol Oral Radiol.* 1966;22:764–78.
2. Soodan KS, Priyadarshni P, Kshirsagar R, Kaur A, Soodan PS. Treatment Modality for Advanced Oral Submucous Fibrosis. *IOSR J Dent Med Sci.* 2015;14(2):76–9.
3. Auluck A, Rosin MP, Zhang L, Sumanth KN. Oral submucous fibrosis, a clinically benign but potentially malignant disease: report of 3 cases and review of the literature. *J Can Dent Assoc.* 2008;74(8):735–40.
4. Arakeri G, Brennan PA. Oral submucous fibrosis: an overview of the aetiology, pathogenesis, classification, and principles of management. *Br J Oral Maxillofac Surg.* 2013;51:587–93.
5. Abraham RR, Pallath V, AM C, Ramnarayan K, Kamath A. Avenues for Professional Development: Faculty Perspectives from an Indian Medical School. *Nepal Journals Online (JOL);* 2014. Available from: <https://dx.doi.org/10.3126/kumj.v10i4.10997>. doi:10.3126/kumj.v10i4.10997.
6. Arakeri G, Rai KK, Boraks G, Patil SG, Aljabab AS, Merckx MAW. Current protocols in the management of oral submucous fibrosis: An update. *J Oral Pathol Med.* 2017;46(6):418–23.
7. Arakeri G, Patil S, Maddur N, Rao V, Subash A, Patil S, et al. Long-term effectiveness of lycopene in the management of oral submucous fibrosis (OSMF): A 3-years follow-up study. *J Oral Pathol Med.* 2020;49(8):803–8.
8. Mandal BK, Das R. Comparative study of conventional local steroid injections only with multi-drugs therapy and steroid injections in oral submucosal fibrosis (OSMF). *Glob J Res Anal.* 2019;8(6).
9. Kamath VV. Surgical Interventions in Oral Submucous Fibrosis: A Systematic Analysis of the Literature. *J Maxillofac Oral Surg.* 2015;14:521–31.
10. Baumann A, Ewers R. Application of the buccal fat pad in oral reconstruction. *J Oral Maxillofac Surg.* 2000;58(4):389–92.
11. Le PV, Gornitsky M. Oral stent as treatment adjunct for oral submucous fibrosis. *Oral Surg, Oral Med, Oral Pathol, Oral Radiol, Endodontol.* 1996;81:148–50.

Author biography

Ramaraj P N Professor and HOD

Vijaya Lakshmi G PG Student

Sneha Kulkarni PG Student

Nithin V M PG Student

Ajeya Ranganathan PG Student

Cite this article: Ramaraj P N, Lakshmi G V, Kulkarni S, Nithin V M, Ranganathan A. Oral submucous fibrosis- The disease of a betel quid chewer. *Int J Oral Health Dent* 2020;6(3):236-241.