



## Case Report

# Hollow bulb obturator and implant retained mandibular overdenture for a compromised completely edentulous patient with partial maxillectomy

Harmanpreet Atwal<sup>1,\*</sup>, Tanuj Mendiratta<sup>1</sup>, Anup Gopi<sup>1</sup>, Rajesh Kumar Yadav<sup>1</sup>

<sup>1</sup>Dept. of Prosthodontics and Crown & Bridge, Army Dental Center (Research & Referral), New Delhi, India



### ARTICLE INFO

#### Article history:

Received 26-07-2020

Accepted 12-08-2020

Available online 10-10-2020

#### Keywords:

Hollow bulb obturator

Maxillectomy

Mandibular overdenture

Monoplane plane occlusion

Balancing ramp

### ABSTRACT

A large maxillary defect situation is often challenging in terms of prosthetic rehabilitation considering the lack of retention, facial support and limited mouth opening along with psychological and functional trauma to the patient. In such situations we aim to successfully rehabilitate the defect in terms of function and aesthetics while ensuring complete obturation of the defect. A 65 years old female with maxillary surgical defect of right side due to squamous cell carcinoma resection along with associated limited mouth opening and post surgical scar contracture reported for prosthetic rehabilitation. This paper describes in detail an unconventional method for the fabrication of a modified hollow bulb obturator with an implant retained mandibular overdenture with monoplane occlusion and balancing ramps. This not only closed the oro-antral communication but also enhanced the masticatory performance, speech and psychological status of the patient. Decreased weight of the prosthesis and an implant retained mandibular overdenture with monoplane occlusion and balancing ramps improved retention, stability and support of the prosthesis, thereby, improving the quality of life after extensive maxillectomy.

© 2020 Published by Innovative Publication. This is an open access article under the CC BY-NC license (<https://creativecommons.org/licenses/by-nc/4.0/>)

## 1. Introduction

Obturator for a large maxillary defect presents a challenge due to its undesirable weight which reduces the retention, stability and support of the maxillofacial prosthesis leading to loss of peripheral seal and traumatic functional occlusion. Therefore as a standard practice obturators are hollowed out in the defect portion to reduce its weight and improve its function.<sup>1</sup>

Wu YL and Schaaf designed different types of obturator prostheses (both solid and hollow) which were evaluated for the amount of weight reduction. They concluded that there was a significant weight reduction in hollow obturator prosthesis, from 6.55% to 33.06% which in turn depends on the size of the defect.<sup>1</sup> Hollow obturator can be of two types: open from the top (open-hollow) or completely closed (closed- hollow). The open hollow obturator presents a disadvantage of secretions collection

which requires frequent cleaning or exit holes to prevent the fluid accumulation<sup>2</sup> whereas closed obturator does not have the problem of fluid collection but it reduces the air space.<sup>3</sup>

Variety of methods have been described in the literature to fabricate closed hollow bulb obturator, out of which most of the techniques describe the incorporation of various heat labile materials during packing stage or by doing multiple processing or making two piece components and later sealing them to make it a hollow prosthesis. In this article a single step processing technique using a pre shaped “wax-bolus” has been described to fabricate a single piece closed-hollow bulb obturator with reduced weight and uniform wall thickness around the hollow space.

## 2. Case Report

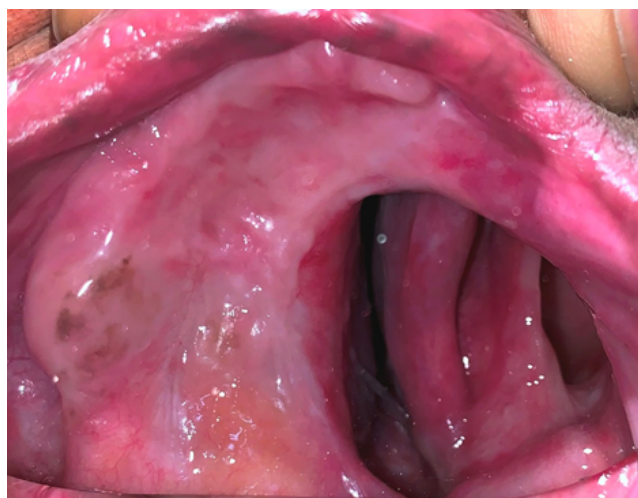A 65-year-old female patient was referred from the Department of Otorhinolaryngology to the Department of Prosthodontics for prosthetic rehabilitation of a large maxillectomy defect right side [Figure 1]. On elicitation of

\* Corresponding author.

E-mail address: [prettyatwal@gmail.com](mailto:prettyatwal@gmail.com) (H. Atwal).

dental history it was found that the patient was diagnosed with squamous cell carcinoma right side maxilla for which partial maxillectomy was performed followed by reconstructive surgery using temporal fascia and muscle of right side. Later, due to the failure of reconstructive attempt the patient was rehabilitated with obturator prosthesis for maxilla and complete denture for the mandibular arch.

The prosthesis performance was unsatisfactory and patient complaint of difficulty in mastication along with nasal regurgitation of fluids, poor esthetics and difficulty in speech with nasal twang in her voice while using the existing prosthesis. Orthopantomograph radiographic evaluation was done which revealed defect site of right maxilla and insufficient bone volume of left maxilla making an implant retained obturator prosthesis as an invalid treatment option. So a decision of a hollow bulb obturator fabrication using wax bolus technique along with implant retained ball attachment mandibular overdenture with monoplane occlusion and balancing ramps was planned for this case.



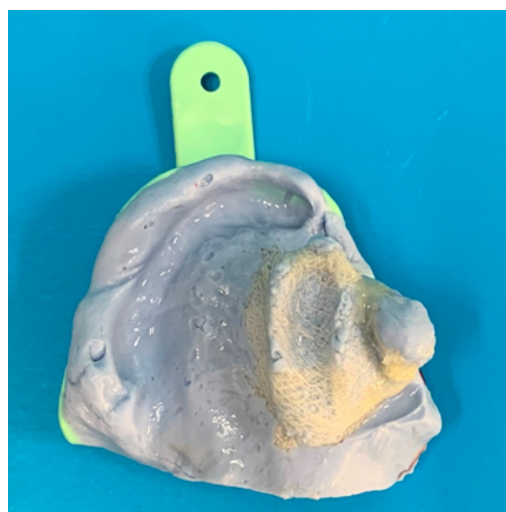**Fig. 1:** Right side maxillectomy defect

### 3. Procedure

#### 3.1. Impression

Preliminary impression for maxillary arch was made using irreversible hydrocolloid (Zelgan 2002, DENTSPLY, India) after blockout of the defect site using paraffin gauze and for mandibular arch using impression compound (Y-dents, MDM Corporation) [Figure 2] followed by custom tray fabrication using auto-polymerizing acrylic resin (DENTSPLY, India). Border moulding for maxillary arch was done by green stick compound (DPI Pinnacle, Dental Products of India) using sectional technique and final impression was made with light body addition silicone impression material (Variotime, Kulzer) [Figure 3

a] followed by fabrication of the master cast using dental stone. Admix impression technique<sup>4</sup> was used to make mandibular impression for the resorbed ridge using impression compound (DPI Pinnacle tracing sticks) and green tracing stick compound in ratio of 3:7 parts by weight [Figure 3 b]. Both the components were placed in a bowl of water at 60 degrees Celsius and kneaded to homogenous mass which was then loaded on to the tray and the patient was asked to do various tongue movements. The impression obtained was then poured to obtain the mandibular master cast.



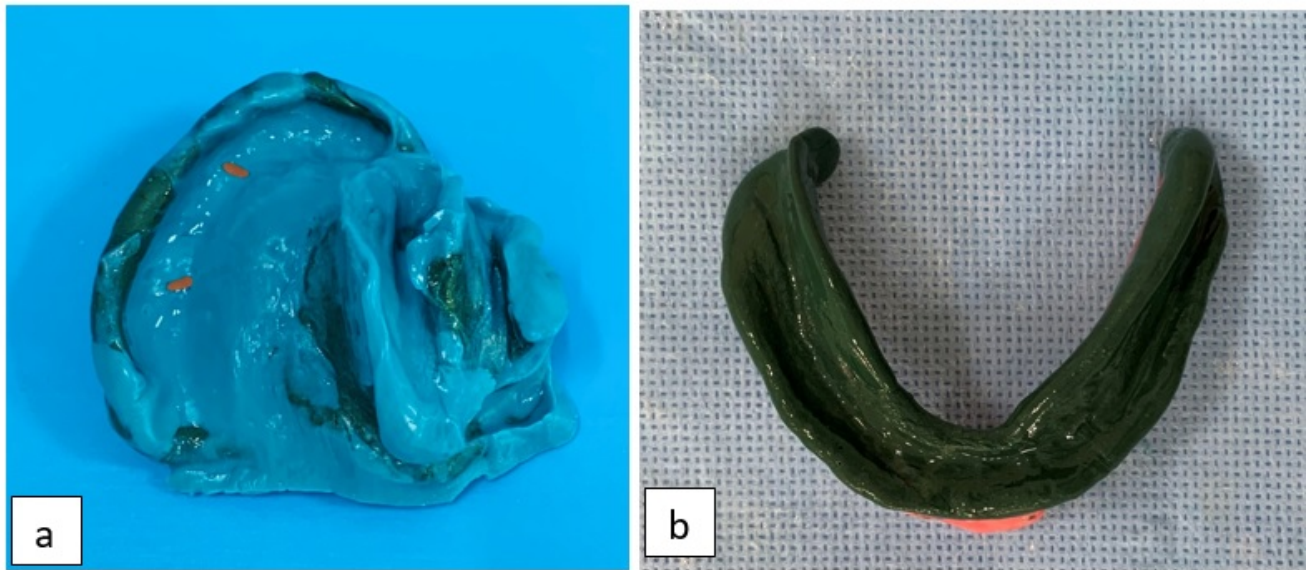
**Fig. 2:** Preliminary maxillary impression

#### 3.2. Maxillomandibular relation

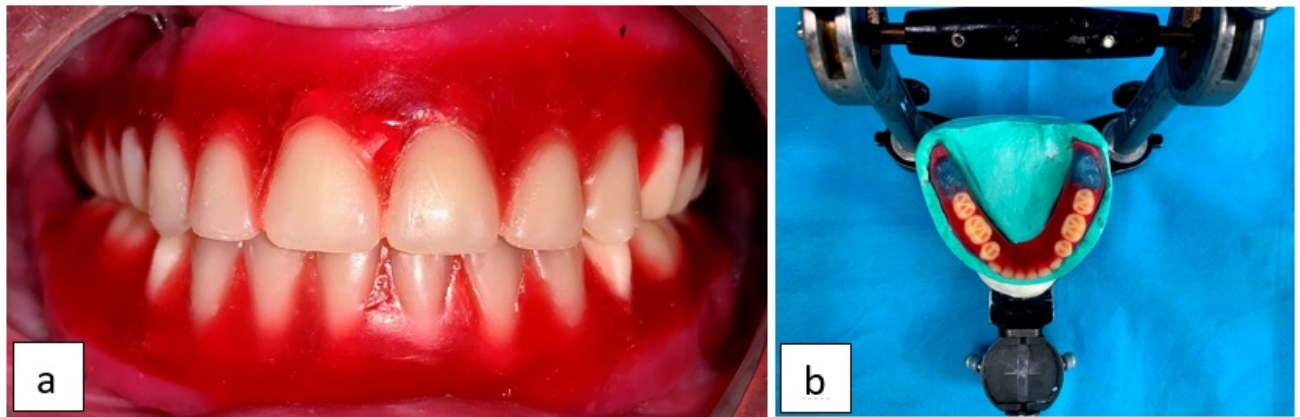
The undesirable undercuts present in the defect were blocked out by dental plaster in the cast except lateral undercut to improve retention. This was followed by denture base and occlusal rim fabrication. The maxillomandibular relationship was recorded and mounted on to the programmed articulator. As the patient had poor neuromuscular coordination, it was decided to use non anatomic teeth establishing monoplane occlusion along with balancing ramps for better comfort and stability of maxillary obturator being the weaker arch.

#### 3.3. Try -In & balancing ramps

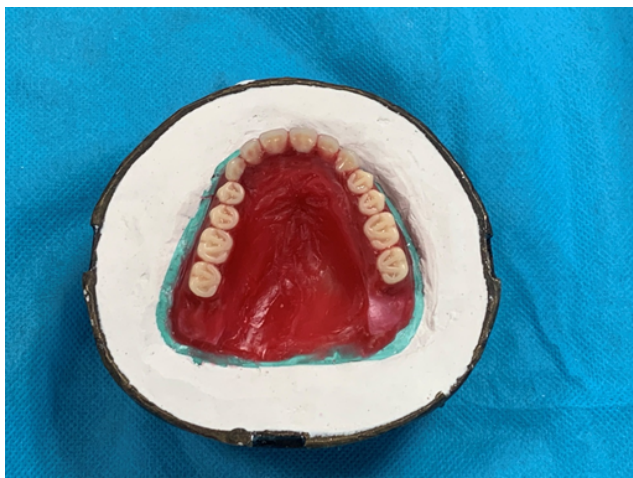The trial of the denture was done in the routine manner [Figure 4 a] and at this time mouth temperature wax (Aluwax Dental Products Company, USA) was placed on the distal aspect of mandibular second molar and the patient was asked to perform functional movements of protrusion and lateral excursive movements. The pattern was recorded [Figure 4 b] and the final wax up was done before the demounting procedure. Palatal rugae wax up was done for maxillary arch to give patient a more natural feel [Figure 5].



**Fig. 3:** Final impression of maxillary & mandibular arch



**Fig. 4:** Trial of prosthesis and mouth temperature wax used for fabricating balancing ramp



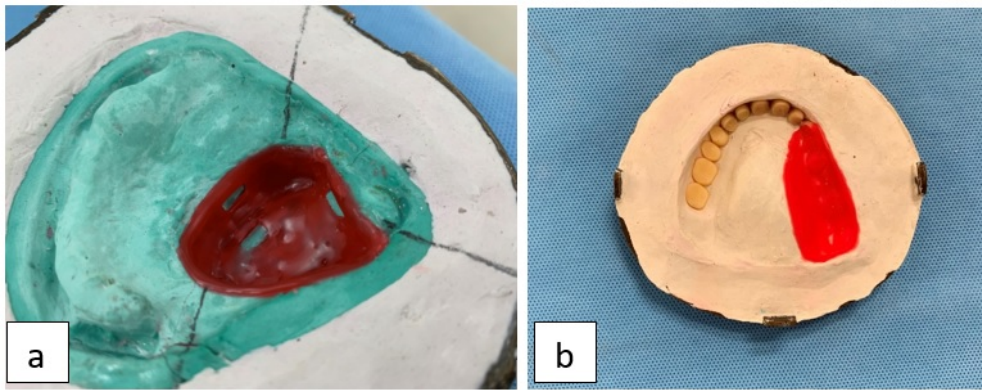
**Fig. 5:** Palatal rugae wax up

### 3.4. Processing

Using the conventional technique flasking was done followed by dewaxing procedure. It was followed by removal of record bases from the flask and three widely distributed straight lines which extended from defect site to the investing plaster were marked for easy re-orientation of wax bolus in its original position during packing.

Double thickness baseplate wax was adapted on both maxillary cast and dewaxed plaster surface followed by preparation of 3 widely spaced windows (3mm X 3mm). It was followed by petroleum jelly application to the adapted wax sheets [Figure 6 a,b].

An approximate estimation for the total surface area of the hollow space created between two adapted wax sheets was done and accordingly a wax-bolus was made for filling-up the same space. The bolus was then placed on adapted



**Fig. 6:** Baseplate wax with windows adapted on maxillary cast

wax sheet and the flask was closed in this position under clamp for 10 mins under tap water. After the separation of the flasks the excess flush of wax was removed and any deficiencies were observed for and corrected. Elevated areas corresponding to the windows created on adapted wax sheet were created which helped in seating the bolus in its desired position during packing stage [Figure 7]. The adapted wax sheets were then removed and the wax bolus was placed in its original position using three lines marked on the cast and investing plaster [Figure 8].



**Fig. 7:** Wax bolus with elevated areas corresponding to windows

Packing was done using heat polymerised acrylic resin (Lucitone, Dentsply, USA) on which the wax bolus was oriented using the three lines till all the stops rested in its original position [Figure 9 a]. On the counter flask remaining portion of acrylic resin was placed [Figure 9 b] and closed with base flask and placed under mechanical clamp.

Bench curing was done at room temperature for 24 hrs followed by curing cycle which was performed according to manufacturer's instructions. After curing bench cooling was done for 24 hrs followed by separation of flasks. It was observed that the obturator had 3 to 5 openings with



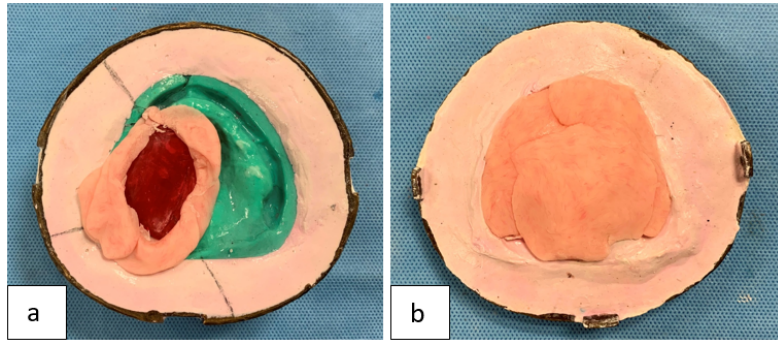
**Fig. 8:** Wax bolus in position with orientation lines extended onto the bolus

the residual portion of wax bolus completely enclosed by acrylic resin as it melted and vented out of the holes during curing cycle. The remaining portion of the wax bolus was removed by pouring hot water removing residual wax from the holes [Figure 10 a]. The holes were sealed using autopolymerising acrylic resin forming a hollow bulb obturator [Figure 10 b].

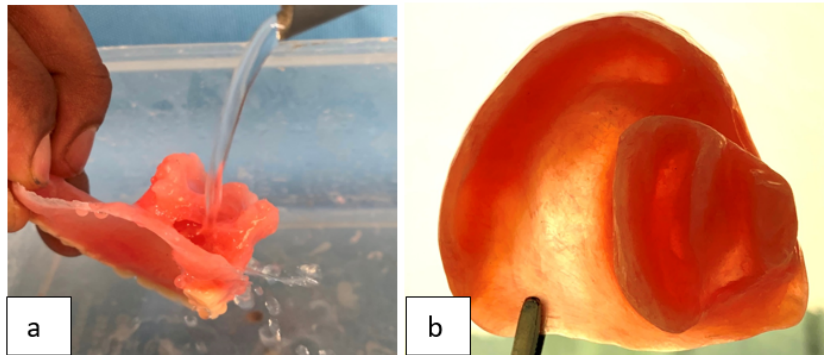
The mandibular denture was fabricated in conventional manner. Final finishing and polishing of the dentures was done, ready to be placed in situ.

### 3.5. Implant placement in mandibular arch

Once the dentures were fabricated, implants of size 3X10mm (AB Dental Implant, USA) post CBCT (Cone Beam Computed Tomography) evaluation were placed in mandibular arch at B&D position along with ball attachments using duplicated denture as a surgical stent [Figure 11]. Recesses were created for minimum loading of implants and to accommodate the future attachment housings. After 3 months of osseointegration, loading of

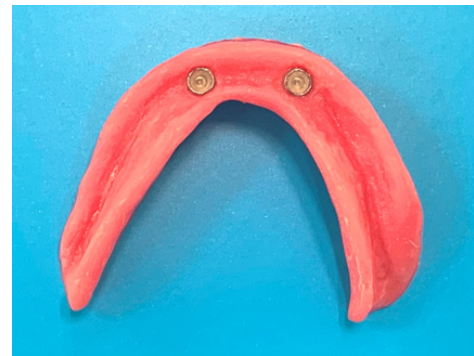

**Fig. 9:** Packing done with wax bolus in position

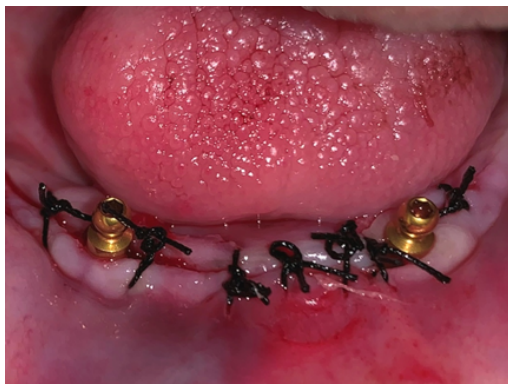

**Fig. 10:** Residual portion of wax removed & holes sealed to form a hollow bulb obturator

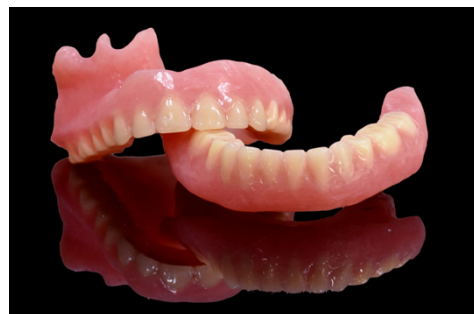two implants was done. Housing with the nylon insert was placed on the attachment and recesses were filled with autopolymerising resin. Insertion of the denture was done and patient was guided into proper occlusion. After curing, the metal housing was retrieved in the denture [Figure 12], excess acrylic was trimmed off and the overdenture was seated over the ball attachment.



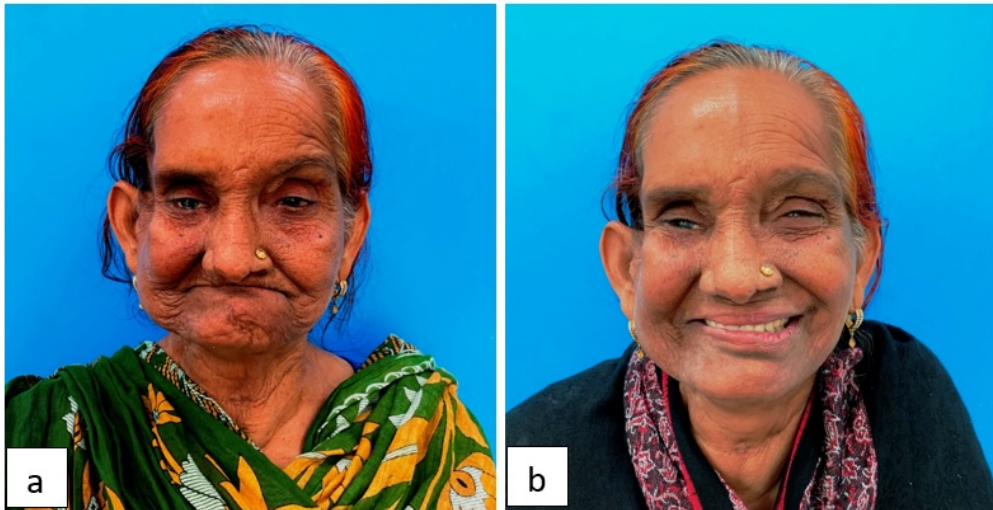**Fig. 12:** Pick up of metal housing



**Fig. 11:** Implants with ball attachments at B & D position



**Fig. 13:** Finished prosthesis - Maxillary hollow bulb obturator & implant retained overdenture



**Fig. 14:** Pre & post operative results

### 3.6. Insertion

After finishing and polishing the fabricated prosthesis [Figure 13] was inserted in-situ and post insertion instructions were given to the patient. The pre and post operative photograph is shown [Figure 14 a,b]. Recall appointments for follow up were performed. The patient reported of improved retention and functional efficiency of the prosthesis with an evident psychological boost.

### 4. Discussion

Numerous techniques are available in the literature for fabrication of closed or open type of hollow bulb obturator.<sup>5,6</sup> Worley and Kniejski described a method for the fabrication of a closed hollow obturator while maintaining uniform thickness of the surrounding wall around the hollow portion.<sup>7</sup> The use of asbestos used in their technique has made the use it unacceptable to practice considering health hazard it can cause to the operator. This technique, which is a modification of existing techniques, is better than other techniques as it provides a uniform thickness of wall around the hollow space and gives a single unit prosthesis in a single step.

The monoplane occlusal scheme with balancing ramps is advocated for patients with resorbed or knife edge ridges, posterior displaceable tissues, mutilated tortuous ridges and poor neuromuscular coordination.<sup>8</sup> The findings of resorbed ridge and poor neuromuscular coordination were observed in this case for which this occlusal scheme was followed which added to the stability of the weaker maxillary arch.

The implant retained mandibular over denture gave better results in terms of patient's satisfaction and functional performance in terms of better prosthetic stability and prevented rotational forces of the components.<sup>9</sup> Hence, making use of two implants in the anterior region as a

logical treatment solution.

### 5. Conclusion

The hollow bulb obturator and implant retained overdenture rehabilitated the patient with improved masticatory efficiency and phonetics by adding resonance to the voice. The reduced weight of the prosthesis significantly improved the patient's comfort. Simplicity of fabrication and uniform wall thickness around the hollow space are the basic advantages of this technique. Patient's functional and esthetic requirements were met which improved the morale of the patient.

### 6. Source of Funding

None.

### 7. Conflict of Interest

None.

### References

1. Wu Y, Schaaf NG. Comparison of weight reduction in different designs of solid and hollow obturator prostheses. *J Prosthetic Dent.* 1989;62(2):214–7.
2. McAndrew KS, Rothenberger S, Minsley GE, Judson C, Hickey scientific writing awards. An innovative investment method for the fabrication of a closed hollow obturator prosthesis. *J Prosthet Dent.* 1997;80:129–32.
3. Phankosol P, Martin JW. Hollow obturator with removable lid. *J Prosthetic Dent.* 1985;54(1):98–100.
4. McCord JF, Tyson KW. A conservative prosthodontic option for the treatment of edentulous patients with atrophic (flat) mandibular ridges. *Br Dent J.* 1997;182(12):469–72.
5. Taicher S, Rosen AG, Arbree NS, Bergen SF, Levy M, Lepley JB. A technique for fabrication of polydimethylsiloxane-acrylic resin obturators. *J Prosthetic Dent.* 1983;50(1):65–8.

6. Blair FM, Hunter NR. The hollow box maxillary obturator. *Br Dent J.* 1998;184(10):484–7.
7. Worley JL, Kniejski ME. A method for controlling the thickness of hollow obturator prostheses. *J Prosthetic Dent.* 1983;50(2):227–9.
8. Ortman HR. Complete Denture Occlusion. In: Winkler S, editor. *Essentials of Complete Denture Prosthodontics.* India: A.I.T.B.S. Publishers; 2009. p. 217–49.
9. Preiskel HW. Precision attachments in prosthodontics: The applications of intracoronal and extracoronal attachments. Quintessence Pub. Co; 1984.

**Tanuj Mendiratta** PG Resident

**Anup Gopi** Senior Specialist

**Rajesh Kumar Yadav** HOD

### Author biography

**Harmanpreet Atwal** Post Graduate

**Cite this article:** Atwal H, Mendiratta T, Gopi A, Yadav RK. Hollow bulb obturator and implant retained mandibular overdenture for a compromised completely edentulous patient with partial maxillectomy. *Int J Oral Health Dent* 2020;6(3):216–222.