



## Case Report

# Asymmetric expansion: An innovative approach

Parijat Chakraborty<sup>1,\*</sup>, Kamlesh Singh<sup>1</sup>, Pratik Chandra<sup>1</sup>, Ashish Chauhan<sup>1</sup>

<sup>1</sup>Dept. of Orthodontics and Dentofacial Orthopaedics, Saraswati Dental College, Lucknow, Uttar Pradesh, India



### ARTICLE INFO

#### Article history:

Received 17-05-2020

Accepted 20-05-2020

Available online 21-07-2020

#### Keywords:

Maxillary expansion

Asymmetric

Jackscrew

### ABSTRACT

Practitioners select expansion treatment appliances based on their personal experiences and on the patient's age and malocclusion. Many attempts have been made to produce greater expansion in the maxillary canine regions. Conventional devices for rapid maxillary expansion (RME) are limited to one direction, along the axis of the expansion screw, and thus cannot provide differential expansion. In this case report, we aimed to expand the maxillary arch asymmetrically according to the requirement of the case.

© 2020 Published by Innovative Publication. This is an open access article under the CC BY-NC license (<https://creativecommons.org/licenses/by-nc/4.0/>)

## 1. Introduction

Maxillary expansion treatments have been used for more than a century to correct maxillary transverse deficiency. The earliest common cited report is that of E.C. Angell published in Dental Cosmos in 1860.<sup>1</sup> Practitioners select treatment appliances based on their personal experiences and on the patient's age and malocclusion.<sup>2</sup> During treatment, transverse forces tip the buccal segments laterally and with proper appliance design, 3rd-order moments will induce bodily translation.<sup>3</sup> Many attempts have been made to produce greater expansion in the maxillary canine regions of CLP patients by changing the design of conventional expanders. Three expansion treatment modalities are used today: rapid maxillary expansion (RME), slow maxillary expansion (SME) and surgically assisted maxillary expansion.<sup>1</sup> Traditionally, adult patients with mild to moderate transverse discrepancies are treated with a combination of slow maxillary expansion with palatal appliances and expanded archwires.<sup>4</sup> The primary goal for this innovation was to expand the maxillary arch asymmetrically according to the requirement and together with fixed appliance.

## 2. Fabrication and Activation

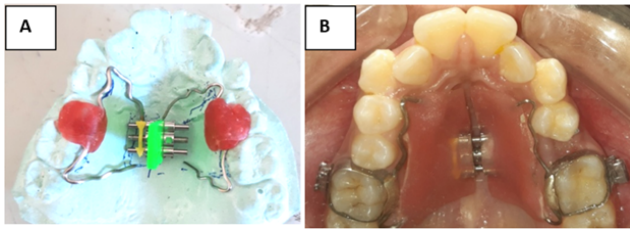
On the working model prepared using Dental Stone, a conventional jackscrew was placed on the mid palatal suture in premolar and molar region. The arrow for activation was placed anteroposteriorly for easy compliance of the individual. Appropriate sized bands were placed on the 1<sup>st</sup> molars. A wire work on each side contouring onto the cervical aspect of the 1<sup>st</sup> molar, 2<sup>nd</sup> premolar and 1<sup>st</sup> premolar was made using stainless steel round wires. The gauge of wire used on both side were different with heavier wire (18 gauge) on the side requiring more expansion and lighter wire (22 gauge) on the other. Both the wire component and the jackscrew were connected using self cure acrylic and the whole appliance was soldered with the molar bands for its stability in the oral cavity (Figure 1).

The appliance fabricated was then cemented in the patient's maxillary arch along with bonding rest of the maxillary arch dentition using 0.022" slot MBT bracket system. Patient was asked to activate the screw at the rate of 1 turn/day for two weeks. After a follow up and religation of the archwire, the patient was further instructed to activate the same for another 2 weeks to get the desired amount of expansion.

On evaluating the pre and stage models it was found that a total of 6mm expansion was achieved in both premolar and

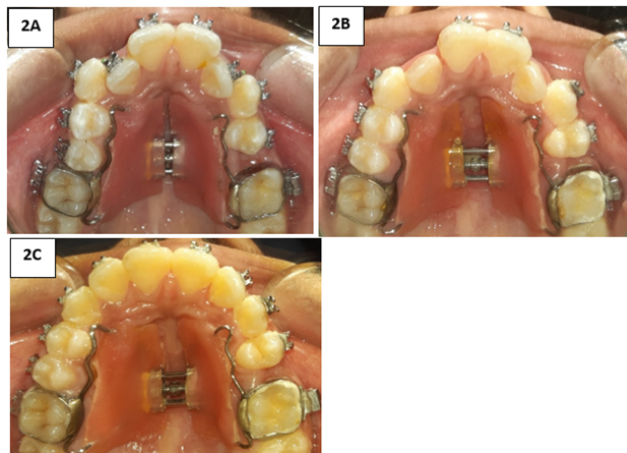
\* Corresponding author.

E-mail address: [parijatchak@gmail.com](mailto:parijatchak@gmail.com) (P. Chakraborty).



**Fig. 1:** **A:** Appliance design on working model consisting of a jackscrew and two wire components; **B:** Appliance seated in the arch with the help of molar bands

molar regions, with 4mm on the right side and 2mm on the left. Crowding was fully relieved and a space of 2mm was available in between the 1<sup>st</sup> premolar and 1<sup>st</sup> molar of the 2<sup>nd</sup> quadrant which was further consolidated by protraction of the molar keeping in mind the midline (Figure 2).



**Fig. 2:** **A:** Appliance cemented along with bonding at the start of the treatment; **B:** Appliance after two weeks of expansion; **C:** Appliance after one month of expansion

### 3. Advantages

1. The use of jackscrew for expansion was cost effective and fulfilled the intent of slow expansion.

2. Different gauge wires produced different amount of forces on the dentition causing asymmetric amount of expansion as required for the individual.
3. Subsequent bonding of the arch also helped in simultaneous leveling and aligning reducing the treatment time in total.

### 4. Source of Funding

None.

### 5. Conflict of Interest

None.

### References

1. Timms DJ. The dawn of rapid maxillary expansion. *Angle Orthod.* 1999;69(3):247-50.
2. Bell RA. A review of maxillary expansion in relation to rate of expansion and patient's age. *Am J Orthod.* 1982;81(1):32-7.
3. Starnbach H, Bayne D, Cleall J, Subtelny JD. Facioskeletal and dental changes resulting from rapid maxillary expansion. *Angle Orthod.* 1966;36(2):152-4.
4. de Araújo Gurgel J, Pinzan-Vercelino CRM, Leon-Salazar V. Maxillary and mandibular dentoalveolar expansion with an auxiliary beta-titanium arch. *Am J Orthod Dentofac Orthop.* 2017;152(4):543-52.

### Author biography

**Parijat Chakraborty** Post Graduate Student

**Kamlesh Singh** Professor

**Pratik Chandra** Reader

**Ashish Chauhan** Senior Lecturer

**Cite this article:** Chakraborty P, Singh K, Chandra P, Chauhan A. Asymmetric expansion: An innovative approach. *Int J Oral Health Dent* 2020;6(2):141-142.