



Case Report

Primary umbilical endometriosis (Villars Nodule)- A rare case with aesthetic treatment

Anjali Saple^{1,*}, Archana Mahato², Sumitra Gantayet¹

¹Dept. of Plastic Surgery, Seven Hills Hospital, Vishakapatnam, Andhra Pradesh, India

²Dept. of Obstetrics and Gynaecology, Seven Hills Hospital, Visakhapatnam, Andhra Pradesh, India



ARTICLE INFO

Article history:

Received 30-04-2020

Accepted 11-05-2020

Available online 12-09-2020

Keywords:

Endometriosis

Primary

Umbilicoplasty

ABSTRACT

Primary umbilical endometriosis (PUE) is a rare condition seen in .5-1% of patients of endometriosis. This condition is a diagnostic dilemma. Once diagnosed, the definitive treatment is surgical excision. The umbilicus is an important aesthetic landmark, and in this condition, where the final goal is not only to cure, but to give the best result, umbilicoplasty plays an important role. Here we describe a patient with PUE, diagnosed and treated with wide excision and umbilicoplasty.

© 2020 Published by Innovative Publication. This is an open access article under the CC BY-NC license (<https://creativecommons.org/licenses/by-nc/4.0/>)

1. Introduction

Endometriosis is the presence of functional endometrial and stromal tissue in extra uterine sites. When it presents in cutaneous tissues it is called cutaneous endometriosis. Cutaneous endometriosis can be primary or secondary depending on its aetiology. The condition is called Primary cutaneous endometriosis when there is no prior history of pelvic endometriosis or abdominal surgeries. The secondary type of cutaneous endometriosis is seen in patients who have undergone previous abdominal or pelvic surgeries, and have evidence of pelvic endometriosis. This is usually seen in the vicinity of the surgical scar. Umbilical endometriosis is a rare occurrence, seen in 0.5-1% of the cases of endometriosis, of this the primary type is rarer. Primary umbilical endometriosis (PUE) was described in 1886 by Villars and hence is also called Villars nodule.¹

PUE can be treated medically or surgically. Surgical excision of the lesion is curative but it entails removal of the umbilicus.² The umbilicus whilst of minimal function, is an important aesthetic landmark of the abdomen, the loss of which can be distressing for the patient. Hence, the

best outcome can be obtained by combining an umbilical reconstruction at the same time.

Here we present a case of a 37 years old female, who presented to us with PUE which was managed with wide excision and umbilicoplasty.

2. Case

A 37 year old nulliparous female, presented with history of a blackish-blue coloured nodule of size 2*2 cm over the umbilicus which was present since 4 years (Figure 1A). She gave history of cyclical bleeding from the nodule. She had regular 3*30 days cycles, with no history of dysmenorrhea. There was also no history of hormonal treatment, or any previous surgeries. A per vaginal and per speculum examination done on her was found to be normal. Ultrasound of the abdomen and pelvis was normal, with no signs of pelvic endometriosis. A provisional diagnosis of PUE was made, and she was planned for wide local excision of the lesion and umbilical reconstruction.

Under Spinal anaesthesia the whole of the nodule was excised along with the umbilical stalk ensuring an adequate margin of 1 cm all around. At the base of the defect the breach in the peritoneum was closed and the rectus

* Corresponding author.

E-mail address: sapleanjali@gmail.com (A. Saple).

sheath was repaired. (Figure 1B) This left a defect of 3*3 cm in the skin and soft tissue, with total loss of the umbilicus. A paraumbilical perforator was identified adjacent to the defect, using a hand held doppler. A circular skin flap of 1.5 cm was islanded based on this perforator and advanced into the defect to fashion the neoumbilicus (Figure 1C). The neoumbilicus was anchored to the rectus fascia, taking care to avoid damage to the perforator present at the base of the flap. The donor site was closed primarily by advancing the skin flaps on both sides of the neoumbilicus. (Figure 1D). The histopathology report confirmed the diagnosis of cutaneous endometriosis.

The patient was discharged on the following day. At two months she had complete relief from her symptoms. At the time of last follow up, at 10 months post-surgery, there were no signs of any recurrence of the disease. The neoumbilicus had a well-defined shape and position and was aesthetically acceptable to the patient (Figure 2).

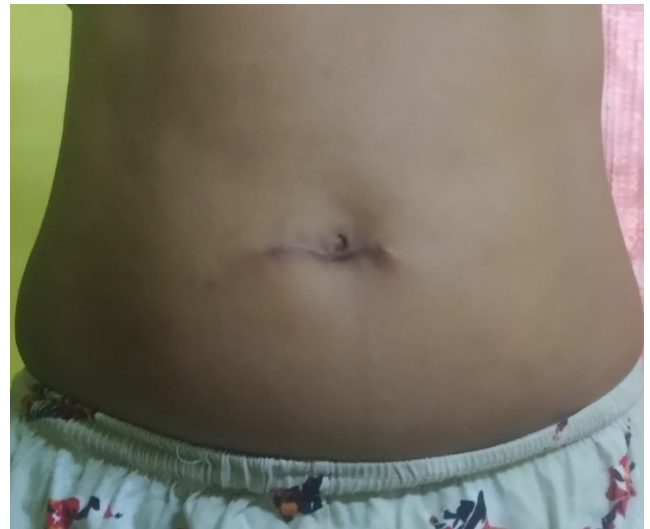

Fig. 2: At 10 months follow up, with well defined umbilicus

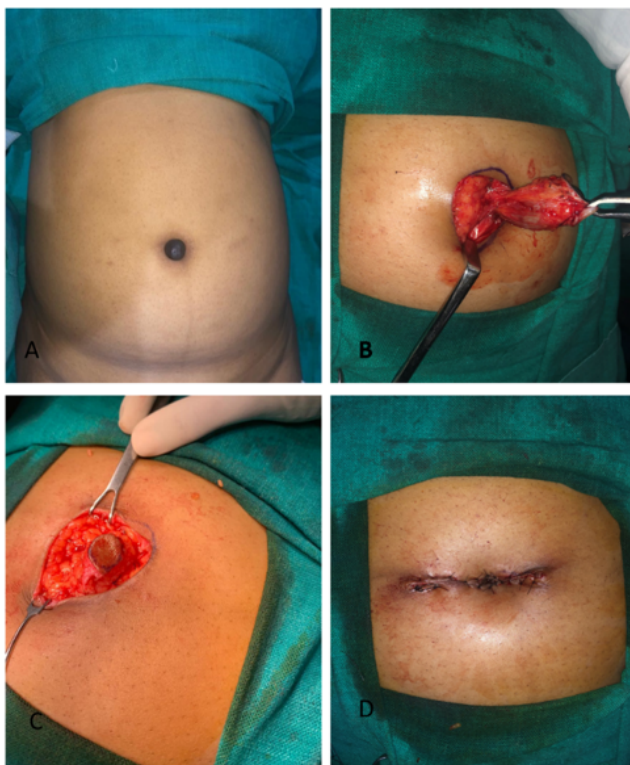


Fig. 1: (A): Blackish blue nodule, of primary umbilical endometriosis; (B): Wide excision of the nodule with excision of the umbilical stalk; (C): Circular skin island flap based on the paraumbilical perforator dissected and mobilised to from neoumbilicus; (D): Inset of the neoumbilicus, and closure of the defect using adjacent skin flaps

3. Discussion

Endometriosis is the presence of functional endometrial and stromal tissue outside the uterus. When present in

a cutaneous site it is called cutaneous endometriosis. It can be primary or secondary, depending on the cause of endometriosis. The secondary type or scar endometriosis, is the more common of the two and is seen in patients who have undergone previous abdominal or laparoscopic surgeries. PUE is a rare disorder and is seen in only 0.5-1% of the cases of endometriosis. PUE was described by Villar and is also known as Villar's nodule.¹

The theories proposed explain UE are, embryonal rest theory of Wolffian or Mullerian ducts, transplantation theory in which ectopic endometrium harbours from retrograde menstruation, coelomic metaplasia theory or lymphatic and haematogenous spread. The lymphatic and haematogenous spread are the most accepted theories for PUE but the exact aetiology still remains unknown.^{3,4}

It usually presents in the reproductive age group, with a nodule in the umbilical region. It may or may not be associated with a history of cyclical bleeding, in the absence of which there may be a diagnostic dilemma.⁵ Evaluation should be done to rule out other differential diagnoses like scar, keloid, secondary endometriosis, pyogenic granuloma, melanocytic nevus, umbilical or paraumbilical hernia and Sister Mary Joseph nodule. Diagnostic tools like Ultrasound/CT/MRI of the abdomen can help to investigate the relation of the lesion with the surrounding tissues and also to look for intraabdominal connections. Diagnostic laparoscopy should be restricted only to patients whose symptoms suggest pelvic endometriosis.⁵

As the presentation is very rare, there is no definitive treatment plan available for this condition. Medical management with hormonal therapy, using oestrogen, progesterone and danazol has shown recurrence after the stoppage of treatment which eventually needed surgical treatment. Hence the treatment of choice is surgical, with en

bloc excision of the nodule with adequate margins to prevent a recurrence. However, if the patient does not consent to complete removal of the umbilicus, local excision of the lesion preserving the umbilicus may be done, accepting a higher risk of recurrence with this approach. Complete excision of the lesion till the level of the fascia or till the peritoneum is shown to be the most definitive. The fascia must be repaired well to prevent risk of later herniation.¹ This approach causes loss of umbilicus which is the central focus of the abdomen and an important aesthetic component of the body. The absence of the umbilicus may be a cause of psychological distress, hence the best result can be obtained by ensuring a wide excision and recreation of a neoumbilicus to give a youthful appearance to the abdomen. The correct placement of the neoumbilicus is important. The landmark is the intersection of a horizontal line joining both the ASIS with a vertical line drawn through the midline of the abdomen. It should be a vertical oval, with a superior hood and a mild depression at its inferior end. There are multiple methods of neoumbilicoplasty like the purse string method, the four flap method, the double VY procedure and the cone flap.⁶⁻⁹ The perforator flap method used in this case, helps to create an aesthetically pleasing and well-defined umbilicus, without the risk of stenosis. The advancement of the skin flaps can be used to cover the remaining defect, even if it is large.^{8,9}

4. Conclusion

PUE, poses both a diagnostic and treatment dilemma. Once the diagnosis is confirmed, surgical excision with reconstruction of the neoumbilicus can provide the patient with the best functional and aesthetic outcome. Neoumbilicoplasty does not add too much to the operating time. Using fundamental plastic surgical principles both excision and creation of neoumbilicus can be done in the same sitting.

5. Source of Funding

None.

6. Conflict of Interest

None.

References

1. Boesgaard-Kjer D, Boesgaard-Kjer D, Kjer JJ. Primary umbilical endometriosis (PUE). *Eur J Obstet Gynecol Reprod Biol.* 2017;209:44-5.
2. Loh SH, Lew BL, Sim WY. Primary Cutaneous Endometriosis of Umbilicus. *Ann Dermatol.* 2017;29:621-5.
3. Latcher JW. Endometriosis of the umbilicus. *Am J Obstet Gynecol.* 1953;66(1):161-8.
4. Bagade PV, Guirguis MM. Menstruating from the umbilicus as a rare case of primary umbilical endometriosis: a case report. *J Med Case Rep.* 2009;3(1):9326.
5. Fancellu A, Pinna A, Manca A, Capobianco G, Porcu A. Primary umbilical endometriosis. Case report and discussion on management options. *Int J Surg Case Rep.* 2013;4:1145-8.
6. Pfulg M, de Sijpe KV, Blondeel PH. A simple new technique for neoumbilicoplasty. *Br J Plast Surg.* 2005;58:688-91.
7. Takasu H, Watanabe Y. Umbilicoplasty with 3 triangular skin flaps and excised diamond-shaped skin flap. *J Pediatr Surg.* 2010;45:2041-4.
8. Malebranche AD, Bush K. Umbilical Endometriosis: A Rare Diagnosis in Plastic and Reconstructive Surgery. *Can J Plast Surg.* 2010;18(4):147-8.
9. Costa-Silva M, Ferreira B, Brinca A, Vieira R. Umbilicus reconstruction after melanoma excision. *J Cutan Aesthet Surg.* 2017;10:183.

Author biography

Anjali Saple Consultant Plastic Cosmetic and Microvascular Surgeon

Archana Mahato Consultant Gynaecologist and Laparoscopic Surgeon

Sumitra Gantayet Registrar

Cite this article: Saple A, Mahato A, Gantayet S. Primary umbilical endometriosis (Villars Nodule)- A rare case with aesthetic treatment. *Indian J Obstet Gynecol Res* 2020;7(3):442-444.