



## Case Report

# A rare case of heterotopic pregnancy managed by laparoscopic salpingectomy

Jaydeep J Bhatu<sup>1,\*</sup>, Shree A Jani<sup>1</sup>

<sup>1</sup>Dept. of Obstetrics and Gynaecology, GMERS Medical College and Hospital, Ahmedabad, Gujarat, India



### ARTICLE INFO

#### Article history:

Received 19-03-2020

Accepted 30-03-2020

Available online 15-06-2020

#### Keywords:

Heterotopic ectopic pregnancy

Laparoscopy

Chorionic villi

### ABSTRACT

Heterotopic pregnancy is the existence of 2 or more simultaneous pregnancies with separate implantation sites, one of which is tubes or ovaries or other ectopic site. The estimated incidence in the general population is estimated at 1:35,000 (for a naturally conceived pregnancy). With increasing trend in assisted reproductive technique, the frequency of heterotopic pregnancies was increased to be between 1:100 to 1:7,000. A 36 yrs third gravida (P1, L1, A1) presented with 2 month amenorrhoea. In Doppler usg there was evidence of irregular solid component at periphery with echogenic tissue around showing ring vascularity and burning ring fire sign present. There is evidence of mild free fluid collection in the pouch of Douglas pre operative and post operative injection 17-oh progesterone acetate (proleutone) used and post operative tidilan injection. Left sided laparoscopic salpingectomy was done. The material was collect in endobag and afterward sent it for histopathological examination which confirms trophoblastic tissue and presence of ectopic pregnancy. There is no proven role of medical management in this because of high Bhcg titer which helps to continue it afterwards. Like other cases if there was no facility for laparoscopy, laparotomy for salpingectomy is another option. Diagnosis of heterotopic rare and challenging but proper ultrasonography skills and broad mind set helps in diagnosis.

© 2020 Published by Innovative Publication. This is an open access article under the CC BY-NC license (<https://creativecommons.org/licenses/by-nc/4.0/>)

## 1. Introduction

Bleeding through vagina in the early pregnancy is a common obstetric entity. Four major causes of pathological bleeding in early pregnancy are miscarriage, ectopic pregnancy, implantation bleeding of pregnancy and cervical carcinoma and ectopy.<sup>1</sup> Heterotopic pregnancy is the existence of 2 or more simultaneous pregnancies with separate implantation sites, one of which is tubes or ovaries or other ectopic site. The estimated incidence in the general population is estimated at 1:35,000 (for a naturally conceived pregnancy). With increasing trend in assisted reproductive technique, the frequency of heterotopic pregnancies was increased to be between 1:100 to 1:7,000.

For patients who have been treated with ovulation-induction an incidence of 33/10,000 has been noted, while

it was extremely rare among women who conceive naturally conception. This raised frequency has been attributed to several factors including higher incidence of pelvic inflammatory disease and the extended use of assisted reproductive technologies (ARTs). The mainstay of treating heterotopic pregnancy remains surgery while laparoscopic salpingectomy used these days.<sup>2</sup>

Every gynaecologist treating a woman of reproductive age group should consider the suspicion of heterotopic pregnancy. Even in the absence of any known risk factor.

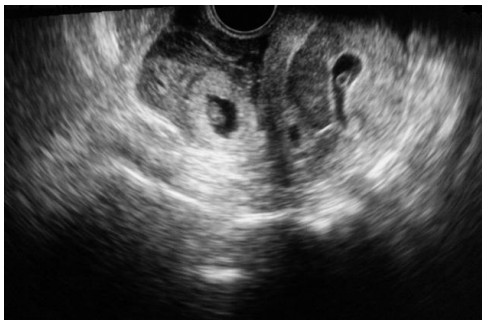## 2. Case Report

A 36 yrs third gravida (P1, L1, A1) presented with 2 month amenorrhoea of one and half months and an early USG showing a single live intrauterine gestation of 6.5 wks. It also showed a mixed echogenic mass lesion in left adnexal region measuring 6.4×4.0 cm. In Doppler usg there was evidence of irregular solid component at periphery

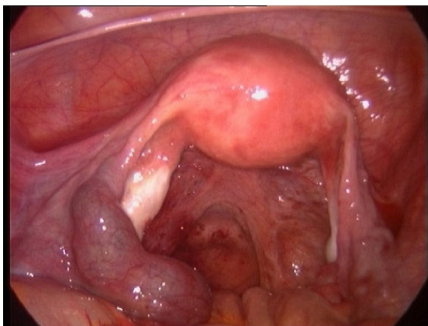
\* Corresponding author.

E-mail address: [bhatujaydeep@gmail.com](mailto:bhatujaydeep@gmail.com) (J. J. Bhatu).

with echogenic tissue around showing ring vascularity and burning ring fire sign present. There is evidence of mild free fluid collection in the pouch of Douglas. Seven years back one spontaneous vaginal history present. On examination, patient was haemodynamically stable, patient was posted for laparoscopy. pre operative and post operative injection 17 –oh progesterone acetate (proleutone) used and post operative tidilan injection also used, there is no proven evidence and guidelines about it but its use was only prophylactically Intraoperative findings there was signs of endometriosis and PID changes and left sided unruptured ectopic. Left sided laparoscopic salpingectomy was done. The material was collect in endobag and afterward sent it for histopathological examination which confirms trophoblastic tissue and presence of ectopic pregnancy.



**Fig. 1:** Shows heterotopic and uterine pregnancy on trans vaginal sonography



**Fig. 2:** Shows laparoscopic panoramic view for left sided unruptured heterotopic pregnancy

### 3. Discussion

Heterotopic pregnancies presents as an intrauterine pregnancy with other simultaneous ectopic pregnancy like tubal, abdominal, cornual, cervical or ovarian pregnancy. A previous review showed that most of extra uterine pregnancies were located in the fallopian tube (72.5%). Clinicians should maintain a high index of suspicion in all patients presenting with amenorrhoea, abdominal pain, adnexal mass, peritoneal irritation, and enlarged uterus, even if an IUP has been confirmed.

The recent mainly two important things noted for heterotopic pregnancy that increasing suspicious mind set in USG and medical management with methotrexate and kcl injection reduction as medical management. Medical knowledge and technology may be improving, but ultimately, even in the presence of a known intrauterine pregnancy, the simple dictum ‘think ectopic’ must not be forgotten.<sup>3</sup> Presence of intra uterine pregnancy set our mindset apart and we don’t even suspect heterotopic pregnancy also there is no proven role of medical management in this because of high Bhcg titer which helps to continue it afterwards. Like other cases if there was no facility for laparoscopy, laparotomy for salpingectomy is another option. pre operative and post operative progesterone used for normal uterine pregnancy protection, but there is no proven evidences about it.

### 4. Conclusion

The incident of ectopic as well as heterotopic pregnancy increase because of increasing trends in artificial reproductive technology. Diagnosis of heterotopic rare and challenging but proper ultrasonography skills and broad mind set helps in diagnosis.

### 5. Acknowledgements

We greatly thankful to Dr. Ajesh Desai Sir, who was also operated the patient and Dr. Jaya Varu for scripting and language correction.

### 6. Source of Funding

None.

### 7. Conflict of Interest

None.

### References

1. Bhatu JJ, Prajapati DS. A study of fetomaternal outcome in bleeding per vaginum in first trimester of pregnancy. *Int J Reprod, Contracept, Obstet Gynecol.* 2020;9(3):1192.
2. Barrenetxea G, Barinaga-Rementería L, de Larruzea AL, Agirregoikoa JA, Mandiola M, Carbonero K. Heterotopic pregnancy: two cases and a comparative review. *Fertil Steril.* 2007;87:417–9.
3. Talbot K, Simpson R, Price N, Jackson SR. Heterotopic pregnancy. *J Obstet Gynaecol.* 2011;31(1):7–12.

### Author biography

**Jaydeep J Bhatu** 3rd Year Resident

**Shree A Jani** 2nd Year Resident

**Cite this article:** Bhatu JJ, Jani SA. A rare case of heterotopic pregnancy managed by laparoscopic salpingectomy. *Indian J Obstet Gynecol Res* 2020;7(2):252-253.