



## Review Article

# Replicas in forensic dentistry for human identification

Ravina Sorout<sup>1</sup>, Osheen Batra<sup>1</sup>, Latika Bachani Chopra<sup>1,\*</sup>

<sup>1</sup>Dept. of Oral Medicine and Radiology, SGT University, Gurugram, Haryana, India



### ARTICLE INFO

#### Article history:

Received 23-3-2021

Accepted 28-03-2021

Available online 10-04-2021

#### Keywords:

Forensic identification

DNA

Forensic odontology

Ameloglyphics

Rugoscopy

Cheiloscopy

Saliva

Bite marks

### ABSTRACT

Forensic odontology is a branch of forensic sciences that uses the skill of the dentist in personal identification during mass calamities, sexual assault and child abuse to name a few. This branch has been growing potentially in its ability to bring justice to the concerned when dental remains are the only available evidence. It is gaining importance in the judiciary and hence in depth knowledge in this field seems irreplaceable.

© This is an open access article distributed under the terms of the Creative Commons Attribution License (<https://creativecommons.org/licenses/by/4.0/>) which permits unrestricted use, distribution, and reproduction in any medium, provided the original author and source are credited.

## 1. Introduction

Just like fingerprints or snowflakes, there are no two teeth that are alike. Not even identical twins have the same teeth. As teeth are specific to every individual, they are often used as an identifier. Also, they are a potential source of DNA since they can stand up against conditions like humidity, temperature, and microbial action.

"What a nightmare! .....bodies as negroes, heads carbonized; shrunken and reduced to nothing, but only the teeth remained....." DR Oscar Ameodo (Father of Forensic Odontology).

Forensic derived from Latin word meaning 'to the forum' and Odontology means the study of teeth. Forensic dentistry involves the processing, review, evaluation and presentation of dental evidence with the purpose of contributing scientific and objective data in legal processes. Dental identification can have three different applications:

1. Comparative identification, in which the post-mortem dental records are compared with the ante-mortem records of an individual in order to establish whether both records correspond to the same person.
2. The obtainment of dental information to narrow the search for an individual when the ante-mortem records are not available and there are no possible data referred to the entity of the subject.
3. Identification of victims following mass disasters or catastrophes.<sup>1</sup>

Keiser-Neilson had defined forensic dentistry as "that branch of forensic dentistry that in the interest of justice deals with the proper handling and examination of dental evidence and the proper evaluation and presentation of dental findings".<sup>2</sup>

With the passage of time, the role of forensic odontology has increased, as many a times teeth and dental restorations are the only means of identification. Forensic odontology has played a key role in identification of affected in mass disasters, in crime investigations, in ethnic studies, and in identification of decomposed and disfigured

\* Corresponding author.

E-mail address: [latikabachani@gmail.com](mailto:latikabachani@gmail.com) (L. B. Chopra).

bodies like that of drowned persons, fire victims, and victims of motor vehicle accidents. The various methods employed in forensic odontology include tooth prints, rugoscopy, cheiloscopy, radiographs, photographic study, and molecular methods. Investigative methods applied are reasonably reliable, yet the shortcomings must be accounted to make it a more meaningful and relevant procedure.<sup>3</sup>

This article will give you a collective review on the evolution, various methods and applications of forensic odontology, which plays a major role in keeping the dental records accurately, and providing required information, which will help the legal authorities to recognize negligence, malpractice, fraud or abuse and identification of unknown individuals.

## 2. Purpose of Forensic Odontology

Forensic odontology plays a major role in both death investigations as well as in the evaluation of victims of sexual assault and child abuse. The dental practitioner can help by providing accurate dental records and all the necessary information needed to identify individuals. For e.g.- identification of species, determination of race, gender, age, DNA analysis, rugoscopy, cheiloscopy, bitemarks, and many more.

### 2.1. Species identification

Is the tooth found in the crime scene of human origin? Based on anatomy and morphology of the tooth it can be identified whether it is of human or not. It is possible to determine even by dental tissue because dentinal fluid contains special information that can be compared and analyzed using counter current electrophoresis with artificial antisera.

### 2.2. Race determination

Human species are categorized into three races- Caucasoid, mongoloid, negroid. Dental characteristics such as shovelings, taurodontism, carebellies cusp hypocone, protostylid, peg shape incisor, etc are used to determine ancestry. Dental restoration also helps in finding the ethnicity of an individual. The type of dental treatment recommends the financial status of a person. Teeth can provide significant evidence regarding the habits and occupation of the individual.

### 2.3. Gender determination

Sex determination plays a major part in the recognizable proof of unknown persons in a natural calamity, chemical, or nuclear bomb explosion. Dental indices are used to show sexual dimorphism. Gender can also be determined by the presence of sex chromatin or Barr bodies in the pulp.

### 2.4. Age estimation

The requirement for age estimation has increased because of growth in number of unidentified cadavers and human remains and cases for living people with no substantial confirmation of date of birth. The number and sequence of teeth erupted in the jaw help in the determination of age. The radiographical method elaborates on various stages of mineralization and helps in giving an accurate estimation of age.

### 2.5. Bitemark

ABFO defines bitemarks as pattern left in an object or tissue by the dental structure of an animal or human. Bitemark inflicted by teeth considered to be highly individualistic to a person and has been used since Roman times. Teeth are used as a weapon by an aggressor and as self-defense by the victim. Peculiar characteristics like missing teeth, malformed teeth, fractured teeth, crowding, diastema are helpful in the comparison process.

### 2.6. Comparative dental identification

Teeth play a critical role when the recognizable proof of remains of a perished individual is skeletonized, deteriorated, burned, or dismembered and cannot be distinguished by visual or unique strategies. The core of the identification procedure is comparing the post mortem remains with ante-mortem record which include notes, radiographs, study cast, etc. In Disaster Victim Identification the dental evidence collected is compared to the ante-mortem records available to the dentist for identification of a deceased person.<sup>4</sup>

### 2.7. DNA analysis

Teeth are fabulous source of genomic DNA due to its resistant nature.

DNA is found in the vascular pulp, accessory canal, odontoblastic process and cellular cementum. Even the root canal treated teeth provide sufficient material for PCR analysis that produces DNA profile which is further compared with ante-mortem samples or paternal DNA.

Teeth and bones are frequently the only sources of DNA available for identification of degraded human remains. The unique location of teeth in the jawbone and their composition provides additional protection to DNA compared to bones making them a preferred source of DNA in many cases.<sup>5</sup>

According to American board of forensic odontology, dental identification is divided into four types :

1. Positive identification: The post-mortem and ante-mortem data match to prove that it is from same individual;

2. Possible identification: The ante-mortem and postmortem data have few consistent features, but because of quality of the records it is difficult to establish the identity;
3. Insufficient evidence: The data is not enough to form the conclusion;
4. Exclusion: The ante-mortem and post mortem data are clearly inconsistent.

In majority of the cases of dental identification, fingerprint and DNA are most commonly used and they often complement each other.<sup>2</sup>

### 3. Teeth

Teeth can withstand high temperatures and are identifiable even when the rest of the body has undergone decomposition. Canines are considered to be the most stable teeth of all the teeth in the human dentition. The labio-lingual thickness of crown and root and the strong anchorage in the alveolar bone along with the self-cleansing quality, helps to preserve these teeth throughout life. Canines seem to be unaffected by extreme catastrophic events like air crashes or hurricanes.

The age-related changes in the dentition are of three types: formative, degenerative and histological. Formative changes can be good predictors till the age 12. They include the completion of the crown, eruption of the crown into oral cavity and completion of the root. Degenerative changes include attrition, periodontosis, secondary dentin and cementum apposition (both seen microscopically), root resorption and transparency of the root seen in ground sections.

#### 3.1. Changes during development

##### 3.1.1. Formation of hard tissue

Tooth formation begins at a very early stage of life by six months. A specific age estimation method can be given by the sequence of formation and eruption of teeth. In this method, each tooth is recorded based on its developmental stage and scores are paralleled with values conforming to a particular age. For instance: a deciduous second incisor crown that is fully formed and is recovered adjacent to a deciduous second incisor crown that is only 3/4 complete suggest a single individual of age less than 6 months. But, if complete deciduous second molar is found in association with these 2 teeth, then it may represent that there are more than 1 individuals. This is used if dentition is completed and not applicable if there is missing teeth due to cases etc.

##### 3.1.2. Dental eruption

Human dentition has 2 eruption stages and their associated ages. To assess age of the unidentified individual, one can equate the postmortem radiographs of the individual to

the eruption standards which was produced by Schour and Massler.

#### 3.2. Eruption of third molar

Emergence of third molar inclines to be around 17-19 years. This tooth has great distinctions, may be completely developed but impacted or it may be completely absent. Only radiograph can be the precise document of this tooth.

#### 3.3. Dental measurement

This technique was a substitute to the qualitative evaluation where length of tooth was measured.

#### 3.4. Degenerative changes

Changes those occur once the teeth have erupted and begin to wear down. There is an instinctual connection between tooth wear and age, as in older age, teeth are more prone to tooth wear. One can use volume of pulp cavity because it's seen that the volume of pulp cavity lessens due to deposition of secondary dentine with aging.

Age estimation is the imperative part in forensic odontology because human dentition follows a consistent and predictable developmental sequence.

### 4. DNA in Forensic Odontology

During the last years, methods of DNA analysis are applied to the cases of forensics. Correspondingly, forensic dental record comparison has been used for identification of human bodies where devastation of bodily tissues or sustained exposure to the environment has made other means of identification unfeasible, i.e., after exposure of fire, mass disasters, etc. Dental DNA characterizes an outstanding source of genomic DNA. The curiosity in using dental tissues as a DNA-source of individual identification falls within the precise character of resistance of this tissue towards physical or chemical exterior bellicities. The identification of individuals is not the only use for DNA but also the technique has allowed criminal investigators to link victims to crime scenes once the body has been removed and cremated. Therefore, it is prudent for the forensic odontologist to become acquaint with the methods of DNA analysis. Its main benefit is the high number of copies per cell when the extracted DNA samples are too small or degraded, such as those obtained from skeletonized tissues, the likelihood of obtaining a DNA profile from mitochondrial DNA is higher than that with genomic DNA. Saliva is also a practical source of DNA for forensic purposes. Saliva is deposited frequently through bite marks in homicides, assaults, child abuse or other criminal cases. Saliva can also be salvaged from cigarette butts, skin, postage stamps, envelopes, clothes, etc. Double swab technique is used for effective collection of dried

saliva using a wet cotton swab followed by a dry cotton swab on surface with dried saliva.<sup>3,6</sup>

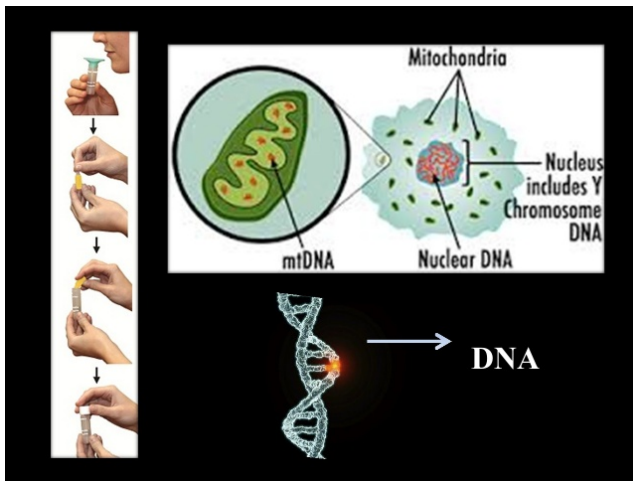


Fig. 1:

#### 4.1. Bitemarks in forensic dentistry

Bite marks are significant and provocative aspect of forensic odontology. Although there are various cases in which bite mark evidence has been grave to the conviction or clemency of criminal defendants, there is continuing dispute over its elucidation and analysis. A probable bite injury must be recognized early for bites on human skin as the transparency and shape of the mark may change in a comparatively short span of time in both alive and dead fatalities.

Bite marks may additionally be inflicted for the duration of violent squabbles in both offensive and protective combat. These marks can be used forensically for regulation enforcement tenacities. A chew mark might also be described as having passed off as an end result of both a physical alteration in a medium caused by using the contact of the teeth, or a consultant pattern left in an object or tissue via the dental constructions of an animal or human. A prototypical human chunk mark is described as being a circular or oval patterned injury consisting of two opposing symmetrical, U-shaped arches separated at their bases by using open spaces. Along the periphery of the arches can be a collection of abrasions, contusions and/or lacerations indicative of the size, shape, association and distribution of the contacting surfaces of the biting dentition.<sup>7,8</sup>

It is possible to perceive precise types of enamel through their class characteristics. For example, incisors produce rectangular accidents and canines produce triangular injuries. But it necessary to have person characteristics recorded in the bitemark to be capable to pick out positively the perpetrator. Use, misuse and abuse of the teeth result in unique features that are referred to as accidental or man or woman traits. Such traits include fractures,

rotations, attritional wear, congenital malformations, etc. When these are recorded in the injury it may additionally be possible to evaluate them to become aware of the specific enamel (person) that caused the injury. If these person characteristics are no longer existing in the teeth, or if they are not recorded nicely in the injury, the basic forensic magnitude of the bitemark is reduced.

Bite marks change over time on living as well as dead. If the mark is on living man or woman there will be changes in the tissue post injury, wherein bleeding, swelling and discoloration can be seen. If the bite is on a dead body, then images of marks are taken with standardized technique. If bite is recorded on objects such as apple, beer, chocolate etc. often yields extra facts due to the fact of lack of distortion of the object and we can achieve a good impression of biting edges. Taking swabs from this object is very imperative due to the fact it may reveal the blood group of the assailant and DNA evaluation is possible.<sup>2</sup>

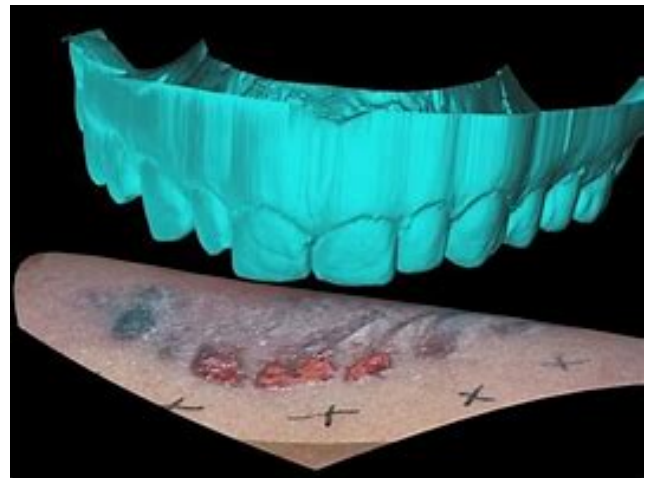
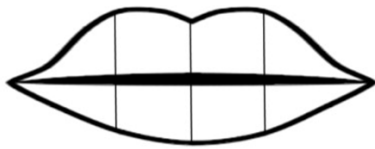


Fig. 2:

#### 5. Chéloscopy

Cheiloscopy derived from Greek word chelios-lips and skopein-see is the term given to the study of lip prints. Two Japanese scientists, Y. Tsuchihashi and T. Suzuki during 1968- 71, established that the association of traces on the purple part of the human lip is individual and unique for every human being. The grooves present on human lips (Sulci labiorum) are unique to every individual and can be used to determine identity. Lip prints are normal strains and fissures in the types of wrinkles and grooves present in the area of transition of human lip, between the inner labial mucosa and outer skin, examination of which is acknowledged as cheiloscopy. This is unique for individuals just as fingerprints. Cheiloscopic methods have an equal importance in relation to other types of forensic evidences for private identification and intercourse determination.

In criminal cases identification, the use of lip prints is restricted due to the fact that credibility of lip prints has no longer been firmly established in our courts. They are identifiable as early as 6th week of intrauterine life. They are permanent, unchangeable even after death and special to each individual except in monozygotic twins. The pattern alters very rarely in ones life time. As these do not change significantly post dead, cadaveric lip prints are hence considered satisfactory for identification purposes.<sup>9</sup>



SUZUKI & TSUCHIHASHI CLASSIFICATION:

TYPE I COMPLETE VERTICAL	TYPE I INCOMPLETE VERTICAL	TYPE II BRANCHED	TYPE III INTERSECTED	TYPE IV RECTILINEAR	TYPE V OTHER

Fig. 3:

## 6. Rugoscopy

Palatal rugae or plica palatinae transverse or rugae palatine, refer to the ridges on the anterior part of the palatal mucosa, each side of the median palatal raphae and behind the incisive papilla. Catastrophies such as plane crashes, fires and explosions can destroy the fingerprints but, fascinatingly, palatal rugae patterns are well-preserved. Once formed they only change their length due to normal growth, and remain in the same position during the course of an entire person's life.<sup>10</sup>

The palatal rugae appear in the third month of intrauterine life. They are asymmetrical and irregular elevations of the mucosa located in the anterior third of the palate. The study of palatal rugae patterns for human identification is described as rugoscopy and does play an important role in medico-legal identification because their individual morphological characteristics are steady throughout life. Even diseases, chemical attack, or trauma does not alter the form of the rugae. The rugae patterns have been studied for innumerable purposes, mainly in the fields of anthropology, comparative anatomy, genetics, forensic odontology, prosthodontics, and orthodontics.<sup>3,11</sup>

### 6.1. Examination of Tooth Prints (Amelogyphics)

Amelogyphics derived from the latin word (amelo-enamel; glyphics-carvings).<sup>12</sup>

Ameloblasts lay down the enamel rods in a rippling and interlacing path. This is mirrored on the outer surface of the enamel as patterns of the ends of a series of adjacent enamel rods. This study of the enamel rod patterns is termed as amelogyphics and can aid as an identification tool in

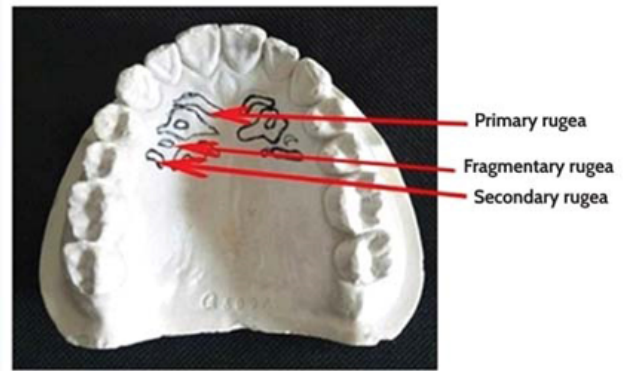


Fig. 4:

decomposed or burned out bodies as enamel is resistant to decomposition. This study requires ante-mortem records. Though enamel is the hardest mineralized substance in human body, the enamel floor is commonly subjected to micro and macrowearing. Fractured, decayed, attrited, abraded, and eroded tooth cannot be included in this method. Amelogyphics is nonetheless in its infancy and whether or not the tooth prints are the same at different depths of enamel has to be evaluated with further studies. Fusun et al. in 2005,<sup>13</sup> Ramenzoni et al. in 2006,<sup>14</sup> Manjunath et al. in 2008,<sup>12</sup> Gupta et al. in 2009,<sup>15</sup> Girish et al. in 2013,<sup>16</sup> Manjunath et al. in 2014,<sup>17</sup> and Singroha K et al in 2020<sup>18</sup> studied enamel rod print.

### 6.2. Practical application of amelogyphics in various fields

1. Individuals working in dangerous occupations such as: soldiers, divers, jet pilots.
2. People who live and travel to potentially unstable areas.

The uniqueness of the tooth prints could be developed as successful identification in forensic science as tooth prints are exclusive for each tooth of an individual. However, further studies need to be carried out to establish the usefulness of tooth prints as a considerable and reliable forensic identification contrivance in cases of burn and acid injuries.

## 7. Radiographs

Dental-based identification is considered less reliable as dental features do change over time compared to other biometric methods like fingerprints, iris scanning, etc. But in victims where there is complete decomposition, radiographs may be the only available biometric method. Various morphological and pathological alterations can be studied from the radiographs. In morphology based studies, root morphology comparatively aids better in identification

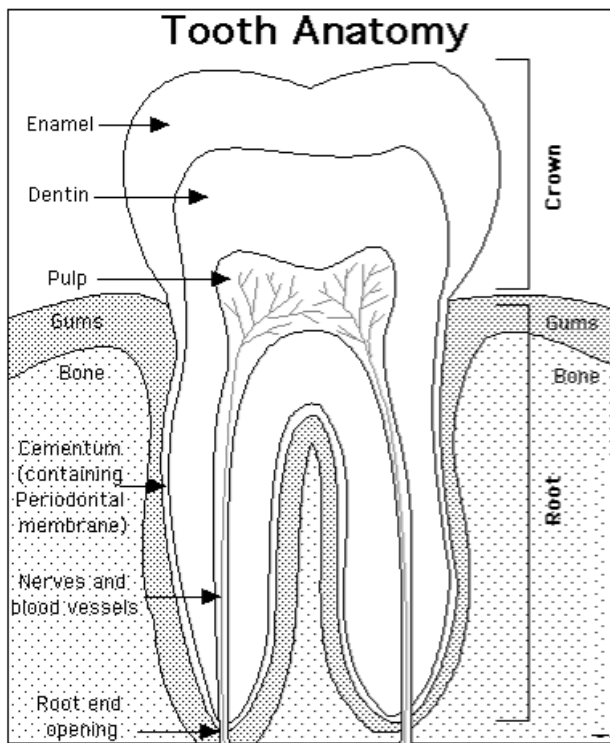


Fig. 5:

than crown morphology. Apart from routine findings, like decayed, missed, filled, and fractured teeth, different stages of wound recovery in extraction sockets, degree of root formation, and bone trabecular pattern in the jaws provide useful resource in identification.<sup>19</sup>

Radiography is usually used for the collection of forensic evidence and is specifically useful for confirming the identity of both living and deceased individuals. Also, used for identifying pre-existing skeletal trauma, assisting in the determination and/or confirmation of the cause of death, and locating hidden foreign bodies. Certain types of foreign bodies consist of bullet fragments, fragments of explosives and packages of illegal substances. This is why it is vital for radiographers to recognize the appropriate forensic imaging protocols for each situation, as well as the criminal and ethical problems involved.<sup>20</sup>

## 8. Conclusion

Forensic dentistry plays a pivotal role in the identification of those individuals who can't be identified visually or through different means. Better expertise and awareness of forensic odontology amongst dental practitioners would be prerequisite in the growing area of medicine. The uniqueness of our dental anatomy and the placement of custom restorations ensure accuracy when the methods are efficiently employed. Dental practitioners ought to be aware of the forensic application of dentistry. Dental records

could be very beneficial to legal authorities in identification processes. Therefore, all types of dental treatments should be recorded and stored properly.

## 9. Source of Funding

None.

## 10. Conflict of Interest

The authors declare that there is no conflict of interest.

## References

1. Ata-Ali J, Ata-Ali F. Forensic dentistry in human identification: A review of the literature. *J Clin Exp Dent*. 2014;6(2):62–7.
2. Disakar KP. Forensic odontology: The new dimension in dental analysis. *Int J Biomed Sci*. 2017;13(1):1–5.
3. Saxena S, Sharma P, Gupta N. Experimental studies of forensic odontology to aid in the identification process. *J Forensic Dent Sci*. 2010;2(2):69–76. doi:10.4103/0975-1475.81285.
4. Higgins D, Austin JJ. Teeth as a source of DNA for forensic identification of human remains: a review. *Sci Justice*. 2013;53(4):433–41.
5. Krishan K, Kanchan T, Garg AK. Dental Evidence in Forensic Identification – An Overview, Methodology and Present Status. *Open Dent J*. 2015;9:250–6. doi:10.2174/1874210601509010250.
6. Stavrianos C, Eliades A, Kokkas A. The role of DNA in forensic odontology (Part 1) DNA analysis methods. *Res J Med Sci*. 2010;4(6):334–9.
7. Pretty IA. Forensic dentistry: 2. Bitemarks and bite injuries. *Dent Update*. 2008;35(1):48–50.
8. Senn DR, Stimson PG. CRC press. 2010.
9. Bharathi S, Thenmozhi MS. Cheilioscopy-Lip print, an determination of sex and individual. *J Pharma Sci Res*. 2015;7(6):330.
10. Caldas IM, Magalhães T, Afonso A. Epub 2006 May 24. Establishing identity using cheilioscopy and palatoscopy. *Forensic Sci Int*. 2007;165(1):1–9.
11. Mohammed RB, Patil RG, Pammi VR, Sandya MP, Kalyan SV, Anitha A. Rugoscopy: Human identification by computer-assisted photographic superimposition technique. *J Forensic Dent Sci*. 2013;5(2):90. doi:10.4103/0975-1475.119771.
12. Manjunath K, Sriram G, Saraswathi T. Enamel rod end patterns: a preliminary study using acetate peel technique and automated biometrics. *J Forensic Odontol*. 2005;p. 33–36.
13. Füsün A, Füsün Ö, Sema B, Solen K. Acetate peel technique: a rapid way of preparing sequential surface replicas of dental hard tissues for microscopic examination. *Arch Oral Biol*. 2005;50(10):837–42. doi:10.1016/j.archoralbio.2004.06.009.
14. Ramenzoni LL, Line SRP. Automated biometrics-based personal identification of the Hunter-Schreger bands of dental enamel. *Proc Biol Sci*. 2006;273(1590):1155–8.
15. Gupta N, Jadhav K, Mujib BRA, Amberkar VS. Is re-creation of human identity possible using tooth prints? An experimental study to aid in identification. *Forensic Sci Int*. 2009;192(1-3):67–71. doi:10.1016/j.forsciint.2009.07.017.
16. Murgod S, Ravath CJM, Hegde RB, Girish HC. Amelogyphics and predilection of dental caries. *J Oral Maxillofac Pathol*. 2013;17(2):181. doi:10.4103/0973-029x.119752.
17. Manjunath K, Sivapathasundharam B. Analysis of enamel rod end pattern at different levels of enamel and its significance in amelogyphics. *J Forensic Sci*. 2014;5(4):1.
18. Singroha K, Banerjee A, Kamath VV, Pramod J, Alangkar S, Elampovai E. Scanning electron microscope corroboration of amelogyphics-A new tool in forensic odontology. *Int J Appl Basic Med Res*. 2020;10(2):76.

19. Kavitha B, Einstein A, Sivapathasundharam B, Saraswathi TR. Limitations in forensic odontology. *J Forensic Dent Sci.* 2009;1:8. doi:10.4103/0974-2948.50881.
20. Forrest AS. Collection and recording of radiological information for forensic purposes. *Aust Dent J.* 2012;57:24–32.

**Osheen Batra**, Post Graduate

**Latika Bachani Chopra**, Senior Lecturer

### Author biography

**Ravina Sorout**, Post graduate

**Cite this article:** Sorout R, Batra O, Chopra LB. Replicas in forensic dentistry for human identification. *Indian J Forensic Community Med* 2021;8(1):4-10.