

Content available at: <https://www.ipinnovative.com/open-access-journals>

Indian Journal of Forensic and Community Medicine

Journal homepage: <https://www.ipinnovative.com/journals/IJFCM>

## Original Research Article

# Clinical and pathological profile of paraquat poisoning cases - A cross-sectional study in Odisha, India

Manas Ranjan Sahu<sup>1</sup>, Mukul Sharma<sup>1,\*</sup>, Biplab Rath<sup>1</sup>, Tony Joseph<sup>1</sup>,  
Kimi Soumya Padhy<sup>1</sup>

<sup>1</sup>Dept. of Forensic Medicine and Toxicology, All India Institute of Medical Sciences, Bhubaneswar, Odisha, India



## ARTICLE INFO

## Article history:

Received 30-12-2020

Accepted 01-01-2021

Available online 08-01-2021

## Keywords:

Paraquat

Herbicide

Pulmonary fibrosis

Multi organ failure

## ABSTRACT

**Introduction:** Agriculture being the primary mode of occupation in Odisha leads to the rampant and widespread use of chemical pesticides and herbicides. Paraquat is a widely used herbicide. Ingestion of PQ irrespective of the quantity could be fatal with life-threatening effects on the gastrointestinal (GI) tract, kidney, liver, lungs, and other organs. Death is usually associated with respiratory insufficiency due to an oxidative insult to the Type-II alveolar epithelium with subsequent fibrosis.

**Materials and Methods:** All cases of paraquat ingestion coming to AIIMS, Bhubaneswar casualty from July 2020 to November 2020 were studied for their clinical findings. The fatal cases were subjected to autopsy and findings noted.

**Results:** Men were most commonly involved. All of the patients had self-harm intent while consuming. The most common presenting symptoms were difficulty in swallowing. Respiratory system was most commonly affected. The cause of death was attributed to respiratory and multi-organ failure.

**Discussion:** Paraquat is widely marketed for its efficacy and low environmental toxicity. Lack of a specific antidote increases the fatality. The most common cause of death is respiratory failure. Paraquat causes renal failure by causing hypovolemia, circulatory failure, septicemia, and direct toxicity. The mainstay of treatment is supportive though the use of immune-suppressants has shown some positive results.

© This is an open access article distributed under the terms of the Creative Commons Attribution License (<https://creativecommons.org/licenses/by/4.0/>) which permits unrestricted use, distribution, and reproduction in any medium, provided the original author and source are credited.

## 1. Introduction

Agriculture is the primary occupation of the people of Odisha with majority of population involved in it. This leads to wide and rampant use of chemical pesticides and herbicides which are easily available in the market. Paraquat (PQ) is N, N'-dimethyl-4, 4'-bipyridinium dichloride, a synthetic quaternary nitrogenous organic compound.<sup>1</sup> Its oxidative reactions were known and used in various chemical reactions. The herbicidal properties were not recognized until 1955 and then marketed in early 1962 under the name 'Gramoxone', and is today amongst the most commonly used herbicides.<sup>2</sup> It is a broad spectrum nonselective herbicide which acts on contact, destroys the

unwanted green plants by the formation of superoxide anion during photosynthesis.<sup>3</sup> Paraquat dichloride of 24% SL strength is registered in India with the Central Insecticide Board and Registration Committee (CIBRC).<sup>4</sup> Paraquat is a pungent corrosive liquid available in market commonly as 'All Quit', 'Finish', 'Gramex', 'Gramo', 'Gramoxone', etc. in India.<sup>5</sup> Ingestion of PQ irrespective of the quantity could be fatal with life-threatening effects on the gastrointestinal (GI) tract, kidney, liver, lungs and other organs.<sup>6</sup> Death is usually associated with respiratory insufficiency due to an oxidative insult to the Type-II alveolar epithelium with subsequent fibrosis.<sup>7</sup> There are no specific antidotes and none of the current treatments have proven successful in acute fulminant PQ poisoning.<sup>8</sup> Several studies have been done on PQ poisoning globally.<sup>9-14</sup> So far original articles with large sample sizes explaining various clinical scenarios

\* Corresponding author.

E-mail address: [mukul.med@gmail.com](mailto:mukul.med@gmail.com) (M. Sharma).

along with autopsy findings in India are rare or absent. Literature survey shows in the form of a case report with one or two cases revealing a wide range of initial symptomatic presentation with initial hospitalization and early discharge followed by other complication with various lag times leading to rehospitalization, thus creating a confusing clinical scenario affecting the management and outcome of the patients due to incidence of occasional poisoning. In this study we have tried to analyze the clinic-pathological profile of all the cases of paraquat poisoning presented to AIIMS, Bhubaneswar during the study period along with their specific autopsy findings and histopathological examination.

## 2. Materials and Methods

This is an observational study in which the poisoning cases with a history of paraquat ingestion, admitted to the Trauma and Emergency Department of AIIMS, Bhubaneswar from July, 2020 to November, 2020. The clinic-pathological findings observed during the hospital stays were documented in a proper preformed format designed for poisoning cases after a proper written informed consent. All the fatal cases were subjected to postmortem examination which was done in the Department of Forensic Medicine & Toxicology, which are also evaluated.

## 3. Results

There were 12 patients with a history of PQ ingestion were admitted during the study period. The diagnosis was based on the history, verification of the ingested herbicide, clinical findings and positive report from the Forensic Science Laboratory. All patients were included in the study. Their characteristics are summarized in the table. Most of the patients were treated symptomatically and used steroids for suppressing the inflammation.

### 3.1. Age & sex incidence

The lowest and highest ages observed were 18 years and 42 years. Both were males. Males were observed to be predominant sex. Five cases were female with age ranging from 20 years to 37 years.

### 3.2. Amount of ingestion

Most of the patients unable to tell the exact amount but usually its mouth full and the maximum amount was up to 30 ml with an exception of one case where the amount is around some drops with a full glass of water.

### 3.3. Commercial name

The commercial names of the PQ used are All Clear, Fire, Weedmar Super, Kapiq, and Swat.

### 3.4. Manner of intake

Deliberate intake in a rage of anger to self-harming was the reason of all ingestion. Most of them preferred to take after lunch, in their own house.

### 3.5. Earliest symptoms

Pain in the throat, difficulty in swallowing, hoarseness of voice, vomiting, decreased urination and loose stool were the common complaints in all the cases. 'Paraquat tongue' was observed in 5 cases. One case presented to the local hospital after 72 hours of consumption of the poison with additional symptoms of icterus and shortness of breath.

### 3.6. Earliest management

Gastric lavage and induced emesis were done in all cases within two hours of local hospitalization. All cases were discharged either on the same day or the next day from the local hospital and remained stable with minimal symptoms. The next admission is usually observed in AIIMS, Bhubaneswar with the most common complaint of shortness breath and oliguria. One case has no complication and was discharged after two days of hospital stay. Death was observed earliest after 36 hours to a maximum of 27 days even after aggressive management in higher set up like AIIMS. The local complication observed was oral ulceration mouth and tongue (paraquat tongue) (Figure 1). The systemic organs affected were gastrointestinal with hematemesis, respiratory system with trachea showing erosions and yellowish discoloration (Figure 2), and lungs with diffuse alveolitis and fibrotic changes on the bilateral lower lobes (Figure 3) and interstitial thickening leading to Type-1 respiratory failure, liver with centrilobular necrosis, and kidney with acute kidney injury (serum creatinine level greater than 1.5 mg/dl.) presenting with oliguria (Figure 4).

### 3.7. Cause of Death

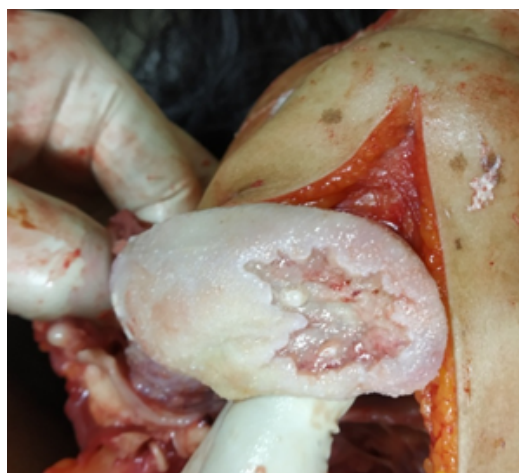Respiratory system was the most commonly affected system followed by gastro intestinal tract and kidneys. Respiratory failure and multi-organ failure were the main causes of death. All fatal cases were subjected to postmortem examination and the findings were also tabulated (Table 1).

## 4. Discussion

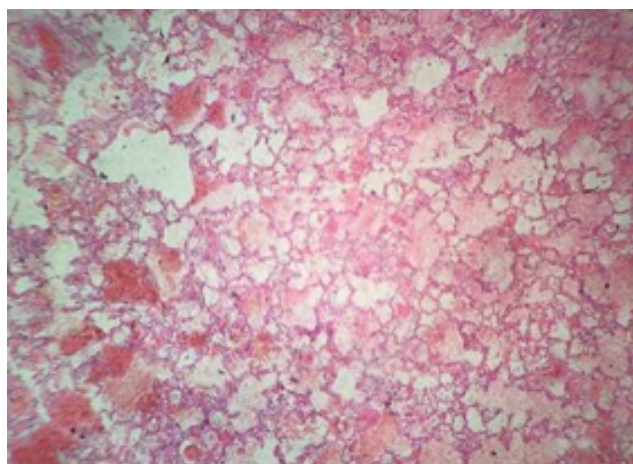
Majority of the population in Odisha and its bordering districts in Chhattisgarh are dependent on agriculture. Crop failures and family disturbances often drive people to look for poison to commit suicide. Nastaran Eizadi Mood et al. (2013) studied on 42 PQ poisoning cases mostly in male and third decade of life with the mortality rate 47%.<sup>9</sup> Rukhsana Parvin et al. (2016) reported a case of 15 years old girl who consumed 20 ml of PQ died on the 4<sup>th</sup> day

Table 1: Brief summary of the cases

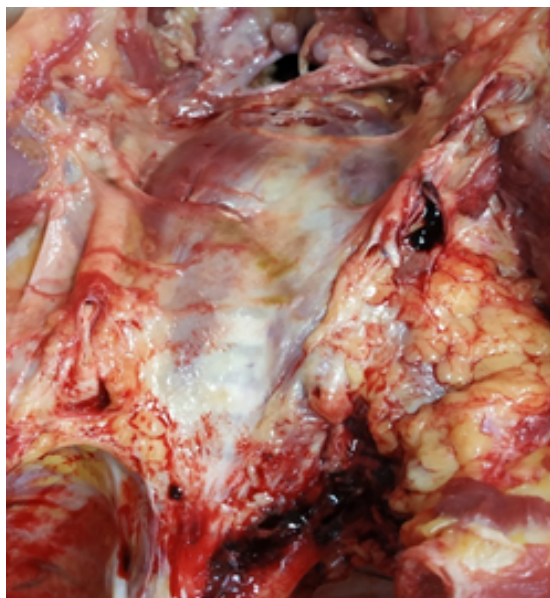
S.No.	Age (in years)	Gender	Manner	Amount	Time duration between consumption and admission	Organ System Involvement			Outcome	Time duration between consumption and death/discharge	Cause of death			
1	28	Male	Suicidal	15 - 30ml	3 days	GI	Liver	Respiratory	Renal	Yes	Yes	Death	27 days	Multi Organ failure
2	22	Male	Suicidal	15 - 30ml	2 days	Yes	Yes	Yes	Yes	Yes	Yes	Death	17 days	Multi Organ failure
3	18	Male	Suicidal	15 - 30ml	5 days	No	Yes	Yes	Yes	Yes	Yes	Death	13 days	Respiratory failure
4	22	Female	Suicidal	Around 20 ml	1 day	Yes	No	Yes	Yes	Yes	Yes	Death	8 days	Respiratory failure
5	20	Female	Suicidal	Unknown diluted with water	18 hrs	No	No	No	No	No	No	Discharged	2 days	NA-
6	30	Female	Suicidal	Around 20 ml diluted with coconut water	2 days	Yes	No	Yes	No	No	No	Death	7 days	Respiratory failure
7	41	Male	Suicidal	15 - 20 ml	12 hrs	No	Yes	Yes	Yes	Yes	Yes	Death	15 days	Multi Organ failure
8	37	Female	Suicidal	Around 15 ml	20 hrs	Yes	No	Yes	Yes	Yes	Yes	Death	7 days	Respiratory failure
9	42	Male	Suicidal	15 - 20 ml	1 day	Yes	No	Yes	Yes	Yes	Yes	Death	10 days	Respiratory failure
10	23	Male	Suicidal	Around 15 ml	1 day	Yes	Yes	Yes	Yes	Yes	Yes	Death	15 days	Multi Organ failure
11	34	Male	Suicidal	Around 30 ml	1 day	Yes	Yes	Yes	Yes	Yes	Yes	Death	8 days	Respiratory failure
12	29	Female	Suicidal	Around 20 ml	2 days	Yes	Yes	Yes	Yes	Yes	Yes	Death	10 days	Respiratory failure



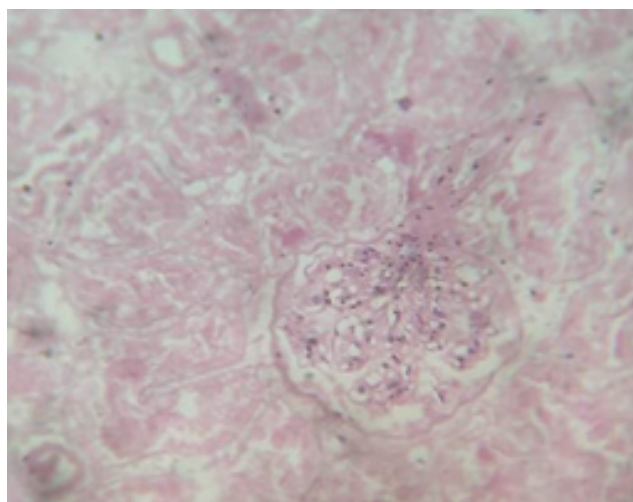
**Fig. 1:** 'Paraquat Tongue' (Ulceration on dorsum of tongue with yellowish discoloration)



**Fig. 3:** Diffuse alveolitis and fibrosis



**Fig. 2:** Yellowish discoloration and erosions on inner wall of Trachea



**Fig. 4:** Glomerular cellular infiltration

even after aggressive treatment.<sup>10</sup> Hsiao-Hui Chen et al. (2013) reported that corrosive action PQ is greater than the Glyphosate weedicide and systemic toxicity occurred with rapid development of hypoxia, hepatitis, and renal failure in many cases.<sup>11</sup> Hsieh YW et al. (2013) observed in six pediatric patients with 33.3% mortality.<sup>12</sup> Ja-Liang Lin et al. (2006) in a randomized control trial observed the mortality rate of the study group (five of 16, 31.3%) was lower than that of the control group (six of seven, 85.7%) with repeated pulse of methylprednisolone and cyclophosphamide with continuous dexamethasone therapy for patients with severe PQ poisoning.<sup>13</sup> Chen and colleagues successfully treated a case of severe PQ poisoning using repeated pulse therapy

of methylprednisolone.<sup>14</sup> It is observed that one tertiary healthcare Centre in Western Odisha registered more than 90% deaths in PQ poisoning.<sup>15</sup> PQ is highly toxic to human and has a high case fatality rate due to a lack of specific antidotes.<sup>14</sup> It is still widely used in many countries in the world because of its low cost and high efficacy.<sup>16</sup> It has low environmental toxicity due to rapid deactivation upon soil contact.<sup>17</sup> The routes of poisoning are ingestion and direct contact with the skin.<sup>18</sup> Direct contact of PQ with skin causes burns and dermatitis.<sup>19</sup> Contact with the eye may irritate, burn, corneal damage, and scarring.<sup>20</sup>

Lethality of PQ depends on the quantity ingested. A patient who has ingested a large amount (>40 ml) of PQ, generally presents with multi-organ dysfunction syndrome, pulmonary edema, cardiac, renal, and hepatic failure along with central nervous system involvement with seizure and have a higher chance of death.<sup>21</sup> Patients, who ingested smaller quantities, presented with predominant involvement

of two organs namely kidney and lungs, mortality in these groups also more than 50%.<sup>22</sup> The lethal dose in humans is approximately 35mg/kg body weight (10ml - 15ml of a 20% solution).<sup>23</sup> Clinical features depend upon the amount of ingested poison. After ingestion, it causes a burning sensation in the mouth, throat, abdominal pain, nausea, vomiting, and diarrhea. Severe oral ulcers may develop within a few days.<sup>24</sup> The tongue may be coated and inflamed with ulceration called 'Paraquat tongue' which was observed in six of our cases after third days of ingestion. It is poorly absorbed by oral route (about 10 – 30%), around 1% to 5% of an oral dose is absorbed in the intestine.<sup>25</sup> It is rapidly distributed in most tissues including lung and kidney.<sup>26</sup> It is rapidly eliminated via the kidney (90% eliminated within 12 to 24 hours).<sup>27</sup> Once absorbed, it rapidly distributes the tissue such as the liver, kidney, and lungs. After ingestion, the greatest PQ concentration is found in the lungs, and the concentration peak in 5 to 7 hours.<sup>15</sup> In lungs it causes pulmonary congestion, edema, hemorrhage, diffuse alveolitis, and extensive pulmonary fibrosis. Acute respiratory distress may occur after 24 to 48 hours after ingestion. PQ selectively accumulates in the capillary endothelial and epithelial cells of the lung and causes diffuse alveolitis followed by extensive pulmonary fibrosis in about 3-14 days. Lungs were usually affected in all the fatal cases with features of pulmonary edema and lung fibrosis. After absorption, its accumulation in the liver cause hepatic injury. PQ is eliminated mainly by the kidney and acute kidney failure is a recognized complication of its poisoning, with reports of oliguric and non-oliguric cases. PQ causes renal failure by causing hypovolemia, circulatory failure, septicemia, and direct toxicity. Multiple systems are involved but pulmonary features are predominant and are the usual cause of death. Late referral to the hospital, the severity of poisoning, and involvement of the kidney, liver, and lungs leading to multi-organ failure are the main cause of increased mortality in our study. The mainstay of treatment is supportive. Despite advances in treatment and supportive care, the mortality rate remains more than 90%. A very high case fatality of PQ is due to its inherent toxicity and lack of definitive treatment.

## 5. Source of Funding

None.

## 6. Conflict of Interest

The authors declare no conflict of interest.

## References

1. Roberts DM, Nelson LSH, Lewin NA, Howland MA, Hoffman RS, Goldfrank LR. Goldfrank's Toxicologic Emergencies. 9th ed. New York: McGraw Hill; 2011.
2. Costa LG. Toxic Effects of Pesticides . In: Klaassen CD, editor. Casarett and Doull's Toxicology - The Basic Science of Poisons. New York: Mc Graw Hill; 2013. p. 961.
3. Pesticides. In: Pillay VV, editor. Modern Medical Toxicology. vol. 6. New Delhi: Jaypee Brothers; 2013. p. 398–400.
4. Government of India. Major Uses of Pesticides. [Online]. Available from: [http://ppqs.gov.in/sites/default/files/mup\\_herbicide.pdf](http://ppqs.gov.in/sites/default/files/mup_herbicide.pdf).
5. Agricultural poisons. In: Aggarwal A, editor. Textbook of Forensic Medicine and Toxicology. Sirmour: Avichal Publishing Company; 2016. p. 610–1.
6. Wikipedia contributors. (2020, November 28). Paraquat. In Wikipedia, The Free Encyclopedia. Retrieved 12:09, December 24, 2020. Available from: <https://en.wikipedia.org/w/index.php?title=Paraquat&oldid=991084254>.
7. Mood NE, Sabzghabae AM, Ghodousi A, Yaraghi A, Mousavi A, Massoum G, et al. Histo-pathological findings and their relationship with age, gender and toxin amounts in paraquat intoxication. *Pak J Med Sci.* 2013;29(1(Suppl)):403–11. doi:10.12669/pjms.291(suppl).3543.
8. Parvin R, Hasan K, Sarkar P, Mouri NN. Fatal Paraquat Poisoning in a 15-Year-Old Girl. *J Enam Med Coll.* 2017;7(2):107–10. doi:10.3329/jemc.v7i2.32657.
9. Wang JW, Yang X, Ning BY, Yang ZY, Luo LH, Xiao H, et al. The successful treatment of systemic toxic induced paraquat poisoning by skin absorption: case reports and a literature review. *Int J Clin Exp Pathol.* 2019;12(9):3662–70.
10. Chen HH, Lin JL, Huang WH, Weng CH, Lee SY, Hsu CW, et al. Spectrum of Corrosive Oesophageal Injury after intentional paraquat or glyphosate-surfactant herbicide ingestion. *Int J Gen Med.* 2013;6:677–677.
11. Hsieh YW, Lin JL, Lee SY, Weng CH, Yang HY, Liu SH, et al. Paraquat poisoning in pediatric patients. *Ped Emerg Care.* 2013;29(4):487–91.
12. Lin JL, Lin-Tan DT, Chen KH, Huang WH. Repeated pulse of methylprednisolone and cyclophosphamide with continuous dexamethasone therapy for patients with severe paraquat poisoning. *Crit Care Med.* 2006;34(2):368–73.
13. Chen GH, Lin JL, Huang YK. Combined methylprednisolone and dexamethasone therapy for paraquat poisoning. *Crit Care Med.* 2002;30(11):2584–7.
14. Shadnia S, Ebadollahi-Natanzi A, Ahmadzadeh S, Mohajeri SK, Pourshejari Y, Rahimi HR. Delayed death following paraquat poisoning: three case reports and a literature review. *Toxicol Res.* 2018;7(5):745–53. doi:10.1039/c8tx00120k.
15. Narendra S, Vinaykumar S. Paraquat Poisoning: A Case Series in South India. *Int J Sci Res.* 2015;4(1):561–4.
16. Janeela MA, Oommen A, Misra AK, Ramya I. Paraquat poisoning: Case report of a survivor. *J Fam Med Prim Care.* 2017;6(3):672–3. doi:10.4103/2249-4863.222042.
17. Gawarammana IB, Buckley NA. Medical management of paraquat ingestion. *Br J Clin Pharmacol.* 2011;72(5):745–57. doi:10.1111/j.1365-2125.2011.04026.x.
18. Rajaram G, Lalitha AV. A case of Paraquat poisoning. *J Pediatr Crit Care.* 2016;3(3):63–8.
19. Pavan M. Acute Kidney Injury Following Paraquat Poisoning in India. *Iran J Kidney Dis.* 2013;7(1):64–6.
20. Somu B, Shankar SH, Baitha U, Biswas A. Paraquat poisoning. *QJM.* 2020;1113(10):752.
21. Raghu K, Mahesh V, Sasidhar P, Reddy PR, Venkataramanah V, Agrawal A. Paraquat poisoning: A case report and review of literature. *J Fam Community Med.* 2013;20(3):198–200. doi:10.4103/2230-8229.122023.
22. Mohan J, Iyyadurai R, Jose A, Das S, Johnson J, Gunasekaran K. Paraquat poisoning management. *Curr Med Issues.* 2019;17(2):34–7.
23. Dhochak N, Sankar J, Lodha R. Paraquat poisoning: An unusual lung toxicity. *J Pediatr Crit Care.* 2019;6(1):51–3.
24. Venkatanand K, Agrawal A, Sarma M. Paraquat poisoning-a dreadful and lethal poisoning: a case report of two cases from East Godavari, Andhra Pradesh, India. *Int J Res Med Sci.* 2016;4:3048–51. doi:10.18203/2320-6012.ijrms20162003.

25. Biswas S, Das A, Das N, Sengupta D, Mondal S, Sukul B. Paraquat Poisoning: A Fatal Issue in Rural West Bengal, India. *Int J Educ Res Health Sci.* 2017;3(4):209–13.
26. Gawarammana IB, Dawson AH. Peripheral burning sensation: a novel clinical marker of poor prognosis and higher plasma-paraquat concentrations in paraquat poisoning. *Clin Toxicol.* 2010;48(4):347–9. doi:10.3109/15563651003641794.
27. Gawarammana I, Buckley NA, Mohamed F, Naser K, Jeganathan K, Ariyananda PL, et al. High-dose immunosuppression to prevent death after paraquat self-poisoning – a randomised controlled trial. *Clin Toxicol.* 2018;56(7):633–9. doi:10.1080/15563650.2017.1394465.

**Mukul Sharma**, Senior Resident

**Biplab Rath**, Junior Resident

**Tony Joseph**, Junior Resident

**Kimi Soumya Padhy**, Junior Resident

### Author biography

**Manas Ranjan Sahu**, Associate Professor

**Cite this article:** Sahu MR, Sharma M, Rath B, Joseph T, Padhy KS. Clinical and pathological profile of paraquat poisoning cases - A cross-sectional study in Odisha, India. *Indian J Forensic Community Med* 2020;7(4):210-215.