



## Original Research Article

## Study of incidence of wormian bones in southern Haryana - A prospective observational study

Shiv Shankar<sup>1,\*</sup>, Hitesh Chawla<sup>1</sup>, Rajeev Kumar<sup>1</sup>, Ashish Tyagi<sup>1</sup>, Bhushan Vashishtha<sup>1</sup>, Jyoti Panchal<sup>2</sup><sup>1</sup>Dept. of Forensic Medicine, SHKM Government Medical College, Nalhar, Haryana, India<sup>2</sup>School of Medical Sciences & Research, Sharda University, Greater Noida, Uttar Pradesh, India

## ARTICLE INFO

## Article history:

Received 15-09-2020

Accepted 12-10-2020

Available online 29-10-2020

## Keywords:

Skull

Suture

Wormian bones

Fractures

## ABSTRACT

**Introduction:** Wormian bones are those bones which found in the cranium having no regular relation to their normal ossification centres. They may be deceived for a fracture skull. The present study was conducted to evaluate the percentage of skulls where wormian bones were present, b anatomical distribution of wormian bones, side specific distribution of wormian bones, and range of observed wormian bones.

**Materials and Methods:** The present study was conducted in the Department of Forensic Medicine in Government Medical College of Southern Haryana over a period of one year from January 2019 to December 2019. A total number of 130 cases brought for postmortem examination were studied. 86 male and 44 female dead bodies were studied. Location of wormian bones along the coronal, sagittal and lambdoid suture on ectocranial surface was noted.

**Results:** The overall incidence of wormian bones was 20.78%. 19 wormian bones (14.62%) were observed in males and 8 (6.15%) in females. Wormian bones were most commonly located in lambdoid suture that is in 19 (14.62%) cases. Out of 19 wormian bones observed around lambdoid suture, 11 (57.90%) were found on left half of the skull and 3 (15.79%) were on right half of the skull.

**Conclusion:** Knowledge of wormian bones is clinically important for forensic experts, neurosurgeons and radiologists because many a time's wormian bones may be misinterpreted for fractures in head injuries. The knowledge of wormian bones may help the doctors in their daily practice in timely diagnosis and management of diseases or fractures in relation to the wormian bones.

© 2020 Published by Innovative Publication. This is an open access article under the CC BY-NC license (<https://creativecommons.org/licenses/by-nc/4.0/>)

## 1. Introduction

Wormian bones are those bones which are found in the cranium having no regular relation to their normal ossification centres. They occurs frequently and generally occupy the sutures and fill fontanelles of neonatal skull.<sup>1</sup> Wormian bones are also known as Schaltknochen (Leichner-Weil, 1964), Supernumerary ossicles, Intercalary, and Sutural & Intrasutural bones.<sup>2</sup> They are unnamed bones because they vary from person to person in number and shape. The wormian bones resemble bones of the skull and involve both internal and external surface of the

cranial vault. They articulate with surrounding bone of the cranium by sutures. They are named after Olaus Worm, a Danish anatomist who described them in a letter to Thomas Bartholin in 1643. Subsequently, Bartholin named them as Ossa Wormiana, their present name. They are formed due to alterations in the normal formation of the flat skull bones and are usually regarded as normal variants. Sometime they can be considered as an abnormal anatomical variant because they are frequently found in certain bone dysplasia conditions including osteogenesis imperfecta, rickets, cleidocranial dysostosis, and pycnodysostosis<sup>3,4</sup> and some other conditions like “Kinky hair” Menke’s syndrome, Hypothyroidism, Hypophosphatasia, Otopalatodigital syndrome, and Down’s syndrome.<sup>5</sup> The formation of sutural

\* Corresponding author.

E-mail address: [shivshankarmbs@gmail.com](mailto:shivshankarmbs@gmail.com) (S. Shankar).

bones is assumed to be controlled by genetic factors.<sup>6</sup> Etiology about prevalence and mechanisms of wormian bones formation in the skull are still unknown.<sup>7</sup> Knowledge of these bones is important for anthropologists, forensic experts, radiologists, orthopedicians and neurosurgeons to avoid deception for fractures of the skull.<sup>8,9</sup> In the present study our objective was to evaluate the percentage of skulls where wormian bones were present, anatomical distribution of wormian bones, side specific distribution of wormian bones and the range of observed wormian bone.

## 2. Material and Methods

The present study was conducted in the Department of Forensic Medicine in Government Medical College of Southern Haryana over a period of one year from January 2019 to December 2019. A total number of 130 cases brought for postmortem examination were studied. 86 male and 44 female dead bodies were studied. Skulls of both sexes with deformed or diseased or fractured skull were excluded from the study population.

Scalp was reflected anteriorly to a level 1-2 cm above the supraorbital ridge and posteriorly to a level just above the external occipital protuberance.<sup>10</sup> Temporal muscles were dissected and the periosteum was denuded. Location of wormian bones along the coronal, sagittal and lambdoid suture on ectocranial surface were noted. Photographs of wormian bones were captured using good resolution camera of 24 megapixels without any filter and zoom effect. In our study, only the bones surrounded by apparent sutures were recorded as wormian bones and only the obvious ones were considered.

## 3. Observations and Results

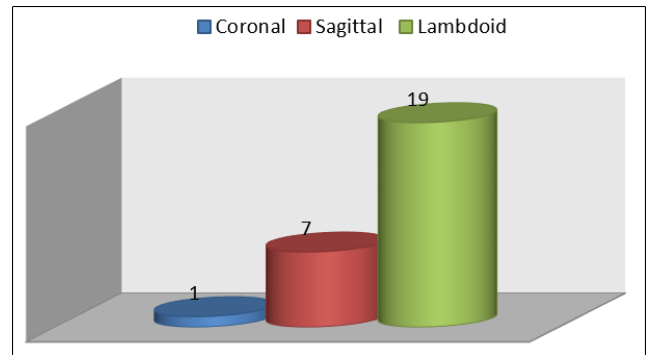
In present study the incidence of wormian bones was 20.78% (27/130). Out of these 19 (14.62%) male skulls and 8 (6.15%) female skulls showed wormian bones. (Table 1)

**Table 1:** Overall Incidence of Wormian bones in total subjects

| Wormian bones | Males       | Females     | Total (%)   |
|---------------|-------------|-------------|-------------|
| Present       | 19 (22.09%) | 8 (18.18%)  | 27 (20.8%)  |
| Absent        | 67 (77.91%) | 36 (81.82%) | 103 (79.2%) |
| Total         | 86 (100%)   | 44 (100%)   | 130 (100%)  |

Wormian bones were most commonly located in lambdoid suture (19/130, 14.62%), followed in order of frequency by sagittal suture (7/130, 5.38%). Only one case showed wormian bone in coronal suture (0.77%, 1/130) (Graph 1).

Out of 19 wormian bones, 11 (57.90%) were found on left half of the skull and 3 (15.79%) were on right half of the skull in the lambdoid suture. Five cases (26.31%) showed wormian bones on both right and left side of lambdoid



**Graph 1:** Graphical representation of incidence of Wormian bones in different sutures

suture. Only 1 (0.77%) case showed wormian bone in right side of coronal suture. (Table 2)

**Table 2:** Incidence of Wormian bones at different Locations

| Location of Wormian Bones | Left side | Right side | Both Right and Left |
|---------------------------|-----------|------------|---------------------|
| Coronal Suture            | 0         | 1          | 0                   |
| Lambdoid Suture           | 11        | 3          | 5                   |

The present study depicted the occurrence of a single wormian bone in 10 (7.69%) skull only. Multiple wormian bones were observed in 17 (13.08%) cases. (Table 3)

**Table 3:** Range of observed wormian bones

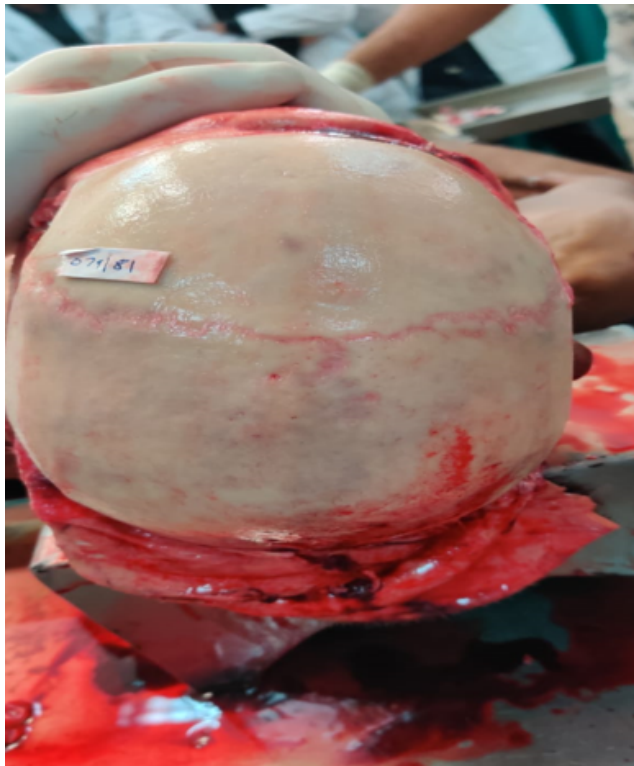
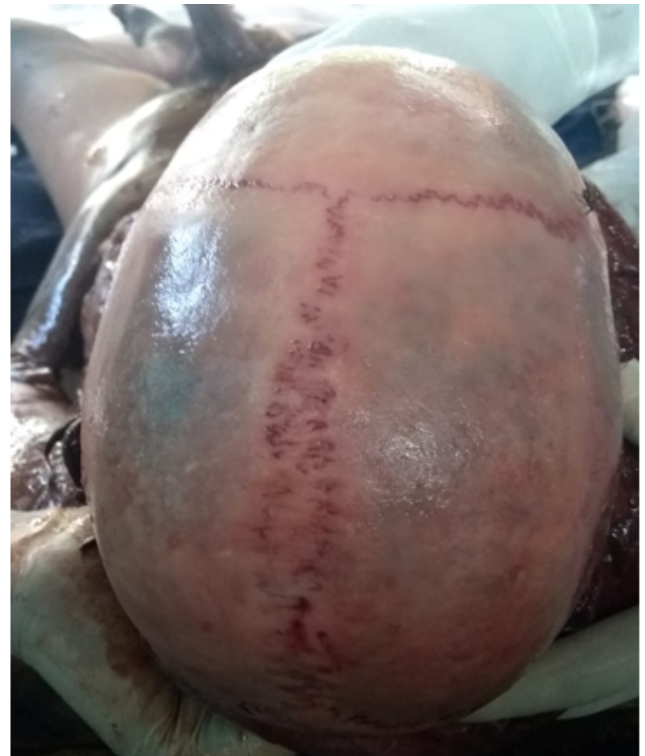| Wormian bone present | No. of cases |
|----------------------|--------------|
| Single               | 10 (7.69%)   |
| Multiple             | 17(13.08%)   |

## 4. Discussion

Wormian bones are very common finding seen in human skulls. We have known of wormian bones for a very long time.<sup>9,11,12</sup> In our study, incidence of the wormian bones was found to be 20.78%. The incidence of wormian bones varies in the literature. A study in Greece presented over 124 skulls (74.7%) having wormian bones out of total 166 skulls.<sup>13</sup> In a study done by Saxena et al. in Nigeria incidence of wormian bones was 2.5% which was very less as compared to our study.<sup>14</sup> Marty et al. studied the incidence of wormian bones in France on 605 CT brains scans from normal child population excluding constitutional bone diseases, found an incidence of 53% which was higher as compared to our study.<sup>4</sup> In another study from West Bengal on 120 unknown adult skulls found the incidence of wormian bones being 45%.<sup>11</sup> In a study done by Goyal et al. in Haryana over 147 subjects, overall incidence of wormian bones was seen in 52 skulls (35.3%).<sup>12</sup> The variation may be due sample size and place of study. The incidence of

**Table 4:** Comparison of incidence of Wormian bones in various studies

| S. No. | Study                       | Year | Region           | No. of cases | %      |
|--------|-----------------------------|------|------------------|--------------|--------|
| 1      | Saxena et al. <sup>14</sup> | 1985 | Nigeria          | 40           | 2.5%   |
| 2      | Masih et al. <sup>9</sup>   | 2013 | Rajasthan        | 150          | 4.7%   |
| 3      | Marti et al. <sup>4</sup>   | 2013 | France           | 605          | 53%    |
| 4      | Ghosh et al. <sup>11</sup>  | 2016 | West Bengal      | 120          | 45%    |
| 5      | Reddy et al. <sup>15</sup>  | 2018 | Telangana        | 100          | 48%    |
| 6      | Natsis et al. <sup>13</sup> | 2018 | Greece           | 166          | 74.7%  |
| 7      | Goyal et al. <sup>12</sup>  | 2018 | Haryana          | 147          | 35.37% |
| 8      | Present study               | 2019 | Southern Haryana | 130          | 20.78% |

**Fig. 1:** Wormian bone in right coronal suture**Fig. 2:** Wormian bone in sagittal suture

wormian bones according to various studies is depicted in Table 4.

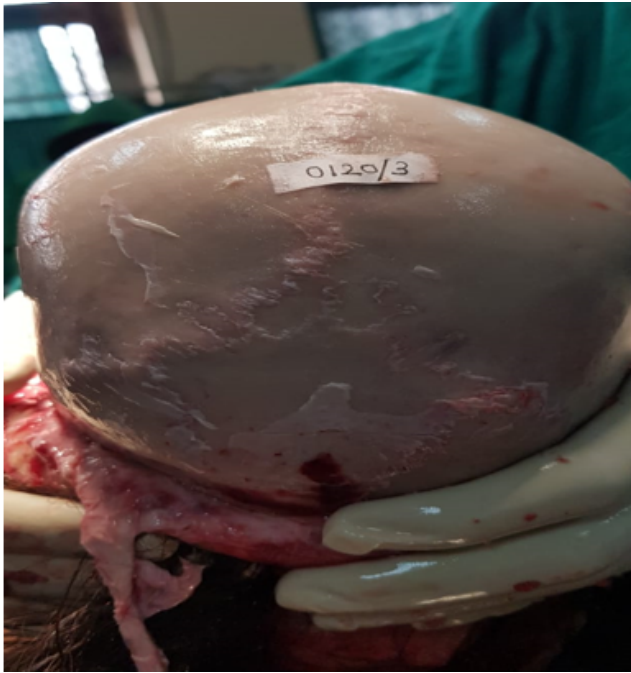In our study the most common site of wormian bone was at lambdoid suture (14.62%), this observation was supported by Natsis et al., who in their study over 166 human skulls also observed the higher incidence of wormian bone in the lambdoid suture (44.6%).<sup>13</sup> Anitha et al. also observed higher incidence of wormian bone in the lambdoid suture, in their study conducted over 50 skulls.<sup>16</sup> Similarly, Marti et al. and Goyal et al. in their respective studies also showed maximum incidence of wormian bones along with lambdoid suture.<sup>4,12</sup> In the present study, the second most common site of wormian bone was at sagittal suture (5.38%). Only 1 (0.77%) case showed wormian bone in coronal suture. In an anthropological study of 1500 skulls,

Tewari et al.<sup>16</sup> did not find any wormian bones in the coronal or sagittal sutures.<sup>17</sup>

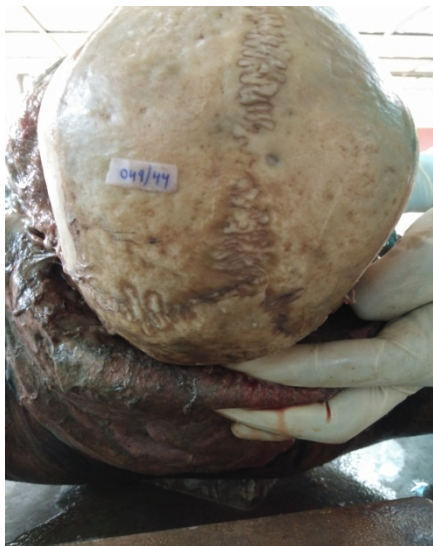We observed that wormian bones were present on left side of skull in 11(57.90%) of cases and 3(15.79%) on right side of skull which was consistent with the study done by Patel et al. who observed wormian bones on the left half of skull in 48.1% of cases and 37.03% on right half of skull.<sup>8</sup> Present study depicts wormian bones in five cases (26.31%) on both right and left side of lambdoid suture. Only 1 (0.77%) case showed wormian bone in right side of coronal suture in our study. Study done by Natsis et al also showed incidence of wormian bones in one case (0.6%) only.

The presence of wormian bone was observed more in males 19 (14.62%) than in females (6.15%) in present study. Observations made by Masih et al. in the study





**Fig. 3:** Wormian bone in lambdoid suture



**Fig. 4:** Wormian bones in sagittal and left side of lambdoid suture

conducted at Rajasthan were in concordance with our study results. Incidence of wormian bone was higher in males as compared to females in their study.<sup>9</sup> However, study conducted by Natsis et al. showed no gender wise difference in the incidence of Wormian bones.<sup>13</sup>

The present study showed the occurrence of a single wormian bone in 10 (7.69%) skull only. Multiple wormian bones were observed in 17 (13.08%) cases. Study done by Saxena et al. showed occurrence of single wormian bone in one skull only. Multiple wormian bones were observed in four skulls in their study. Ghosh et al. also observed in their

study that 18 (15%) skulls had a single wormian bone and 36 (30%) skulls had multiple wormian bones.<sup>11</sup>

## 5. Conclusion

Our study shows that wormian bones may be found even in coronal and sagittal suture in addition to the usual site in lambdoid suture. Knowledge of wormian bones is clinically important for forensic experts, neurosurgeons and radiologists because many a time's wormian bones may be misinterpreted for fractures in head injuries. Sometime wormian bones may fall in decomposed bodies which give rise to appear as entry or exit gunshot wound. The knowledge of wormian bones may help the doctors in their daily practice in timely diagnosis and management of diseases or fractures in relation to the wormian bones.

## 6. Source of Funding

Nil.

## 7. Conflicts of Interest

None.

## References

1. Srivastava H. Ossification of the membranous portion of the squamous part of the occipital bone in man. *J Anat.* 1992;180:219–24.
2. Nayak S. Multiple wormian bones at the lambdoid suture in an Indian skull. *Neuroanat.* 2008;7:52–3.
3. Reinoso MG, Pimentel H, Delgado RF, Stoeter P. Unusually Large Anterior Fontanelar Bone and Diffuse Capillary Malformation with Overgrowth in a Three-Month-Old Child. *Neuroradiol J.* 2014;27(5):613–5.
4. Marti B, Sirinelli D, Maurin L, Carpentier E. Wormian bones in a general paediatric population. *Diagn Interv Imaging.* 2013;94(4):428–32.
5. Wormian Bones: Differential Diagnosis #6; 2012.
6. El-Najjar M, Dawson GL. Photographic regional atlas of bone disease. *Am J Phys Anthropol.* 1977;46:155–60.
7. Reveron RR. Anatomical classification of sutural bones. *MOJ Anat Physiol.* 2017;3:101.
8. Patel D, Chauhan K, Patil D. Morphological study of wormian bones in dried human skulls. *Natl J Med Res.* 2015;5(3):222–5.
9. Masih WF, Gupta S, Chand AE, Jaiswal P, Saraswat PK. Incidence of wormian bone in human skulls in Rajasthan. *J Evol Med Dent Sci.* 2013;2(9):1001–4.
10. Ludwig J. Handbook of autopsy practice. 3rd ed. New Jersey: Humana Press; 2002.
11. Ghosh SK, Biswas S, Sharma S, Chakraborty S. An anatomical study of wormian bones from the eastern part of India: is genetic influence a primary determinant of their morphogenesis? *Anat Sci Int.* 2017;92:373–82.
12. Garg A, Goyal N, Kumar Y. Incidence and medicolegal significance of wormian bones in human skulls in North India Region. *Int J Appl Basic Med Res.* 2019;9(3):165.
13. Natsis K, Piagkou M, Lazaridis N, Anastasopoulos N, Nousios G, Piagkos G, et al. Incidence, number and topography of Wormian bones in Greek adult dry skulls. *Folia Morpholo.* 2019;78(2):359–70.
14. Saxena SK, Chowdhary DS, Jain SP. Interparietal bones in Nigerian skulls. *J Anat.* 1986;144:235–7.
15. Reddy U, Reddy MV. Study of wormian bones in adult dry skulls of human cadaver. *Int J Anat Res.* 2018;6(3.3):5632–6.

16. Anitha V, Jalharish G, Rishi SM, Rishwanth VH. Wormian Bones - An Original Research Article. *Int J Sci Res.* 2017;6(10):782–4.
17. Tewari PS, Malhotra VK, Agarwal SK, Tewari SP. Preinterparietal bone in man. *Anat Anz.* 1982;152:337–9.

**Ashish Tyagi** Assistant Professor

**Bhushan Vashishtha** Demonstrator

**Jyoti Panchal** Intern

### Author biography

**Shiv Shankar** PG Resident

**Hitesh Chawla** Associate Professor

**Rajeev Kumar** Professor

**Cite this article:** Shankar S, Chawla H, Kumar R, Tyagi A, Vashishtha B, Panchal J. Study of incidence of wormian bones in southern Haryana - A prospective observational study. *Indian J Forensic Community Med* 2020;7(3):129-133.