

Content available at: <https://www.ipinnovative.com/open-access-journals>

Journal of Oral Medicine, Oral Surgery, Oral Pathology and Oral Radiology

Journal homepage: www.joooo.org

Case Report

An eight-year-old boy with large complex odontoma in maxillary anterior area associated with unerupted tooth

Shoborose Tantray^{1,*}, Andleeb Manhas², Keerti Chauhan³

¹Dept. of Oral and Maxillofacial Pathology and Microbiology, Santosh Dental College and Hospital, Ghaziabad, Uttar Pradesh, India

²Dept. of Dentistry, Sher - i - Kashmir Institute of Medical Sciences, Srinagar, Jammu and Kashmir, India

³Dept. of Oral and Maxillofacial Pathology and Microbiology, Dental College, Azamgarh, Uttar Pradesh, india



ARTICLE INFO

Article history:

Received 25-01-2021

Accepted 03-02-2021

Available online 18-02-2021

Keywords:

Odontomas

Hamartoma

Denticles

Odontogenic tumour

ABSTRACT

Odontomas are the most common odontogenic benign tumors composed of dental tissue. The term odontoma was first coined by Broca (1866); he defined odontoma as a tumor formed by an overgrowth of complete dental tissues. They can be thought of as “tooth hamartomas” with the lesion consisting of various tooth components. Histologically Odontomas are divided into complex and compound odontomas. In this paper we are describing the case of a complex odontoma in an eight -year-old boy diagnosed due to the retention of the permanent left maxillary central and lateral incisor. A surgical excision was performed without distressing the unerupted central and lateral incisor. The results obtained indicate that early diagnosis of odontomas enables adoption of less complex treatment, a better prognosis, and displacement or devitalisation of adjacent tooth.

© This is an open access article distributed under the terms of the Creative Commons Attribution License (<https://creativecommons.org/licenses/by/4.0/>) which permits unrestricted use, distribution, and reproduction in any medium, provided the original author and source are credited.

1. Introduction

Odontomas are the most common benign odontogenic tumors, characterized by their slower growth and non-aggressive behaviour.¹ In 1866 the term odontoma was first coined by Paul Broca, who defined it as a tumour of overgrowth of complete dental tissue.² These Odontomas are considered to be developmental anomalies resulting from the growth of completely differentiated epithelial and mesenchymal cells that give rise to ameloblasts and odontoblasts. These odontogenic tumours are mostly formed of enamel and dentin however can also contain variable amounts of cementum and pulp tissue.^{3,4} These tumours are thought to be hamartomas and not true neoplasms because the epithelial and mesenchymal cells and tissues of an odontoma can appear normal but are deficient in structural arrangement.⁵ Although etiology of odontoma is still unknown however it has

been suggested local traumas or infections may cause odontomas.⁶ On radiographic examination, odontomas appear as dense radiopaque lesions with prominent external margins surrounded by a thin radiolucent zone.^{7,8} In 2005 the World Health Organization (WHO) has classified odontomas on the basis of the histopathological findings: complex odontomas, and compound odontomas. Complex odontomas are the ones in which dental tissues are well-formed but unstructured and these tissues are haphazardly arranged, on the contrary in compound odontomas, the dental tissues are normal, arranged in an orderly pattern, but their size and anatomy are altered, giving rise to numerous small teeth like elements called odontoids or denticles.⁹ It has been reported that majority of odontomas which are located in the anterior region of the maxilla are compound, while the great majority of odontomas located in the posterior areas, especially in the mandible, are of the complex types.¹ Excision of odontoma is advised in the absence of any contraindication. Prognosis after treatment is very favourable, with scant relapse.^{10,11}

* Corresponding author.

E-mail address: shabroztantray@gmail.com (S. Tantray).

2. Case Report

An Eight-year-old boy, came to the Department of Oral and Maxillofacial Pathology with a chief complaint of missing left upper front teeth since birth.(Figure 1) Patient’s medical and family history were indecisive. Intraoral examination revealed the presence of class IV caries w.r.t 53 and 63.

Area of chief complaint: Site: Left maxillary anterior region of the jaw. Extending from maxillary labial frenum to the canine prominence. (Figure 2) Labial vestibule was obliterated with no palatal extension, ovoid in shape, with smooth overlying surface epithelium. Overlying and surrounding mucosa were normal. Measuring about 2 x 1cm in size.(Figure 3) Consistency was bony hard texture was smooth and it was non tender. All the findings were confirmed on palpation.

The radiographic examination revealed the irregular ill-defined calcified masses in the upper Anterior region. Multiple impacted tooth like denticles/malformed/irregular opacities were noted w.r.t impacted teeth 21,22.(Figure 4) An OPG revealed the same finding as seen in intraoral periapical radiograph.(Figure 5)

On the basis of clinical and radiographic examination, a provisional diagnosis of complex odontome was made.

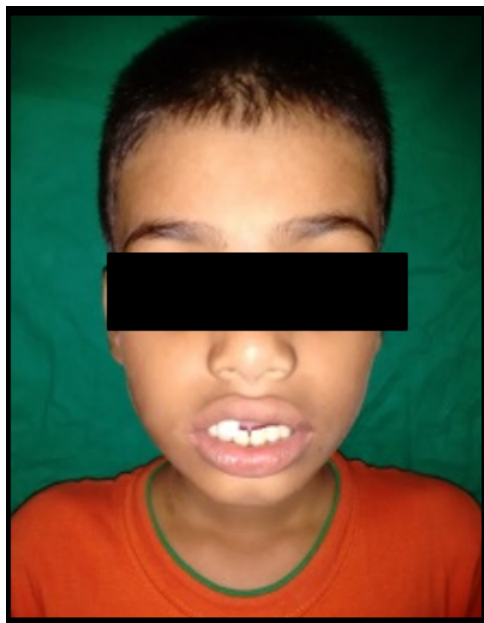

Fig. 1: Extra- oral view

Trapezoidal incision was made and a full thickness mucoperiosteal flap was raised showing bony prominence w.r.t labial cortical plate. Well encapsulated multiple tooth like denticles along with thin labial cortical plate were removed. Simple interrupted sutures were placed. The excised tooth like denticles were received by Department of Oral and maxillofacial Pathology for histopathological examination.

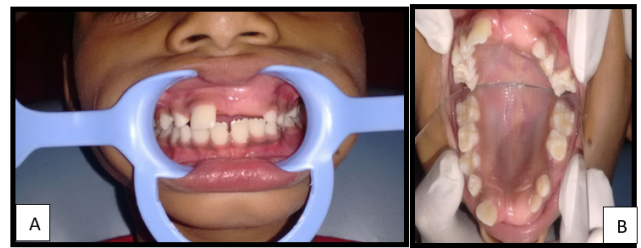

Fig. 2: (A) & (B) Intraoral examination showing missing 21,22

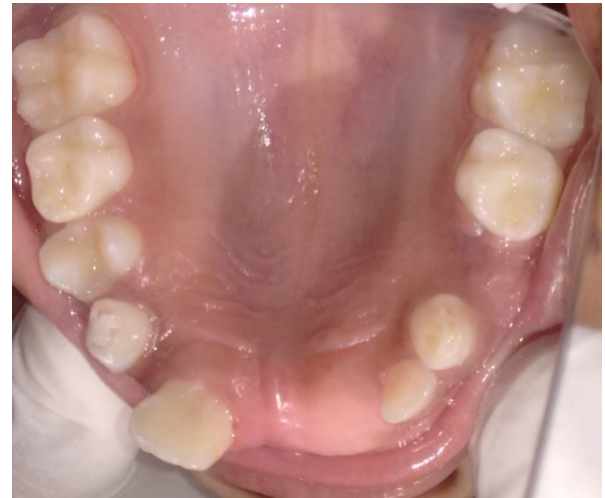

Fig. 3: Maxillary view- showing prominence in labial cortical plate, no palatal prominence

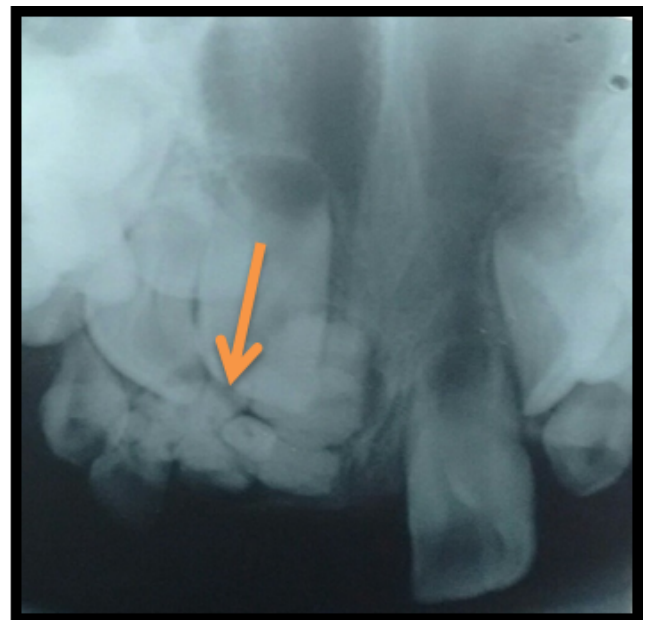


Fig. 4: Malformed/irregular opacities noted w.r.t impacted teeth 21,22

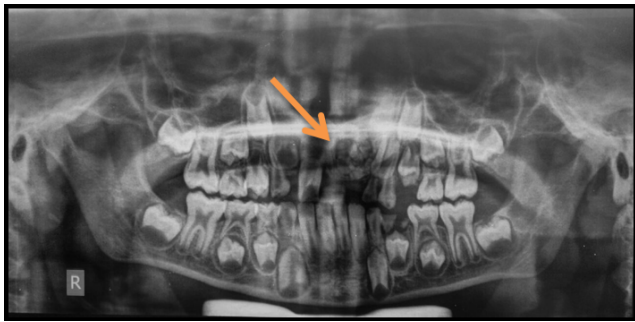


Fig. 5: Multiple impacted tooth like denticles/malformed/irregular opacities noted w.r.t impacted teeth 21,22.

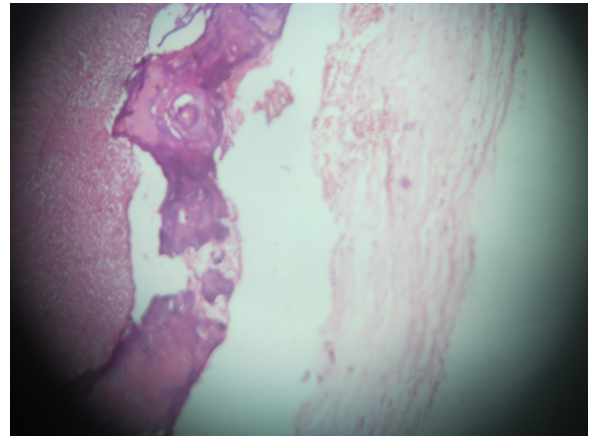


Fig. 8: Low power view: Showing dentinal tubules, enamel matrix & soft tissue

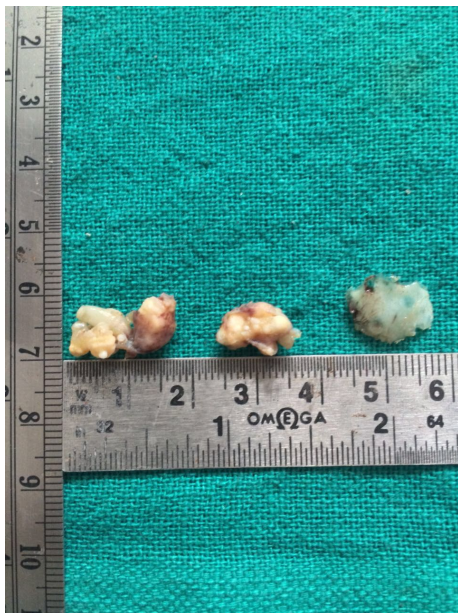


Fig. 6: Excised specimen

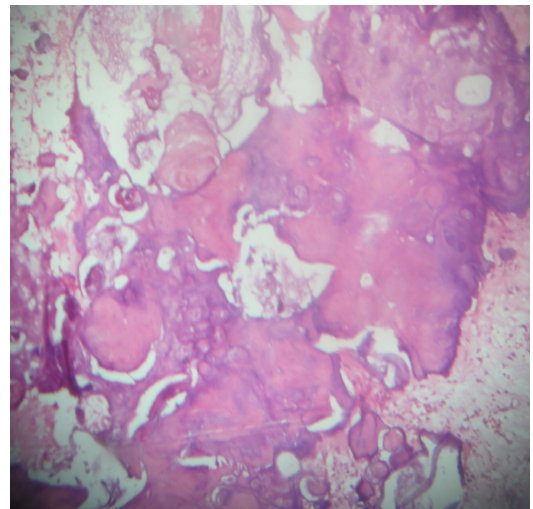


Fig. 9: High power view showing: dentin, enamel spaces, enamel matrix appears as hematoxylinic fibrillar material

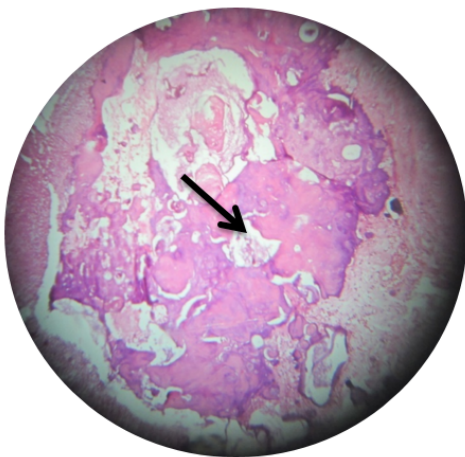


Fig. 7: Scanner view: The dentin matrix is eosinophilic and contains tubules, arrangement of these tissues is disordered

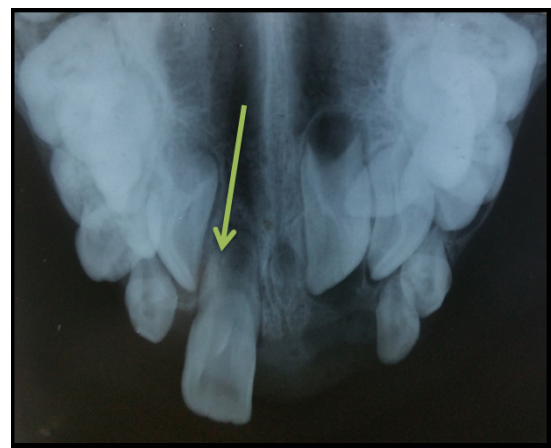


Fig. 10: No radio-opaque denticles are seen in the 21, 22 region. Erupting permanent incisors much below the basal maxilla compared to pre-operative view

On gross examination the specimen received were calcified masses and were irregular in shape.(Figure 6) The specimen was decalcified and processed in the conventional manner. On histopathological examination the specimen revealed the dentin matrix which was eosinophilic and contains tubules. The arrangement of these tissues was disordered dentin, enamel spaces, enamel matrix appeared as hematoxyphillic fibrillar material.(Figures 7, 8 and 9)

On the basis of clinical, radiographical and histopathological investigations a diagnosis of complex odontoma was given other provisional diagnosis are compound odontome, Adenomatoid odontogenic tumor and Dentigerous cyst.

Three months postoperatively, OPG was advised to check for the eruption of permanent incisors (Figure 10) and revealed a continuous eruption of the tooth into the oral cavity.

3. Discussion

Complex odontoma is a common odontogenic tumor, and it is usually a hard painless mass, which rarely exceeds diameter of the tooth. Odontomas are mostly discovered accidentally on radiographics. Symptoms of complex odontomas include impacted permanent teeth and swelling. Budnick in 1976 concluded that 61% of cases are associated with impacted teeth.¹² As seen in our case report permanent central and lateral incisors were impacted. The origin of complex odontoma is still unclear; some studies suggest trauma or infection to be the cause. In a study conducted by Lopez-Areal et al, they evaluated that a 10 months year old child developed multiple odontomas after experiencing trauma with intrusion of incisor teeth.¹³ A study conducted by Hitchin, reported that odontomas are inherited or developed as a result of genetic mutation.¹⁴ The individuals having Gardner's syndrome which is a heritable syndrome an increased number of odontomas were seen.¹⁵ Recurrence of complex odontomas is exceptional. On radiographic examinations, complex odontoma appears as a radiopaque mass which does not resemble tooth structure. Microscopically the complex odontoma is characterized by sheets of immature tubular dentin with encased hollow tooth like structures.(Figures 7, 8 and 9) Conservative surgical excision of the lesion is the treatment of choice.

4. Conclusion

In general odontomas are common odontogenic tumours, however when compared to other odontomas, complex odontomas are very unusual. Complex odontomas should be surgically excised because they are characterized by expansion of cortical plates and if left untreated can cause pathological fracture of the bone.

5. Source of Funding

None.

6. Conflict of Interest

The authors declare that there is no conflict of interest.

References

1. Shafer WG, Hine MK, Levy BM. Cysts and tumours of the jaws," in A Textbook of Oral Pathology. 4th ed. Philadelphia, Pa, USA: WB, Saunders; 1997.
2. Cohen DM, Bhattacharyya I. Ameloblastic fibroma, ameloblastic fibro-odontoma, and odontoma. *Oral Maxillofac Surg Clin N Am.* 2004;16(3):375–84. doi:10.1016/j.coms.2004.03.005.
3. Philipsen H, Reichart P, Prtorius F. Mixed odontogenic tumours and odontomas. Considerations on interrelationship. Review of the literature and presentation of 134 new cases of odontomas. *Oral Oncol.* 1997;33(2):86–99. doi:10.1016/s0964-1955(96)00067-x.
4. Cuesta SA, Albiol JG, Aytes LB, Escoda CG. Review of 61 cases of odontoma. Presentation of an erupted complex odontoma. *Med Oral.* 2003;8(5):366–73.
5. Shekar SE, Rao RS, Gunasheela B, Supriya N. Erupted compound odontome. *J Oral Maxillofac Pathol.* 2009;13(1):47–50. doi:10.4103/0973-029x.48758.
6. Dagstan S, Goregen M, Miloglu O. Compound odontoma associated with maxillary impacted permanent central incisor tooth: a case report. *Int J Dent Sci.* 2007;5(2).
7. Sprawson E. Odontomes. *Br Dent J.* 1937;62:177–201.
8. Bimstein E. Root dilaceration and stunting in two unerupted primary incisors. *ASDC J Dent Child.* 1978;45(3):223–5.
9. Barnes L, Eveson JW, Reichart P, Sidransky D. World Health Organization Classification of Tumours. Pathology and Genetics of E558 Head and Neck Tumours. Lyon, France: IARC Press; 2005.
10. Waldron AC. Odontogenic cysts and tumours. In: Neville BW, editor. *Oral and Maxillofacial Pathology.* Philadelphia, Pa, USA: WB Saunders; 2002. p. 631–2.
11. White SC, Pharoah MJ. Benign tumours of the jaws. In: *Oral Radiology: Principles and Interpretation.* St. Louis, Mo, USA: Mosby; 2004. p. 424–8.
12. Budnick SD. Compound and complex odontomas. *Oral Surge, Oral Me, Oral Pathol.* 1976;42:501–6. doi:10.1016/0030-4220(76)90297-8.
13. Lopez-Areal L, Donat FS, Lozano JG. Compound odontoma erupting in the mouth: 4-year follow-up of a clinical case. *J Oral Pathol Med.* 1992;21(6):285–8. doi:10.1111/j.1600-0714.1992.tb01012.x.
14. Hitchin AD. The aetiology of the calcified composite odontomes. *Br Dent J.* 1971;130(11):475–82.
15. Hisatomi M, i Asaumi J, Konouchi H, Honda Y, Wakasa T, Kishi K. A case of complex odontoma associated with an impacted lower deciduous second molar and analysis of the 107 odontomas. *Oral Dis.* 2002;8(2):100–5. doi:10.1034/j.1601-0825.2002.1c778.x.

Author biography

Shoborose Tantray, Senior Lecturer

Andleeb Manhas, Senior Resident

Keerti Chauhan, Senior Lecturer

Cite this article: Tantray S, Manhas A, Chauhan K. An eight-year-old boy with large complex odontoma in maxillary anterior area associated with unerupted tooth. *J Oral Med, Oral Surg, Oral Pathol, Oral Radiol* 2021;7(1):74-77.