

Content available at: <https://www.ipinnovative.com/open-access-journals>

Journal of Oral Medicine, Oral Surgery, Oral Pathology and Oral Radiology

Journal homepage: www.joooo.org**Original Research Article****Morphometric analysis of lingual foramen on CBCT: A retrospective radiographic study**Tauseefa Jan^{1,*}, Altaf Hussain Chalkoo¹, Shamshad Begum¹, Nusrat Nazir¹¹Dept. of Oral Medicine and Radiology, Government Dental College Srinagar, Srinagar, Jammu and Kashmir, India**ARTICLE INFO***Article history:*

Received 25-11-2020

Accepted 26-11-2020

Available online 02-12-2020

Keywords:

CBCT

Lingual foramen

Lingual vascular canal

Mandible implant treatment planning

ABSTRACT

Lingual foramen is an opening present commonly on the lingual aspects of mandible and it is commonly a midline structure. It consists of blood vessels that supply the anterior mandible. This study was conducted with aim of analyzing the location, number, radiographic subtypes and relationship of lingual foramen/foramina with the alveolar crest on Cone Beam Computed Tomography. Double lingual foramen is shown in most of the cases followed by single foramen. In our study, all 104(100%) patients showed median and lingual position of lingual foramen. There was significant difference in single lingual foramen between males and females. Type I lingual foramen was most commonly found followed by type VI. CBCT is advanced and most important diagnostic tool in order to reveal morphological features and normal anatomical variations as it further helps in planning an implant or corrective surgical treatment procedure.

© This is an open access article distributed under the terms of the Creative Commons Attribution License (<https://creativecommons.org/licenses/by/4.0/>) which permits unrestricted use, distribution, and reproduction in any medium, provided the original author and source are credited.

1. Introduction

There are numerous foramina present in the mandible, some are most easily anatomically recognizable for example mandibular and mental foramen, but there is some less popular foramen especially on the lingual side of mandible named lingual foramen. The lingual foramen is a small opening situated in the midline on the lingual surface of the anterior mandible at the level of or superior to the genial tubercle.^{1,2}

Radio graphically it is seen as a single round radiolucent canal surrounded by a peripheral well- defined radiopaque border situated in the midline (commonly) below the level of the apices of the mandibular incisors (Figure 1). The radiopacity which surrounds the foramen has been reported to be the genial tubercles. The presence of two or even more such foramina is not uncommon. White (2009) described the contents of superior foramen as a neurovascular bundle, which description implies a nerve, artery and vein whereas the inferior foramen is supplied from the sublingual or

sub mental arteries and mylohyoid nerve.³ Ennis (1937) described that a terminal branch of the inferior alveolar artery as passing through the lingual foramen to anastomose with the lingual artery.⁴

A detail understanding of number, morphological description, dimension of bony canal and dimension of foramen with the alveolar crest superiorly and mandibular border inferiorly is utmost important during anterior mandibular surgery for example implant placement, genioplasty/grafting procedures or ridge augmentation for avoiding various intraoperative and postoperative complications as this foramen can be easily neglected by the clinician. Some of these complications are intraoperative bleeding, nerve injury and neuropraxia of the mandibular incisive nerve.^{5,6}

2. Aim

The aim of this study was to analyze the location, number, radiographical subtypes and relationship of lingual foramen/foramina with the alveolar crest on Cone Beam Computed Tomography.

* Corresponding author.

E-mail address: tauseefa110364@gmail.com (T. Jan).

3. Objectives

These were as follow:

1. Location of lingual foramen.
 - a. Median or Para median (right side or left side)
 - b. Lingual or buccal
 - c. Below the mandibular apices or in between the apices)
2. Number of foramen (single/double/triple/multiple).
3. Classified according to radiographical subtypes.
4. Morphological measurements (vertical distance of the lingual foramina to the alveolar crest of the mandible.)

4. Materials and Methods

This retrospective radiographic study was conducted in the Department of Oral Medicine and Radiology, Government Dental College & Hospital, Srinagar which included 104 patients (58 males and 46 females). The CBCT Scans of 150 patients were collected and analyzed first. Out of them, 104 CBCT scans were included in the study as they fulfill the selection criteria. Cone Beam 3D imaging Newtom Machine with NNT viewer software were used for digital imaging and communications in medicine DICOM imaging system with axial thickness of 0.150 mm, FOV is 8×8cm, tube voltage- 90 Kvp tube current - 9mA, time scan – 63.85 sec. The contrast and brightness of the images were adjusted using the image processing tool in the software to ensure optimal visualization. The axial, coronal, and sagittal planes were created CBCT scans with good quality and resolution, absence of any cyst/tumor/ bone lesions/fracture in the mandible and absence of severe atrophy/completely edentulous lower jaw. They were subjected to various measurements in cognizance with objectives of the study. Median or paramedian location were analyzed on axial and coronal section of CBCT scan, number of lingual foramen were recorded on coronal as well as sagittal section. Radiographic types and morphometric measurement were recorded on sagittal section. Radiographically subtypes of lingual foramen were recorded according to Sekerci AE (2014).⁷ These types are described below:-

Type I: single lingual vascular canal located above the genial tubercle.

Type II: single lingual vascular canal located below genial tubercle.

Type III: single lingual vascular canal at the inferior-most part.

Type IV: single lingual vascular canal at the superior-most part.

Type V: single lingual vascular canal exiting through the labial side of the mandible.

Type VI: two canals (one located above the genial tubercle, other located below genial tubercle), one oriented downwards and another oriented upwards.

Type VII: two canals (intersection of two separate canals; one— oriented downwards—located above the genial tubercle, other—oriented upwards—located below genial tubercle).

Type VIII: cross-section image of canal is a representation of two parallel canals.

Type IX: two canals (intersection of two separate canals; one exiting through the lingual cortical plate and one through the labial).

Type X: two canals located below genial tubercle.

Type XI: three canals (one within or superior to the genial tubercle, one—oriented downwards—located above the genial tubercle and one through the labial).

Type XII: three canals (one—oriented downwards located above the genial tubercle, others located below genial tubercle).

5. Results

Our study included CBCT scans of 104 patients, out of which 58 were males and 46 were females. The age range was 22-75 years. The mediolateral positioning of Lingual foramen on axial/coronal section of all 104 patients (100%) showed median position and out of 104 patients 6 cases (4 males and 2 females) also showed paramedian position as shown in Figure 2. Again buccolingual positioning of Lingual foramen on sagittal section showed that all patients (104/ 100%) exhibit lingual positioning but 4 patients (2 males and 2 females) also showed lingual foramen buccally. All patients exhibit lingual foramen below the apices of mandibular incisors in craniocaudal aspect.

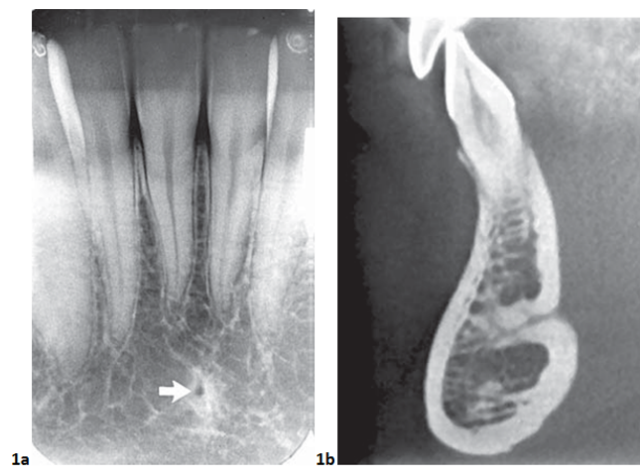


Fig. 1: a: Lingual foramen on an intraoral periapical view (arrow), in the midline of mandible below the lower incisor apices. **b:** Cross-section CBCT image of anterior mandible shows lingual foramen extending deep into mandible from lingual surface

Out of total, 36.54% cases exhibit single lingual foramen, double and triple lingual foramen seen in 57.69% and 5.77% of cases respectively. Males showed more no. of single

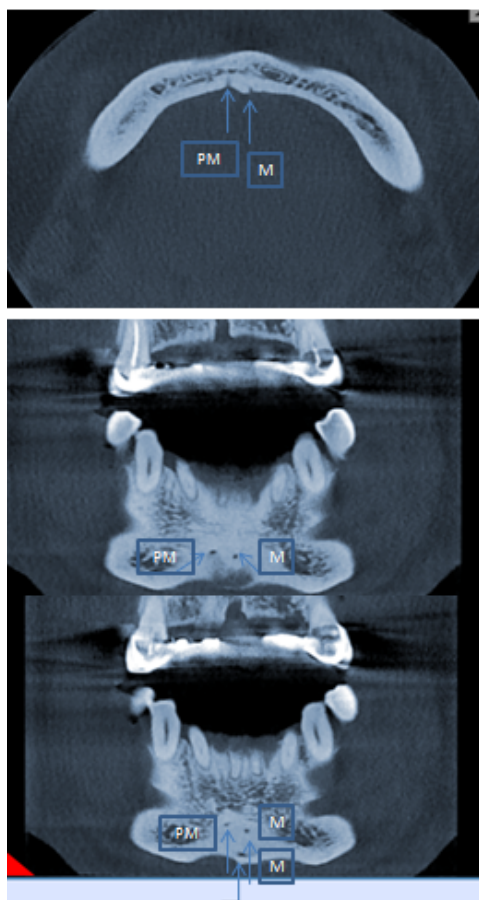


Fig. 2: Median and paramedian lingual foramen in axial and coronal section of CBCT

as well as double lingual foramen than female as shown in Table 2. Triple foramen was recorded more in females than males. But statistically significant difference between gender was seen only in single lingual foramen as given in Table 3.

Out of 12 radiographic types of lingual foramen described by Sekerci AE (2014),⁷ only 10 types were founded in both genders as given in Table 4. Type I lingual foramen was most commonly recorded i.e. 34% of population followed by type VI which is present in 30% of study population. Type VII and type VIII were found in 14% and 10% of study population respectively. Type V and type X was not founded in any of the patient. The mean distance between alveolar crest to lingual foramen were 20.47 ± 4.43 cm with range from 5.2 mm to 26.8 mm.

6. Discussion

A three-dimensional radiographic investigation of anatomical structures depicts detailed morphology of anatomical structures such as bone density, canal morphology and dimensions etc. The knowledge of

morphological variations of lingual vascular canal in terms of number location, types and morphometric distance from the neighboring significant landmarks is very important as it reduces the risk of intra and postoperative complications in implant and corrective surgical procedure.⁸

In our study, all 104(100%) patients showed median and lingual position of lingual foramen. Along with this, 6 cases showed Para median position and 4 patients showed buccally position also. Again in 104 subjects, 38(36.54%), 60(57.69%) and 6 (5.77%) cases exhibit single, double and triple lingual foramen respectively. Double lingual foramen is shown in most of the cases. Study done by Abesi F(2015)⁸ showed Lingual foramen in the median region of the mandible in 100% of the cases and 39.5% had a single foramen, 53% had two foramina and 7.5% showed three foramen Our results also supported by the studies done by Gahleitner et al.,⁹ and Mc Donnell² studies but in contrast Sekerci AE et al. (2014)⁷ single foramen in 48% of the subjects, double foramina in 36.6%, and triple in 10.6%. Studies done by Jacobs R et al. (2007)¹⁰ and Kawai T et al. (2007)¹¹ also recorded single foramen was most frequent.

Assari A et al. (2017)¹² conducted a study in which 23.1%, 38.8% and 26.9% showed single, two and three lingual foramen respectively but there was no significant difference in the pattern of distribution of foramina between males and females. In our study significant difference between genders is seen in single lingual foramen.

In our study type I lingual foramen was most commonly recorded i.e. 34% of population followed by type VI which is present in 30% of study population. The results are in consistent with the study done by Sekerci AE et al. (2014)⁷ in which Type I (32.98%) was the most common variation followed by type VI (26.05%). The mean distance between alveolar crest to lingual foramen were 20.47 ± 4.43 cm. Sekerci AE et al. (2014)⁷ recorded mean distance from alveolar crest to superior lingual foramen was 12.04 ± 3.05 and from alveolar crest to inferior lingual foramen was 24.46 ± 6.36 .⁷ The average distance to the alveolar crest was of 14.2 mm (SD 4.34), with a minimum of 6.2 mm and a maximum of 26.2 mm was recodes by Babiuc I et al. (2011).¹³

Our study was lacking in terms of small sample size and comparison of lingual foramen variation in different age groups. we strongly suggests further more studies in large sample size of population with wide range of age so that more morphological variations can be studied in detail.

7. Conclusion

There is wide range of anatomical variation of lingual vascular canals in respects of number, position, and dimension. It is important to consider these features during preoperative planning for surgery particularly implant placement in the anterior mandible as it may lead to uncontrolled hemorrhage intraosseously or in soft

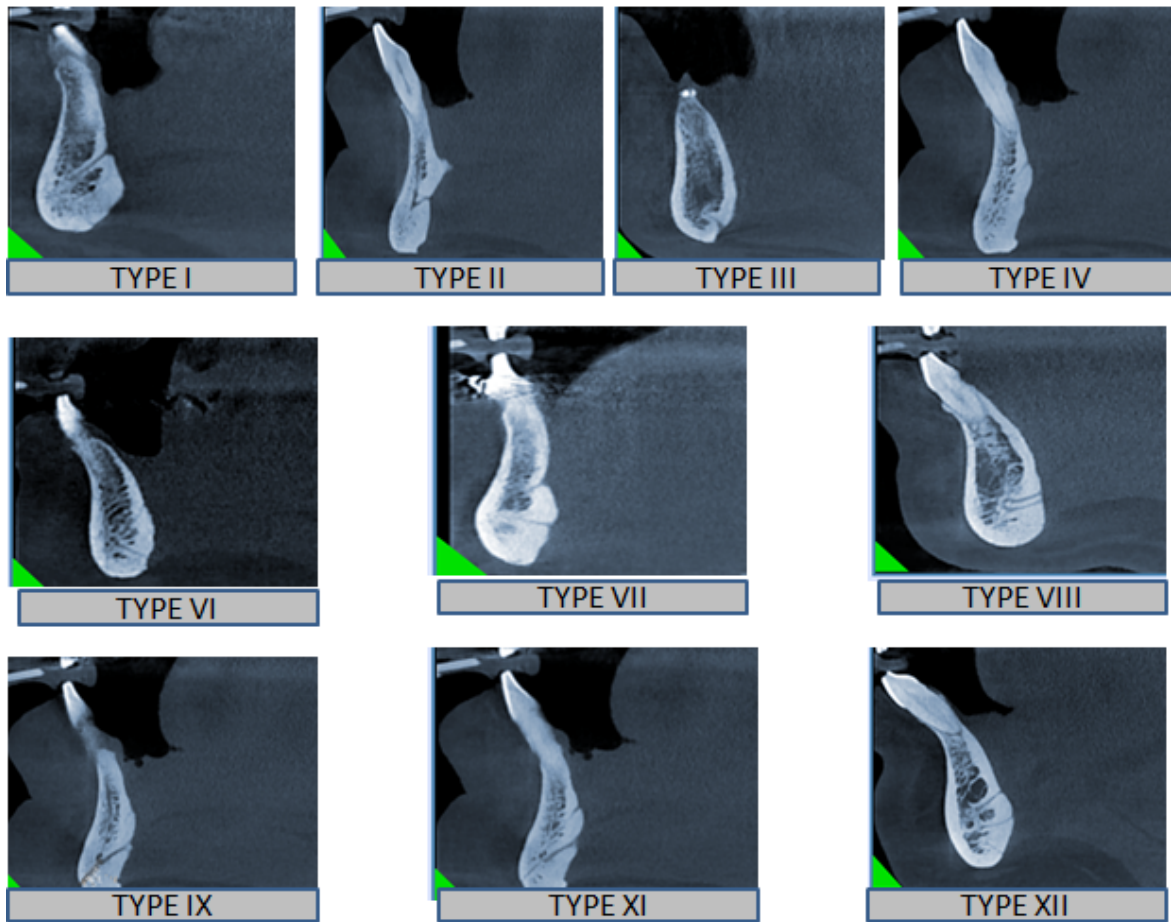


Fig. 3: Radiographic types of lingual foramen recorded in study sample

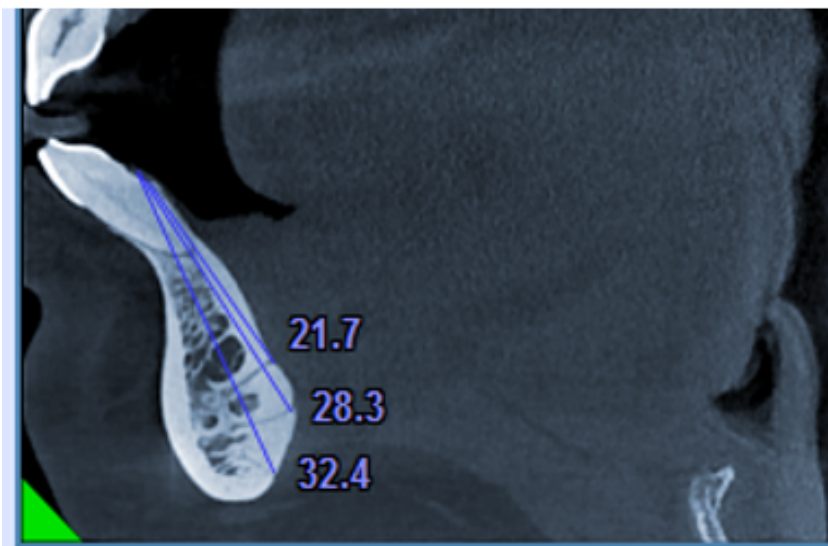


Fig. 4: Morphometric measurements from alveolar crest to opening of lingual foramen lingually

Table 1:

Gender	No.	Median	Paramedian	Buccal	Lingual	Below the apices	Between the apices
Males	58	58	4	2	58	58	0
Females	46	46	2	2	46	46	0
Total	104	104	6	4	104	104	0

Table 2:

Gender	Single	Double	Triple	Total
Males	24 (41.38%)	32(55.17%)	2(3.45%)	58(100%)
Females	14(30.43%)	28(60.87%)	4(8.69%)	46(100%)
Total	38(36.54%)	60(57.69%)	6(5.77%)	104(100%)

Table 3:

No. of foramen	χ^2	p-value
Single	5.5	0.02*
Double	0.32	>0.2
Triple	1.2	0.2

Table 4:

Type of lingual foramen	Males	Females	Total
Type I	24 (23%)	12 (11%)	36 (34%)
Type II	2 (1.9%)	0	2(1.9%)
Type III	1 (.9%)	1 (.9%)	2 (1.8%)
Type IV	0	2 (1.9%)	2(1.9%)
Type V	0	0	0
Type VI	12 (11%)	18 (17%)	30 (29%)
Type VII	12 (11%)	2 (1.9%)	14 (12.9%)
Type VIII	6 (5.8%)	4 (3.8%)	10 (9.6%)
Type IX	2 (1.9%)	0	2(1.9%)
Type X	0	0	0
Type XI	0	2 (1.9%)	2(1.9%)
Type XXI	1(.9%)	3 (2.9%)	4 (3.8%)

tissue. CBCT is a three-dimensional radiographic imaging modality with greatly reduced doses of radiation and high accuracy and is recently becoming a routine diagnostic tool in implant planning.

8. Source of Funding

None.

9. Conflict of Interest

The authors declare that there is no conflict of interest

References

- Mraiwa N, Jacobs R, Moerman P, Lambrichts I, van Steenberghe D, Quirynen M. Presence and course of the incisive canal in the human mandibular interforaminal region: two-dimensional imaging versus anatomical observations. *Surg Radiol Anat.* 2003;25(5-6):416–23. doi:10.1007/s00276-003-0152-8.
- McDonnell D, Nouri MR, Todd ME. The mandibular lingual foramen: a consistent arterial foramen in the middle of the mandible. *J Anat.* 1994;184(2):363–9.
- White SC, Pharoah MJ. *Oral Radiology; Principles and Interpretation.* 6th ed. St. Louis, Missouri: Mosby Elsevier; 2009.
- Ennis LM. Roentgenographic variations of the maxillary sinus and the nutrient canals of the maxilla and the mandible. *Int J Orthod Oral Surg.* 1937;23(2):173–93. doi:10.1016/s1072-3498(37)80010-2.
- Dreiseidler T, Mischkowski RA, Neugebauer J, Ritter L, Zöllner JE. Comparison of cone-beam imaging with orthopantomography and computerized tomography for assessment in presurgical implant dentistry. *Int J Oral Maxillofac Implants.* 2009;24(2):216–25.
- Rosano G, Taschieri S, Gaudy JF, Testori T, Fabbro MD. Anatomic assessment of the anterior mandible and relative hemorrhage risk in implant dentistry: a cadaveric study. *Clin Oral Implants Res.* 2009;20(8):791–5. doi:10.1111/j.1600-0501.2009.01713.x.
- Sekerci AE, Sisman Y, Payveren MA. Evaluation of location and dimensions of mandibular lingual foramina using cone-beam computed tomography. *Surg Radiol Anat.* 2014;36:857–64. doi:10.1007/s00276-014-1311-9.
- Scaravilli MS, Mariniello M, Sammartino G. Mandibular lingual vascular canals (MLVC): Evaluation on dental CTs of a case series. *Eur J Radiol.* 2010;76(2):173–6. doi:10.1016/j.ejrad.2009.06.002.
- Gahleitner A, Hofschneider U, Tepper G, Pretterklieber M, Schick S, Zauza K, et al. Lingual Vascular Canals of the Mandible: Evaluation with Dental CT. *Radiol.* 2001;220(1):186–9. doi:10.1148/radiology.220.1.r01j105186.
- Liang X, Jacobs R, Lambrichts I, Vandewalle G. Lingual foramina on the mandibular midline revisited: A macroanatomical study. *Clin Anat.* 2007;20(3):246–51. doi:10.1002/ca.20357.

11. Kawai T, Asami R, Sato I, Yoshida S, Yosue T. Classification of the lingual foramina and their bony canals in the median region of the mandible: cone beam computed tomography observations of dry Japanese mandibles. *Oral Radiol.* 2007;23(2):42–8. doi:10.1007/s11282-007-0064-0.
12. Assari A, Almashat H, Alamry A, Algarni B. Prevalence and location of the anterior lingual foramen: A cone-beam computed tomography assessment. *Saudi J Oral Sci.* 2017;4(1):41. doi:10.4103/sjos.sjoralsci_56_16.
13. Babiuc I, Tărlungeanu I, Păuna M. Cone beam computed tomography observations of the lingual foramina and their bony canals in the median region of the mandible. *Rom J Morphol Embryol.* 2011;52(3):827–9.

Author biography

Tauseefa Jan, PG Student

Altaf Hussain Chalkoo, Professor and HOD

Shamshad Begum, Senior Resident

Nusrat Nazir, Senior Resident

Cite this article: Jan T, Hussain Chalkoo A, Begum S, Nazir N. Morphometric analysis of lingual foramen on CBCT: A retrospective radiographic study. *J Oral Med, Oral Surg, Oral Pathol, Oral Radiol* 2020;6(4):193-198.