

Content available at: <https://www.ipinnovative.com/open-access-journals>

Journal of Oral Medicine, Oral Surgery, Oral Pathology and Oral Radiology

Journal homepage: [www.joooo.org](http://www.joooo.org)

## Original Research Article

## Evaluation of the preauricular transmasstetric anterior parotid approach in the open reduction and internal fixation of condylar fractures

Shreyas Orvakonde<sup>1,\*</sup>, Bidyalaxmi Mutum<sup>2</sup><sup>1</sup>Dept. of Dentistry, Chamarajanagar Institute of Medical Sciences, Yadapura, Karnataka, India<sup>2</sup>Private Practitioner, Mysore, Karnataka, India

## ARTICLE INFO

## Article history:

Received 16-11-2020

Accepted 19-11-2020

Available online 02-12-2020

## Keywords:

Condylar fractures

Open reduction internal fixation

Preauricular

Transmasstetric anterior parotid

## ABSTRACT

Numerous approaches have been described to access the fractured condyle. Unrestricted wide optical window to the fracture site and the safety of the facial nerve dictate the type of approach required.

**Aims:** To evaluate the pre auricular transmasstetric anterior parotid approach in 20 unilateral condylar fractures.

**Results:** All the twenty cases evaluated showed adequate mouth opening, no signs of facial nerve palsy and sialoceles.

The transmasstetric anterior parotid approach is a safe approach which can be used in the surgical management of condylar fractures and is of special value in obtaining excellent exposure in the cases of medially displaced condylar neck fractures.

© This is an open access article distributed under the terms of the Creative Commons Attribution License (<https://creativecommons.org/licenses/by/4.0/>) which permits unrestricted use, distribution, and reproduction in any medium, provided the original author and source are credited.

### 1. Introduction

Condylar fractures are frequently encountered by the maxillofacial surgeon. They occur as a solitary fracture or in conjugation with other mandibular and facial fractures. Condylar fractures form roughly 25-50% of all mandibular fractures.<sup>1,2</sup> Open reduction and internal fixation is the preferred method of treating these fractures in order to obtain good functional outcomes. Most importantly ORIF achieves immediate return to function and mitigates the nutritional disparity that occurs due to prolonged periods of IMF.

Various approaches such as the pre auricular, submandibular, rhytidectomy and retro mandibular have been utilized in order to approach the fractured condyle. Integrity and safety of the facial nerve and adequate exposure are key requisites in choosing the approach. The retromandibular<sup>3</sup> approach combined with the transparotid approach provides direct exposure to the fracture site. Even though a simple approach it has its shortcomings in

terms of providing adequate exposure to higher levels such as the condylar neck and head fractures. This approach has also been associated with facial palsy.<sup>4</sup> Although temporary, many patients may not be fully accepting of this complication.

Medially displaced condylar fractures require more retraction and the chances of neuropraxia are high in such cases.<sup>5</sup> We thus aimed to evaluate the preauricular transmasstetric anterior parotid approach.

### 2. Materials and Methods

Twenty patients with unilateral condylar fractures, 13 subcondylar and 7 condylar neck fractures were included in the study. Bilateral condylar fractures were excluded from the study. Pertinent consent including ethical clearance was obtained.

Average operating time from skin incision to closure was noted. Facial nerve function was evaluated using the tests mentioned (Table 1). Facial nerve function was evaluated 24 hrs post surgery and at a period of 1, 2 and 6 weeks subsequently.

\* Corresponding author.

E-mail address: [drshre890@gmail.com](mailto:drshre890@gmail.com) (S. Orvakonde).

Mouth opening was evaluated 24 hrs post surgery and at a period of 1, 2 and 6 weeks post surgery.

**Table 1:** Tests patient asked to perform to evaluate facial nerve function

Expression/movement	Branch assessed
Elevate and wrinkle forehead	Temporal branch
Closure of eyes	Zygomatic branch
Whistle, puff cheeks, blow cheeks	Buccal branch
Evert lower lip, move lower lip	Marginal mandibularis

### 2.1. Surgical technique

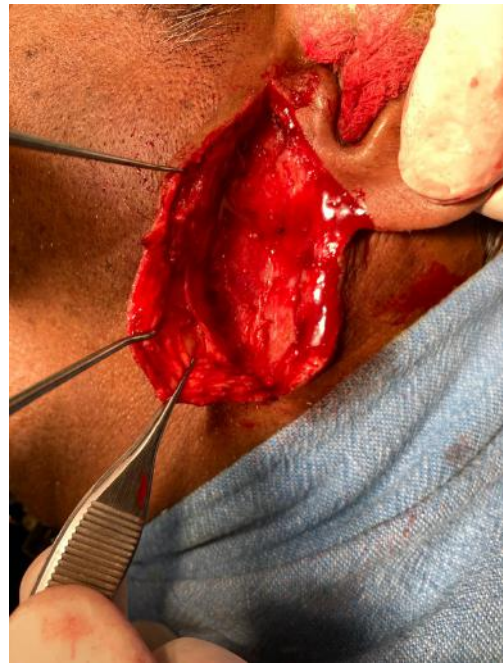The incision was devised to have two parts a preauricular portion and a retromandibular extension curving beneath the ear lobe and extending inferiorly paralleling the posterior border of the mandible. The retromandibular limb was around 2-3 cms. The dissection of the retromandibular limb is initiated first and a flap is raised in the subdermal plan anteriorly. A wide plane of dissection is done in this plane to facilitate retraction (Figure 1). This wide plane also allows easy identification of the parotid and masseter junction overlapped by the parotidomasseteric fascia. Prior to dissection through this plane, the preauricular incision is deepened only up to the subdermal area and the two limbs are connected. Once the junction of the parotid and masseter is identified (Figure 2) the masseter is approached in a blunt manner anterior to the gland. The gland is then retracted posteriorly exposing the masseter. The muscle is then incised up to bone after palpating the mandible. Sub periosteal dissection is then carried out to expose the mandible (Figure 3) the fracture was then identified and reduced. Fixation was achieved using titanium 2.0 mm 4 hole plate with 2mm screws (6 mm length)-Figure 4. Layered closure was done using 4-0 vicryl and skin using 5-0 prolene.

### 3. Results

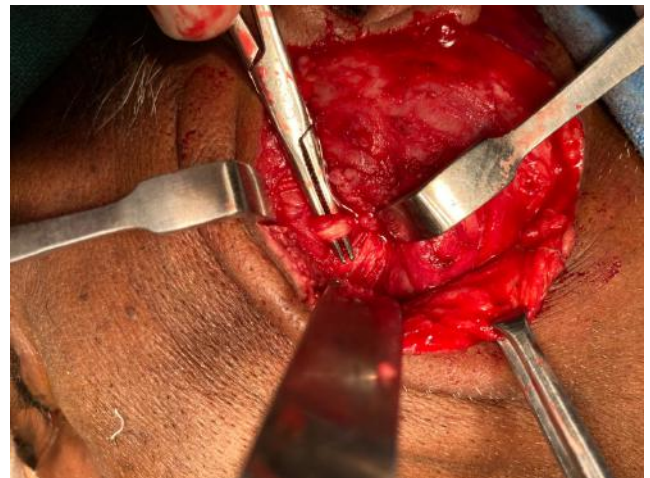
All 20 patients were evaluated and no patient was lost to follow up. All the cases were operated by a single surgeon. The average time for the fixation of all the sub condylar fractures from skin incision to closure was 60 mins. The medially displaced condylar neck fractures took slightly more time owing to the increased manipulation in order to retrieve the medially displaced fragment. The average time was 90 mins in these cases.

Mouth opening was normal in 17 cases post surgery. 3 cases developed mild trismus which resolved after 2 weeks.

Facial nerve function was evaluated 24 hrs post surgery and at period of 1, 2 and 6 weeks. Facial nerve function was normal in all patients and no deficit was noted. No patients reported with sialocele post surgery.



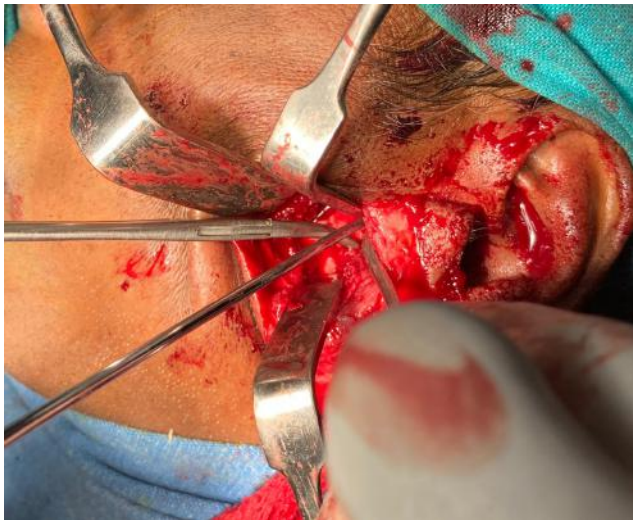**Fig. 1:**



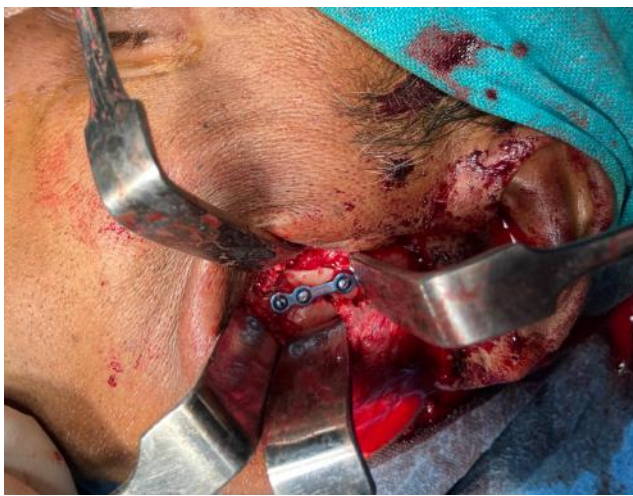**Fig. 2:**

### 4. Discussion

ORIF of the condyle remains the best form of treatment for condylar fractures and consistently provides superior results in terms of function and occlusal stability. A vast array of approaches have been described to approach the mandibular condyle. The pre auricular approach offers exposure to the condylar head and neck region, it is more suitable for intracapsular and condylar head procedures. It is extremely difficult to apply screws in a perpendicular fashion with this approach and there is always the risk of injury to the temporal and zygomatic branches. According to Hammer et al. and tang et al. the incidence of damage to



**Fig. 3:**



**Fig. 4:**

the facial nerve after the preauricular approach ranged from 3.2% to 42.9%.<sup>6,7</sup> Ellis et al.,<sup>8</sup> Iizuka et al.,<sup>9</sup> Chossegros et al.<sup>10</sup> have all reported temporary atony of the facial nerve after the retromandibular approach. Our study clearly demonstrated that the Preauricular transmasseteric approach is a safe approach and protects the branches of the facial nerve from temporary and permanent neural deficit. The safe window of surgical space available between the buccal and marginal branches is made use of to safely approach the mandible. This window increases as we move more anteriorly. The available surgical window is better compared to all the approaches thus resulting in less retraction.

The retromandibular transparotid approach violates the parotid fascia and can result in sialocele/parotid fistula. This approach clearly identifies the anterior border of the parotid

and dissection is anterior to it and completely negates the problem of post-operative sialocele.

From our study we can conclude that the preauricular transmasseteric anteroparotid approach is a safe and viable approach in the treatment of condylar fractures.

## 5. Source of Funding

None.

## 6. Conflict of Interest

The author(s) declare(s) that there is no conflict of interest regarding the publication of this article.

## References

1. Rowe NL, Killey HC. Fractures of the facial skeleton. 2nd ed. Edinburgh: Churchill Livingstone; 1968.
2. Silvennoinen U, Iizuka T, Lindqvist C, Oikarinen K. Different patterns of condylar fractures: An analysis of 382 patients in a 3-year period. *J Oral Maxillofac Surg.* 1992;50(10):1032–7. doi:10.1016/0278-2391(92)90484-h.
3. Hinds EC, Girotti WJ. Vertical subcondylar osteotomy: A reappraisal. *Oral Surg, Oral Med, Oral Pathol.* 1967;24(2):164–70. doi:10.1016/0030-4220(67)90256-3.
4. Downie JJ, Devlin MF, Carton ATM, Hislop WS. Prospective study of morbidity associated with open reduction and internal fixation of the fractured condyle by the transparotid approach. *Br J Oral Maxillofac Surg.* 2009;47(5):370–3. doi:10.1016/j.bjoms.2008.11.002.
5. Wilsona AW, Ethunandana M, Brennan PA. Transmasseteric anteroparotid approach for open reduction and internal fixation of condylar fractures A. *Br J Oral Maxillofac Surg.* 2005;43(1):57–60.
6. Hammer B, Schier P, Prein J. Osteosynthesis of condylar neck fractures: a review of 30 patients. *Br J Oral Maxillofac Surg.* 1997;35(4):288–91. doi:10.1016/s0266-4356(97)90050-4.
7. Tang W, Gao C, Long J, Lin Y, Wang H, Liu L. Application of modified retromandibular approach indirectly from the anterior edge of the parotid gland in the surgical treatment of condylar fractures. *J Oral Maxillofac Surg.* 2009;67:552–60.
8. Ellisiii E, Mcfadden D, Simon P. Surgical complications with open treatment of mandibular condylar process fractures. *J Oral Maxillofac Surg.* 2000;58:950–8.
9. Iizuka T, Lindqvist C, Hallikainen D, Mikkonen P, Pauku P. Severe bone resorption and osteoarthritis after miniplate fixation of high condylar fractures. *Oral Surg, Oral Med, Oral Pathol.* 1991;72(4):400–7. doi:10.1016/0030-4220(91)90547-p.
10. Chossegros C, Cheynet F, Blanc JL, Bourezak Z. Short retromandibular approach of subcondylar fractures. *Oral Surg, Oral Med, Oral Pathol, Oral Radiol, Endodontol.* 1996;82(3):248–52. doi:10.1016/s1079-2104(96)80347-7.

## Author biography

**Shreyas Orvakonde**, Resident

**Bidyalaxmi Mutum**, Private Practitioner

**Cite this article:** Orvakonde S, Mutum B. Evaluation of the preauricular transmasseteric anterior parotid approach in the open reduction and internal fixation of condylar fractures. *J Oral Med, Oral Surg, Oral Pathol, Oral Radiol* 2020;6(4):190-192.