



Case Report

Osteosarcoma of mandible in a teenager - A case report with review of literature

Pragati Upasham¹, Pinky Gupta^{1,*}, Ajinkya Bangar¹

¹Dept. of Pathology, D Y Patil School of Medicine, Navi Mumbai, Maharashtra, India



ARTICLE INFO

Article history:

Received 24-05-2020

Accepted 30-06-2020

Available online 03-10-2020

Keywords:

Bone malignant tumour

Histopathology

Jaw osteosarcoma

Mandible

Osteoblastic

ABSTRACT

Osteosarcomas are highly malignant bone tumours characterised by the presence of malignant mesenchymal cells producing osteoid or immature bone. Though rapidly growing bones are commonly affected like metaphysis in the femur, rare cases of Osteosarcoma of jaw (JOS) too occur; with an incidence of approximately 0.7 per million. The diagnosis involves clinico-radiological and histological correlation. A 14-year old male presented with the chief complaints of swelling and pain in his lower jaw on left side for 15 days and was given a provisional diagnosis of neoplasia of left body of mandible on radiography which was confirmed as osteosarcoma in histopathology.

The case presented here highlight the importance of histopathology in diagnosing the lesion. Considering its rarity we present the case and attempt to review the literature associated with this lesion. Osteosarcoma especially of jaw requires a high degree of suspicion and need to be diagnosed and treated promptly to prevent further complications as rapidly growing tumour could predispose to bony outgrowth, facial deformity, airway compromise and metastasis.

Key message: Jaw osteosarcoma is a rare entity requiring clinico-radiological and histopathological correlation for early diagnosis. With a clinically distinct profile as compared to its extremity counterpart, early histomorphological diagnosis and management with surgery, chemotherapy and radiotherapy can lead to better outcome.

© 2020 Published by Innovative Publication. This is an open access article under the CC BY-NC license (<https://creativecommons.org/licenses/by-nc/4.0/>)

1. Introduction

Osteosarcomas are primary malignant bone tumours that involve production of osteoid or immature bone by the malignant cells.¹ It is the most common non hematopoietic primary malignant tumor of bone; around 6-10 percent of total cases arise in the head and neck region.² In most series, jaw is the most common site with incidence of 0.7/million and approximately equal distribution between the mandible and the maxilla.²⁻⁴ There is a slight male predominance ranging from 1.1:1 to 1.75:1.^{3,4} The typical patient presents with a mass or swelling in the cheek or jaw, sometimes with pain, and occasionally with dental complaints.^{1,5} Head and neck osteosarcoma usually have lower potential to metastasize.^{1,3,5} It may have both chondroblastic or osteoblastic pattern.^{1,3} To the database

of these rare tumours, we are adding the present case of Osteosarcoma of jaw.

2. Case Presentation

A 14-year old male patient came to the medicine OPD with the chief complaints of swelling and pain in his lower left jaw for 15 days. The pain was severe, pricking and continuous in nature without any diurnal variation and with minimal response to analgesic and was associated with gradually increasing swelling. The patient also experienced difficulty in chewing food on that side. There was no history of fever, weight loss and night sweats.

Radiography was done which on Panoramic view showed a lesion along the left body of the mandible, with irregular osteolytic areas. Cross-sectional radiograph depicted bicortical expansion and radial spicules extending outside the jaw bone, giving a “sunray appearance”

* Corresponding author.

E-mail address: pinky.gpt5@gmail.com (P. Gupta).

which was classical of osteosarcoma. The submitted biopsy showed the histopathological features suggestive of osteosarcoma of body of the mandible. Based on this, left hemi-mandibulectomy was done.

The specimen consisted of the left sided mandible with a 3cm x 2cm x 1.5cm in size, ill-defined mass, brown in colour, at the lower one-third of the left side of the face, which extended, supero-inferiorly, three cm from the left zygoma to three cm above the inferior mandibular border and anteroposteriorly, four cm from the angle of the mouth to three cm from the angle of the mandible.(Figure 1)

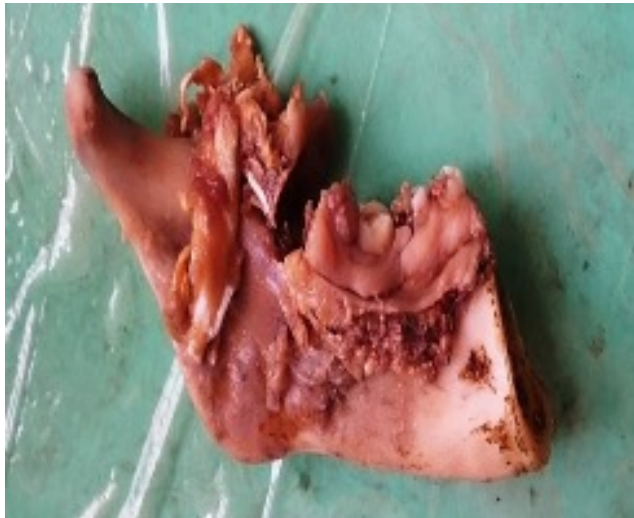

Fig. 1: Gross specimen of left hemomandibulectomy with ill defined tumor mass

On microscopy, section studied showed a malignant tumor with the tumor cells being arranged in diffuse pattern and at places, pseudo-papillary pattern was seen. Individual tumor cells were pleomorphic, predominantly small, round to oval with hyperchromatic nuclei and scant amount of eosinophilic cytoplasm. Malignant osteoid formation was seen in few places(Figures 2 and 3). Surgical margins were free of tumor. Based on histopathology, the final diagnosis given was low grade osteoblastic osteosarcoma with the staging as T1N0M0, corresponding to stage 1A.

3. Discussion

Osteosarcoma (OS) of the head and neck although noted in all groups however higher incidence is in third and fourth decade which is at least 10 years older than patients with non-head and neck osteosarcomas⁵ with slight male predominance.³⁻⁵ It most commonly arises in the jaw either in mandible or maxilla.^{3,4} In one small series of paediatric jaw osteosarcoma median age at time of diagnosis was 16.3 years (range, 6.3–21.9 years). Seventy five percent patients had tumors involving the mandible, rest being maxilla.⁶

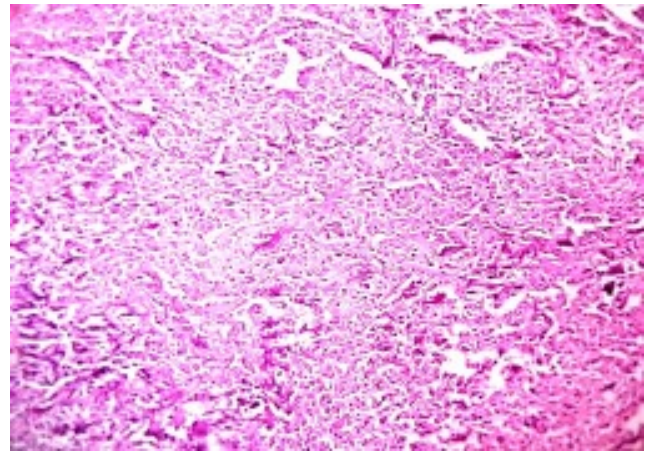


Fig. 2: Osteoblastic osteosarcoma.(H&E 10X) Showing Tumour cells arranged in diffuse pattern

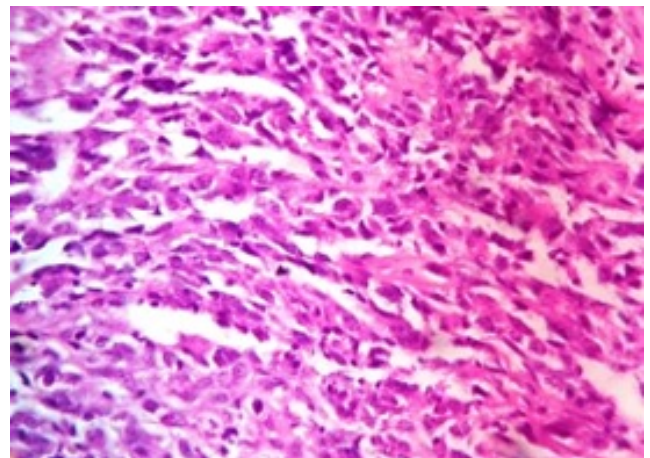


Fig. 3: Osteoblastic osteosarcoma.(H&E 40X) Showing malignant cells with osteoid formation at places

The typical patient presents with a mass or swelling in the cheek or jaw, sometimes with pain, and occasionally with dental complaints.^{1,5} Our patient, a teenager had similar clinical features.

There are few identified predisposing factors like prior irradiation, fibrous dysplasia, pagets disease, along with genetically predisposing conditions like hereditary retinoblastoma, Li Fraumeni syndrome and Rothmund-Thomson syndrome.⁵ No such correlation could be done in this case.

An accurate diagnosis, usually require clinico radiological correlation facilitated by CT(computed tomography), MRI(magnetic resonance imaging) and biopsy, in order to define the disease stage and plan further management.² Radiograph shows osseous destruction with either lytic, sclerotic, or mixed component, and indistinct margins. The periodontal ligament space and inferior dental canal widening, along with sunburst effect are almost

characteristic of OS of the jaw bone, but not all lesions may show these features.³ In the present case requisition form revealed the same finding but we could not retrieve the radiological plate of our patient.

The recognition of osteoid production by tumour cells is prerequisite for diagnosis of osteosarcoma.³ Osteosarcomas are categorized histologically into osteoblastic, chondroblastic, fibroblastic subtypes depending upon the predominant extracellular matrix.³ Other uncommon histologic variants are telangiectatic, myxomatous, fibrous histiocytoma-like, epithelioid, small-cell, large-cell and giant-cell OS.⁷

Most series of Jaw osteosarcoma report predominantly chondroblastic differentiation subtype.³ But, there is no consensus regarding the main differentiation patterns (osteoblastic and chondroblastic), and more regularly it display a more heterogeneous histotype.⁸ In our case, the histomorphology was suggestive of osteoblastic variant.

Jaw osteosarcoma are classified into central (intramedullary) & peripheral (surface subtype). Peripheral tumors further categorized into parosteal, periosteal and high grade surface osteosarcoma. Parosteal (or juxtacortical) osteosarcoma which represent upto 5% of all osteosarcomas are rare tumor, involving the jaw. It is well differentiated and comprises of spindle cell with minimal atypia and rare mitotic figures parting irregular trabeculae of woven bone, arranged in a parallel manner. In due course, the trabeculae often coalesce forming a large solid bone mass.⁴ The case presented here belonged to the group of conventional central osteosarcoma.

The grade is divided into low grade (G1) and high grade (G2).³ Immunohistochemistry (IHC) helps in the differentiating chondrosarcoma from chondroblastic osteosarcoma. Chondrosarcoma shows positivity for S100 and Vimentin while it is negative for cytokeratin and EMA (Epithelial Membrane Antigen). Galactin-1 was further seen to be largely expressed in osteosarcoma but not in chondrosarcoma with a positive predictive value of 85.7%.⁹ Chondroblastic osteosarcoma on the other hand is positive for Vimentin, EMA, S100 and rarely cytokeratin. Further detection of MDM2 and CDK4 is a useful diagnostic tool in separating low grade osteosarcoma from benign lesion. The expression of IDH1 in formalin fixed paraffin tissue correlated with p53 and thus may serve as a candidate biomarker for osteosarcoma.³ IHC couldn't be done in our case and the patient was referred to specialised centre for further management, hence he was lost to further follow up.

Distant metastasis as compared to local recurrence are less common in jaw osteosarcomas.^{5,6} Generally, prognosis of jaw osteosarcomas is better than that of long bone osteosarcomas. This may be due to the histologically better differentiation of jaw osteosarcomas than that of long bone osteosarcomas.¹⁰

The treatment of osteosarcomas incorporates a multimodality approach in form of surgery plus neoadjuvant

or adjuvant chemotherapy and adjuvant radiotherapy.^{6,9} Surgical accessibility plays a significant role in outcome of head and neck osteosarcomas as patients who are able to undergo complete or wide excision have a better prognosis. As an example, patients with mandibular tumors have better survival than those with disease in other maxillary & craniofacial bones.^{5,6}

4. Conclusion

OS of the jaw has a clinically distinct profile from that of the long bones. It exhibit a mean age of occurrence one decade later than long bones osteosarcomas. The prognosis for osteosarcoma arising in jaw is better than those arising in long bone, however it too have an aggressive presentation that must be suspected and diagnosed promptly.

Thus in conclusion we state that histopathological study contributes significantly in the diagnosis & ultimately predicting prognosis in jaw osteosarcoma. Early histomorphological diagnosis and management with surgery, chemotherapy and radiotherapy will achieve better outcome in this lesion.

5. Source of Funding

None.

6. Conflict of Interest

None.

References

1. Samraj L, Kaliamoorthy S, Venkatapathy R, Oza N. Osteosarcoma of the mandible: A case report with an early radiographic manifestation. *Imaging Sci Dent.* 2014;44(1):85.
2. Gupta S, Parikh S, Goel S. Parosteal osteosarcoma of mandible: A rare case report. *J Can Res Ther.* 2018;14:471–4.
3. Chaudhary M, Chaudhary SD. Osteosarcoma of jaws. *J Oral Maxillofac Pathol.* 2012;16(2):233–8.
4. Puranik SR, Puranik RS, Ramdurg PK, Choudhary GRC. Parosteal osteosarcoma: Report of a rare juxtacortical variant of osteosarcoma affecting the maxilla. *J Oral Maxillofac Pathol.* 2014;18(3):432–6.
5. Patel SG, Meyers P, Huvos AG, Wolden S, Singh B, Shaha AR, et al. Improved outcomes in patients with osteogenic sarcoma of the head and neck. *Cancer.* 2002;95(7):1495–1503.
6. Huh WW, Holsinger FC, Levy A, Palla FSL, Anderson PM. Osteosarcoma of the jaw in children and young adults. *Head Neck.* 2012;34(7):981–4.
7. Angiero F, Moltrasio F, Cattoretti G. Clinical and histopathological profile of primary or secondary osteosarcoma of the jaws. *Anticancer Res.* 2011;31:4485–9.
8. Nissanka EH, Amaratunge E, Tilakarathne WM. Clinicopathological analysis of osteosarcoma of jaw bones. *Oral Dis.* 2007;13(1):82–7.
9. ElKordy MA, ElBaradie TS, ElSebai HI, Amin AAE, Alla SMK. Osteosarcoma of the jaw: Challenges in the diagnosis and treatment. *J Egypt Natl Canc Inst.* 2018;30(1):7–11.
10. Agrawal RR, Bhavthankar JD, Mandale MS, Patil PP. Osteosarcoma of Jaw with Varying Histomorphologic Patterns: Case Report. *J Orthop Case Rep.* 2017;7(1):61–4.

Author biography

Pragati Upasham Professor

Pinky Gupta Junior Resident

Ajinkya Bangar Junior Resident

Cite this article: Upasham P, Gupta P, Bangar A. Osteosarcoma of mandible in a teenager - A case report with review of literature. *J Oral Med, Oral Surg, Oral Pathol, Oral Radiol* 2020;6(3):146-149.