



Case Report

Head and neck soft tissue fibrosarcoma in nine year old child: A case report

Vishal Bamniya¹, Ajay Pratap Singh Parihar^{1,*}, Arvind Jain², Ashish Saxena³, Sheetal Singar¹, Abhishek Maurya¹

¹Dept. of Oral Medicine and Radiology, Government College of Dentistry, Indore, Madhya Pradesh, India

²Dept. of Conservative Dentistry and Endodontics, Government College of Dentistry, Indore, Madhya Pradesh, India

³Dept. of Pedodontics and Preventive Dentistry, Government College of Dentistry, Indore, Madhya Pradesh, India



ARTICLE INFO

Article history:

Received 09-05-2020

Accepted 16-06-2020

Available online 18-07-2020

Keywords:

Fibrosarcoma

ABSTRACT

Fibrosarcoma is a mesenchymal cell origin tumor composed of malignant fibroblast. This condition affects primarily to long bones, and rarely occurs in cranium about, with the maxilla being the most rarest cranial site. This paper describes a rare case of 9 year old baby girl who presented with swelling on the left side of face diagnosed as soft tissue fibrosarcoma of the intraoral region. The histopathologically confirmed the diagnosis by the presence of spindle-shaped cells arranged in fascicles with mitotic figures and cellular proliferation reproducing fibroblasts.

© 2020 Published by Innovative Publication. This is an open access article under the CC BY-NC license (<https://creativecommons.org/licenses/by-nc/4.0/>)

1. Introduction

Sarcomas are malignant neoplasm arising in 'solid' mesenchymal tissues.¹ Soft tissue sarcomas of oral cavity are rare and account approximately 1% of all malignancies.² Sarcoma includes subtypes such as fibrosarcoma (FS) which is a cancer of fibrous tissue origin.^{1,2} FS is a condition which primarily affect long bones and rarely occurs in cranium with mandible being most common cranial site with greatest number of these occurring in premolar and molar region.^{3,4} FS typically occurs relatively in younger persons which differs it from malignant epithelial neoplasms.³ FS also defined by World Health Organization 2013 as a malignancy composed of 'herringbone' architecture fibroblasts.⁵

2. Case Report

A 9-year-old girl was referred to the own department with the chief complaint of swelling over the left side of the face with a hard, slightly painful, well-circumscribed swelling (4.5 × 4 × 3.5 cm) which was noticed by the

parents 15 days before first presentation. There was no ulceration of the overlying mucosa. Skin over the swelling was normal in colour. The swelling was firm and fixed to underlying structures. Mouth-opening was reduced to 32 mm due to pain. Paraesthesia was evident in the right upper lip. There was associated history of difficulty in speech and mastication. Intraorally, the swelling appeared to be arising from the labial vestibule extending up to the first molar of the left side. There was no displacement and mobility seen with respected teeth.

3. Discussion

Soft tissue sarcomas of the oral cavity account for approximately 1% of all oral malignancies which is very rare and includes subtypes such as fibrosarcoma, malignant fibrous histiocytoma, liposarcoma, rhabdomyosarcoma, leiomyosarcoma, angiosarcoma, and alveolar soft part sarcoma. Soft tissue sarcoma may involve any part of oral cavity which is usually presents as a slow- or rapid-growing swelling of the mucosa.² Fibrosarcoma is a neoplasm composed of malignant fibroblasts that produce collagen and elastin. Occurs equally in male and females.⁴ Most

* Corresponding author.

E-mail address: ajaycbct@gmail.com (A. P. S. Parihar).

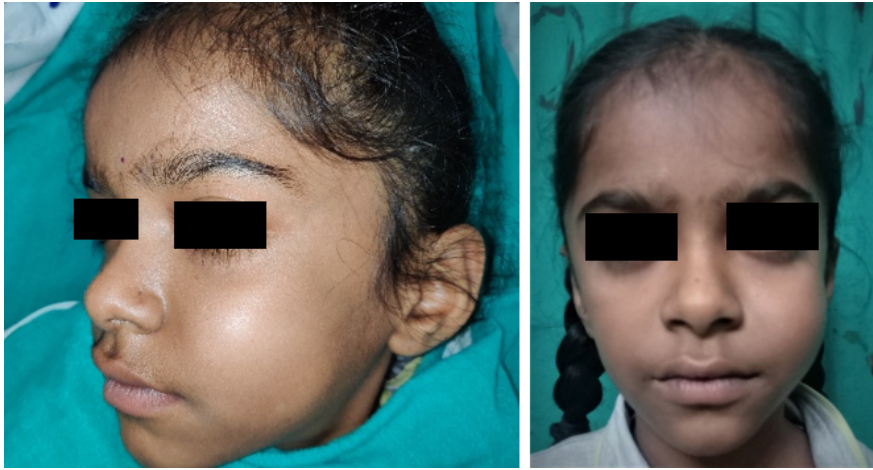

Fig. 1: Swelling in left side of zygomatic region of size 4.5x3.5 cm, extended superiorly from infraorbital margin to just above corner of upper lip which was round to oval in shape with well defined borders overlying skin was normal in color which was firm and fixed to underlying structures and tender on palpation

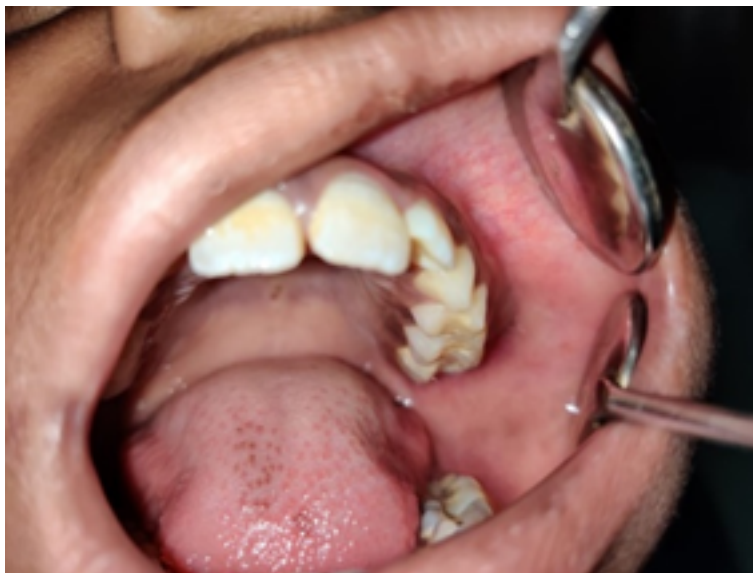

Fig. 2: Intraoral swelling appeared to be arising from buccal vestibule extending up to 1st molar overlying mucosa appears normal in color and on palpation swelling was firm in consistency and tender on palpation

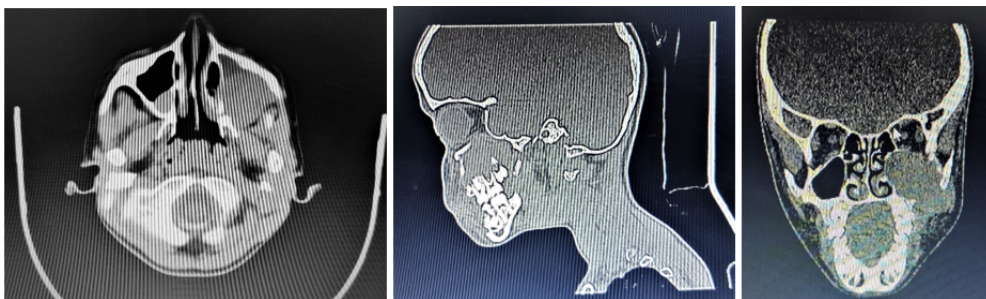


Fig. 3: Heterogeneous hypodense mass of approx size 3.9x2.5 cm is demonstrated in coronal plain CT, showing a rather sharp margin with cortical destruction involving left maxilla with some osteolytic lesions and a central soft tissue component showing post-contrast enhancement. Right maxillary sinusitis noted

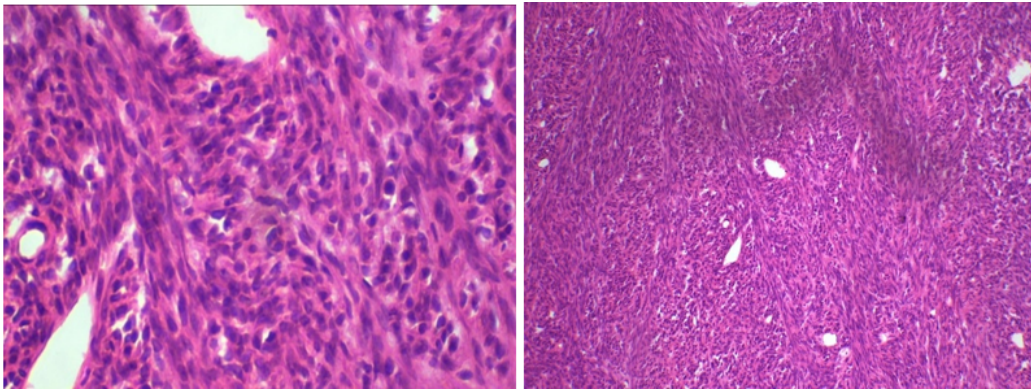


Fig. 4: The given H&E section shows highly cellular connective tissue mass made of numerous fibroblast cells arranged as fascicles which are interlacing in form of herring bone pattern and fibroblast have elongated nucleus and Cellular pleomorphism and mitotic figures are evidently seen. Given features are suggestive of Fibrosarcoma

of the soft tissue sarcomas are of unknown aetiology but some environmental and genetic factors are clearly associated with these neoplasms. Patients with genetic disorders, including neurofibromatosis and hereditary form of retinoblastoma are at risk for development of sarcomas. Trauma and chronic infection may play a role in the development of soft tissue sarcoma.⁶

Clinical manifestations of fibrosarcoma of the jaw are pain and swelling usually presenting symptom with an enlarging mass within bone which varies depending on the location, size, and spread of the tumor. Clinically FS is lobulated, sessile and non haemorrhagic submucosal mass of normal coloration in oral cavity.⁷ Overlying mucosa although initially normal but may become erythematous or ulcerated. If FS involving the course of peripheral nerves, may results in sensorineural abnormalities and if FS. Involving muscles of mastication or temporomandibular joint it may results in trismus.⁴

FS is a soft tissue lesion occurs adjacent to bone and may cause Saucer like depression in underlying bone or it may invade as squamous cell carcinoma. Sclerosis may occur in adjacent normal bone whether FS may be present peripherally or central to bone. Lesion may be typically infiltrative so extent of neoplasm may be underestimated.⁴

FS varies in histologic grade forms such as well differentiated form, Intermediate grade tumors and High grade lesion well differentiated form shows normal mitotic figures seen in small numbers, but cells and nuclei are not pleomorphic. Intermediate grade tumors are cellular and have the typical herringbone pattern showing the diagnostic parallel sheets of cells arranged in intertwining whorls with slight degree of cellular pleomorphism. High-grade lesions are very cellular with marked cellular atypia and mitotic activity extremely anaplastic and pleomorphic with bizarre nuclei.⁸

In most of head and neck sarcomas adequate surgical excision is not applicable because of its complex anatomy

and due to major vital structures which are located in close proximity to primary tumor. post-operative radiotherapy and / or chemotherapy should be preferred in cases When there is no adequately free surgical margins are present. chemotherapy provides improved local control especially if combined with radiation therapy where wide excision is not possible. Preoperative chemo-radiotherapy helps to shrink large soft tissue sarcomas specially those near vital structures prior to surgery. ⁹ Some literature review also suggests chemotherapy as high observed response rate particularly to the anthracycline and alkylating agent-free regimen of vincristine and dactinomycin.⁹

The need for adjuvant radiotherapy is still unclear and is usually indicated in high-grade tumors as these tumors may present sub-clinical or microscopic metastases at the time of diagnosis. Preoperative over postoperative irradiation include the following (According to J Radiat Oncol (2013) 2:135–148 143) First, preoperative treatment will produce partial regression of the tumor,. Second, preoperative treatment may decrease the risk of autotransplantation of the tumor in the surgical bed and may also decrease the risk of intravascular seeding. Third, in preoperative treatment, the clinically and radiographically demonstrable areas of risk are treated while other tissues are protected.¹⁰

4. Conclusion

Head and neck sarcomas are group of malignant neoplasms that affect critical structural units of head and / or neck that can result in grave consequences if not diagnosed properly in timely fashion. The diagnosis and management of soft tissue sarcomas of the head and neck is particularly challenging The rare and variable presentation of fibrosarcoma suggests a crucial role in dentistry. Thus, it should be considered as a differential diagnosis among soft tissue masses related to head and neck region.

5. Source of Funding

None.

6. Conflict of Interest

None.

References

1. Kumar V, Abbas AK, Aster JC. Robinson's Pathology. 9th ed.:
2. Greenberg MS, Glick M, Ship JA. Burket's oral medicine. Eleventh edition ed.:
3. Sahu S, Shrivastava S, Nayak S, Nayak P. Fibrosarcoma of maxilla: A rare case report. *J Oral Maxillofac Pathol.* 2016;20(1):162.
4. 2nd, editor. White and Pharoah's Oral Radiology Principles and Interpretation.:
5. Jin L, Yang HY, Wang YF, Yang HJ. Recurrent fibrosarcoma of maxillary sinus involving the cranial base: A rare case. *J Can Res Ther.* 2018;14:542–545.
6. Bree R, der Waal I, Bree E, Leemans CR. Management of adult soft tissue sarcomas of the head and neck. *Oral Oncol.* 2010;46:786–90.
7. Bang G, Baardsen R, Gilhuus-Moe O. Infantile fibrosarcoma in the mandible: case report. *J Oral Pathol Med.* 1989;18(6):339–43.
8. Shafer H. Shafer's Textbook of Oral Pathology. Seventh edition ed.:
9. Singh A, Singh H, Kumar D, Singh A. Intraoral Soft Tissue Fibrosarcoma in a Four-Year-Old Child: An Unusual Case Report. *J*

Clin Pediatr Dent. 2019;43(6):408–12.

10. Mancini BR, Roberts KB. Pediatric non-rhabdomyosarcoma soft tissue sarcomas. *J Radiat Oncol.* 2013;2(2):135–48.

Author biography

Vishal Bamniya Post Graduate Student

Ajay Pratap Singh Parihar Professor and HOD

Arvind Jain Reader

Ashish Saxena Professor and HOD

Sheetal Singar Post Graduate Student

Abhishek Maurya Post Graduate Student

Cite this article: Bamniya V, Parihar APS, Jain A, Saxena A, Singar S, Maurya A. Head and neck soft tissue fibrosarcoma in nine year old child: A case report. *J Oral Med, Oral Surg, Oral Pathol, Oral Radiol* 2020;6(2):106-109.