



Original Research Article

Role of mast cells in aetiopathogenesis of radicular cyst

Annapurna Doddamani^{1,*}, Akshatha B K¹, Charlotte¹, Veerendra Kumar²,
Rakhee Sharma¹, Rohini V J³

¹Dept. of Oral Pathology, M.R Ambedkar Dental College and Hospital, Bengaluru, Karnataka, India

²Vydehi Institute of Dental Sciences & Research Centre, Bengaluru, Karnataka, India

³H K E S N Dental College, India



ARTICLE INFO

Article history:

Received 30-05-2020

Accepted 06-06-2020

Available online 18-07-2020

Keywords:

Mast cells

Radicular cyst

Toluidine blue

ABSTRACT

Objectives: The aim of this study was to analyse distribution of mast cells in different zones in the capsule of radicular cyst and to determine its role in mechanism of cystic expansion.

Materials and Methods: 20 formalin fixed paraffin embedded tissue block from the diagnosed cases of radicular cyst were included and was cut into 5µm thickness. The staining of the tissue sections was done using freshly prepared Toluidine blue solution and mounted using DPX. The mast cell counting was carried out under 20 X magnifications in randomly selected 10 areas and the sections was divided into three zones; Subepithelial, Intermediate and Deep.

Result: Mast cells were found to be higher in the Intermediate zone (7.65%) followed by the Subepithelial (13.35%) and Deep zone(6.05%). Kruskal-Wallis test was applied which showed, no significant difference was found between the zones with respect to the mast cells (P>0.05).

Conclusion: The present study showed increased activity of mast cell in the intermediate zone indicating breakdown of capsular extracellular matrix in the subepithelial layer as well as enhancing increased osteoclastic activity in the deeper areas thereby leading to the cystic enlargement.

© 2020 Published by Innovative Publication. This is an open access article under the CC BY-NC license (<https://creativecommons.org/licenses/by-nc/4.0/>)

1. Introduction

Odontogenic cysts are the most common benign destructive lesions of the jawbones. About 95% of all such lesions are represented by Periapical cysts, dentigerous cysts and keratocystic odontogenic tumors.^{1,2} The most common odontogenic cystic lesion affecting the jaws is radicular cyst which is inflammatory in origin, commonly found affecting apices of the involved teeth.³ These odontogenic cysts destroy bone and undergo expansive growth in both the maxilla and the mandible due to breakdown of the extracellular matrix, build-up of osmotic pressure in the cystic fluid or due to perilesional bone resorption.⁴ The proteolysis of collagen fibers, osteoid-derived gelatine and protein components of basement membrane results in breakdown of extracellular matrix resulting in jaw cystic

expansion.⁵

A bacterial, chemical or mechanical irritation from tooth root canals causes inflammation of periapical tissue. As the inflammation in periapical lesions could be acute or chronic in form, they manifest differently, both clinically and microscopically. Histopathologic examination reveals numerous inflammatory cells such as polymorpho-nuclear leukocytes, macrophages, lymphocytes, plasma cells, mast cells, basophils and eosinophils. The presence of these cells indicates the existence of local immune reactions in periapical lesions.⁶

The mast cell is a phylogenetically old cell which occurs in all species with blood circulation. Mast cells are round or elongated cells with the cytoplasm containing metachromatic granules. They were first described by Paul Ehrlich in 1878 and named these cells Mastzellen because he hypothesized that the intracellular granules

* Corresponding author.

E-mail address: dr.annapurna20jan@gmail.com (A. Doddamani).

would contain phagocytosed materials or nutrients.^{7,8}

Mast cells are found in a variety of tissues including skin, submucosa or connective tissue of various organs, mucosal epithelial tissues and dental pulp. They are typically distributed in the perivascular and the perineural regions.⁹ Upon activation, mast cells containing numerous cytoplasmic granules are degranulated into the extracellular space. Activated mast cells can synthesize platelet activating factors, chemotactic mediators and several pro-inflammatory cytokines such as IL-1 α , IL-3, IL-6 and TNF- α .^{4,10} Additionally, mast cells being a rich source of heparin and proteolytic enzymes, such as tryptase, chymase and hyaluronic acid, participates in connective tissue breakdown during metabolic turnover and in inflammation. Products released by activated mast cell and breakdown products of connective tissue elements, are extruded into the cystic lumen raising the hydrostatic pressure leading to enlargement. It has also been shown that mast cells may enhance bone resorption by heparin production.⁵

The aim of this study was to assess mast cell distribution in different zones in the capsule of radicular cyst and to analyze and study the number of mast cells in radicular cyst contributing in cystic enlargement.

2. Materials and Methods

The study included 20 formalin fixed paraffin embedded tissue block which was retrieved from the archives of department of oral pathology and microbiology. 5 μ m paraffin sections from the diagnosed cases of radicular cyst were included in the study. All the sections were subjected to dewaxing thoroughly in xylene and hydrated through descending grades of alcohol. The tissue sections were stained by freshly preparing Toluidine blue solution (1% toloum blue in 1% sodium chloride) and mounted with DPX. The mast cell counting done under 20 X magnification. Mast cells were counted in randomly selected 10 areas and the sections was divided into three zones.

1. Subepithelial.
2. Intermediate.
3. Deep.

3. Results

Statistical analysis revealed mean no. of mast cells was found to be higher in the Intermediate zone followed by the Subepithelial zone and the Deep zone respectively (Table 1). Kruskal-Wallis test was applied which showed, no significant difference was found between the zones with respect to the mast cells (Table 2).

Table 1: Mast cell distribution in different zones of radicular cyst with mean value and standard deviation

Zone	Mean value	SD
Subepithelial	7.65	10.94
Intermediate	13.35	21.23
Deep	6.05	7.21

Table 2: According to Kruskal-Wallis analysis the P value is >0.05

Zone	Mean Rank	P-Value
Subepithelial	29.00	
Intermediate	35.38	0.288
Deep	27.13	

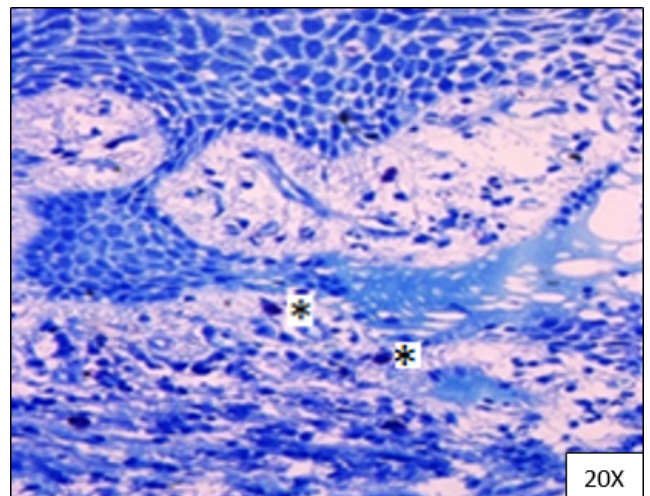


Fig. 1: Toluidine blue stained section shows * Mast cell in subepithelial zone

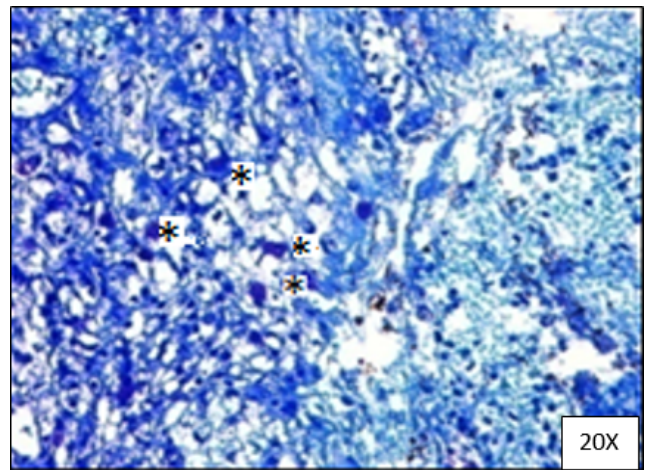


Fig. 2: Increased number of * mast cells in intermediate zone

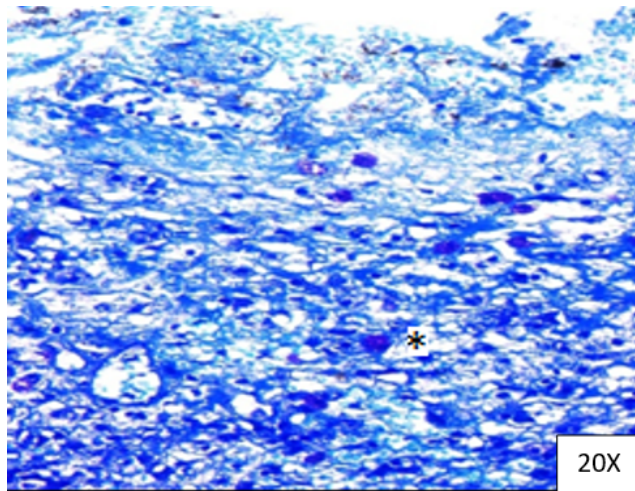


Fig. 3: Less number of * mast cells found in deeper zone

4. Discussion

Mast cells are found widespread throughout the connective tissue wall of all cysts and more particularly in periapical cyst, dentigerous cyst and keratocystic odontogenic tumor.⁴ It has been previously suggested that mast cell degranulation products could be associated with increasing destruction of extracellular matrix in the cystic wall and with stimulation of cytokine production, thus facilitating the expansion of these lesions.^{4,5}

Periapical lesions occur in response to chronic irritation in periapical tissue, resulting in increased number of inflammatory cells, among which mast cells play a major role in the formation of granulomas and cysts.¹¹

In present study, the results showed increased number of mast cells in intermediate zone (13.35%) of radicular cyst followed by subepithelial (7.65%) and deep (6.05%) zone. The increased activity of mast cell in the intermediate zone indicates the release of hydrolytic enzymes resulting in the breakdown of capsular extracellular matrix in the subepithelial layer as well as enhancing increased osteoclastic activity in the deeper areas thereby leading to the cystic enlargement. This finding is in accordance with study of Shailja et al.⁵ who has speculated that the mast cells are implicated in bone destruction and inhibition of these cells could modulate cystic growth.

Shailja et al. revealed increased presence of mast cells in the subepithelial zone of periapical cyst, dentigerous cyst and keratocystic odontogenic tumors stained by the toluidine blue suggesting an increased breakdown of capsular matrix resulting in cystic expansion.⁵

This may indicate higher activity of mast cells in the external layer of the cystic wall, in close proximity of perilesional bone, suggesting that degranulation of mast cell are associated in bone resorption at the cyst-bone interface, there by leading to cyst enlargement. In contrast Netto et

al.⁴ showed higher frequency of mast cell distribution in the deepest region of connective tissue wall, suggesting that these cells may be associated with the phenomenon of bone resorption. De Oliveira et al.⁶ found that mast cells were more frequently in periapical cysts than in granuloma based on expression of mast cell tryptase in both lesions.

On mast cell degranulation various mediators are released thereby, playing an important role in the pathogenesis of odontogenic cysts.¹² The hydrostatic pressure of the luminal fluid is essential in cyst enlargement. The increase in the osmotic pressure of the fluid by activated mast cell can be due to following ways-

1. Heparin being directly released into the luminal fluid.
2. Degradation of capsular extracellular matrix components by the release of hydrolytic enzymes which may facilitate their passage into the fluid.
3. By the histamine action on contraction of smooth muscles and vascular permeability enhances exudation of serum protein following entry into luminal fluid.¹²

5. Conclusion

The role of mast cells and their products in the pathogenesis of inflammatory and non-inflammatory odontogenic cysts still remains an enigma. Future studies with larger sample size will lead to elucidate the contribution of mast cells to the development of these lesions.

6. Source of Funding

None.

7. Conflict of Interest

None.

References

1. Mosqueda TA, Irigoyen-Camacho ME, Diaz-Franco MA, Torres-Tejero MA. Odontogenic cysts. Analysis of 856 cases. *Med Oral*. 2002;7:89–96.
2. Ochsenius G, Escobar E, Godoy L, Penafiel C. Odontogenic cysts: analysis of 2,944 cases in Chile. *Med Oral Pathol Oral Cir Bucal*. 2007;12:85–91.
3. Nainani P, Sidhu GK. Radicular Cyst -An Update with emphasis on Pathogenesis. *J Adv Med Dent Scie Res*. 2014;2(3):97–98.
4. Netto J, Pires FR, Fonseca E, Sliva LE, Lourenco S. Evaluation of mast cells in periapical cysts, dentigerous cysts and keratocystic odontogenic tumors. *J Oral Pathol Med*. 2012;41:630–6.
5. Chatterjee S, Mahajan S, Boaz K, Thomas G. Quantitative role of mast cells in odontogenic cystic enlargement. *Braz J Oral Sci*. 2008;7(27):1662–5.
6. Dražić R, Sopta J, Minić AJ. Mast cells in periapical lesions: potential role in their pathogenesis. *J Oral Pathol Med*. 2010;39(3):257–62.
7. Molderigs GJ. Mast cell functions in physiology and pathophysiology; 2010.
8. Amin K. The role of mast cells in allergic inflammation. *Respir Med*. 2012;106:9–14.
9. Urb M, Sheppard DC. The Role of Mast Cells in the Defence against Pathogens. *PLoS Pathog*. 2012;8(4):1–3.

10. Kheur S, Pathekar D, Neeta B, Kulkarni M, Routray S, Dhas V. Role of mast cell in oral pathology. *Oral Maxillofac Pathol J.* 2013;4(1):320–5.
11. de Oliveira Rodini C, Batista AC, Lara VS. Comparative immunohistochemical study of the presence of mast cells in apical granulomas and periapical cysts: possible role of mast cells in the course of human periapical lesions. *Oral Surg Oral Med Oral Pathol Oral Radiol Endod.* 2004;97:59–63.
12. Debta P, Debta FM. Evaluation of Infiltration of Immunological Cells (Tissue Eosinophil and Mast Cell) in Odontogenic Cysts by Using Special Stains. *J Clin Cell Immunol.* 2010;1(1):1–4.

Akshatha B K Assistant Professor

Charlotte Professor

Veerendra Kumar Reader

Rakhee Sharma Assistant Professor

Rohini V J MDS

Author biography

Annapurna Doddamani Doctor (MDS)

Cite this article: Doddamani A, Akshatha B K , Charlotte , Kumar V, Sharma R, Rohini V J . Role of mast cells in aetiopathogenesis of radicular cyst. *J Oral Med, Oral Surg, Oral Pathol, Oral Radiol* 2020;6(2):81-84.