



Original Research Article

Assessment of cases of ameloblastoma in different age groups- A clinico-histological study

Supriya Singh¹, Rohit Singh^{2,*}, Kumar Anand³, Aaysha Tabinda Nabi⁴, Irfanul Huda², Qalbi Fatima⁴

¹Dept. of Oral Medicine and Radiology, Awadh Dental College and Hospital, Jamshedpur, Jharkhand, India

²Dept. of Prosthodontic, Patna Dental College and Hospital, Patna, Bihar, India

³Dept. of Oral Medicine and Radiology, Buddha Institute of Dental Sciences and Hospital, Patna, Bihar, India

⁴Dept. of Periodontology, Buddha Institute of Dental Sciences and Hospital, Patna, Bihar, India



ARTICLE INFO

Article history:

Received 03-04-2020

Accepted 30-05-2020

Available online 18-07-2020

Keywords:

Ameloblastoma

Basal

Plexiform

ABSTRACT

Background: Ameloblastoma is an odontogenic neoplasm, and accounts 11-13% of all odontogenic tumours. The current study was carried out to evaluate cases of ameloblastoma.

Materials and Methods: The current study was carried out on 85 cases of ameloblastoma of both genders. Anatomical location and histopathological variant etc. was recorded.

Results: Out of 85 cases, males were 55 and females were 30. Most common type seen was plexiform seen in 35 patients, followed by follicular and acanthomatous in 20 each, granular in 7, desmoplastic in 2 and basal in 1 patient. The difference obtained was statistically significant ($p < 0.05$).

Conclusion: Authors found that maximum cases were of plexiform type and mandible was commonly involved bone.

© 2020 Published by Innovative Publication. This is an open access article under the CC BY-NC license (<https://creativecommons.org/licenses/by-nc/4.0/>)

1. Introduction

Ameloblastoma is an odontogenic neoplasm, and accounts 11-13% of all odontogenic tumors. It is aggressive, locally invasive persistent tumor that has benign characteristics of growth.¹ It has three different types: 1) solid multicystic ameloblastoma (SMA); 2) unicystic ameloblastoma and 3) peripheral ameloblastoma.² Desmoplastic ameloblastoma is considered as a distinct type because of its different biological behavior, radiographic feature and unique histopathology. These tumors are epithelial in origin. They can arise from: remnants of the dental lamina, developing enamel organ, epithelial lining of odontogenic cysts, offshoots of basal cells oral epithelium, heterotopic epithelium. (e.g., pituitary gland).³

Clinically, it usually presents itself as an asymptomatic swelling occurring most commonly in posterior mandible. It is frequently associated with an impacted tooth. It

predominantly effect individuals aged between 30 and 60 years. There is no definite gender predilection. Conventional ameloblastoma radiographically represent as a unilocular or multilocular radiolucent lesion surrounded by a radiopaque border.⁴ Ameloblastoma has a tendency for expansion. Unicystic lesions present more commonly as unilocular radiolucency. The internal structure varies from totally radiolucent to a mixed radiolucent-radiopaque caused by presence of bony septae creating internal compartments, which may give rise to soap bubble, honeycomb, spider-like or mother-and-daughter cell appearances. The appearance of septae on the radiograph usually represents differential resorption of the cortical plate by the tumor and not actual separation of tumor portions.

Ameloblastoma can be divided histologically in four types: solid, unicystic, peripheral and desmoplastic. Based on its cellular and organization pattern, it can be divided into five subtypes: follicular, plexiform, acanthomatous, granular and basal cell. These types can occur as solitary lesion or in

* Corresponding author.

E-mail address: draayasha345@gmail.com (R. Singh).

combination.⁵ The current study was carried out to evaluate cases of ameloblastoma in different age groups.

2. Materials and Methods

The present study was conducted in the department of Oral Pathology and Oral Medicine & Radiology. This study consists of 85 cases of ameloblastoma of both genders. The inclusion criteria were cases within specified age group and those giving consent to participate in the study. Exclusion criteria were cases with poor radiographs or with indefinite diagnosis and those unwilling to participate. The protocol was approved from ethical committee of institutional before the commencement of study.

General demographic characteristics such as age, gender, name etc. was recorded in case history performa. Other factors such as anatomical location and histopathological type etc. were also recorded. Type of treatment was also recorded. Patients were followed up regularly. Results obtained were tabulated on Microsoft excel sheet and subjected to statistical analysis. P value < 0.05 was considered as statistically significant.

3. Results

Table 1: Distribution of cases

Total- 85		
Gender	Males	Females
Number	55	30

Table 1 revealed that out of 85 cases, males were 55 and females were 30.

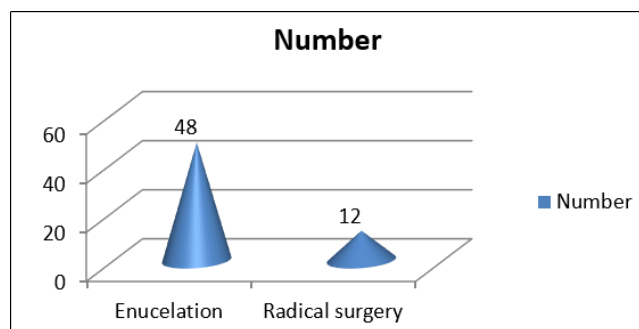


Fig. 1: Type of treatment given to different cases

Figure 1 shows that in most of the cases (67 cases) treatment given was enucleation and radical surgery in only 18 cases which showed statistically significant difference (P < 0.05).

4. Discussion

As per World Health Organization (2005) classification ameloblastoma is divided into 1) solid/multicystic, 2) extra-osseous/peripheral, 3) desmoplastic, and 4) unicystic (3).

The solid/multicystic ameloblastoma can histopathologically be divided into a follicular and a plexiform type; the follicular type can be further subdivided into a spindle cell type, an acanthomatous type, a granular type and a basal cell type.⁶

In radiographs ameloblastoma are revealed as a unilocular or multilocular radiolucent lesion with sclerotic border. Bony septae may result in a honeycomb appearance. Roots resorption may or may not be observed.⁷ The radiographic differential diagnosis includes a variety of odontogenic cysts and tumours, particularly the odontogenic keratocyst, central giant cell granuloma, simple bony cyst and fibro-osseous lesions. Desmoplastic ameloblastoma characterized by a mottled, mixed radiolucency/radiopacity with diffuse margins, suggesting a fibro-osseous lesion.⁸ The current study was carried out to evaluate cases of ameloblastoma in different age groups.

In the present study, out of 85 cases, males were 55 and females were 30. The most common type seen was plexiform seen in 35 patients, followed by follicular and acanthomatous in 20 each, granular in 7, desmoplastic in 2 and basal in 1 patient. Arotiba et al⁹ observed in their study on 540 odontogenic tumors, 40 patients were having ameloblastomas with an overall prevalence rate of 7.4%. Males were frequently involved with male: female ratio of 1.8:1. Ameloblastoma affected individuals with age range between 21-60 years but most of them were seen in age group of 31-40 years. They observed follicular ameloblastoma as most common histological variant (42.5%) followed by acanthomatous type (32.5%). Two of the patients presented with the granular cell type which is considered as most aggressive form of ameloblastoma. The most frequent anatomical location of ameloblastoma was in the mandibular posterior area (87.5%) whereas maxillary posterior area was affected in 12.5% of the cases.

In the present study, 25 cases were observed in maxilla and 60 in mandible. In 67 cases enucleation and radical surgery in 18 cases were given as treatment. Chidzonga et al¹⁰ observed no statistically significant differences between the histopathological (sub) types of ameloblastomas and the demographical, clinical parameters, nor between the histopathological (sub) types and treatment outcome.

In present study, 67 cases treated with enucleation and radical surgery was done in 18 cases. The follow up for the study was 12- 26 months. We did not report recurrence in any of our study. Figueiredo et al.¹¹ in their study on ameloblastoma found that the mean age in males was 23.25 ± 6.99 years, while that in females was 43.43 ± 17.13 years. Seven (63.63%) of the 11 subjects were females, and four (36.36%) were males. 10 (90.9%) of the 11 ameloblastomas were located in the mandible. Swelling was noted in all 11 patients. 10 cases showed radiographic findings, while one case was a peripheral

Table 2: Distribution of histological subtypes based upon age of subject

Types	21-30 years	31-40 years	41-50 years	>50 years	Total
Plexiform	15	8	7	5	35
Follicular	12	4	3	1	20
Granular	4	1	2	0	7
Desmoplastic	2	0	0	0	2
Acanthomatous	10	5	3	2	20
Basal	1	0	0	0	1

Table 2 demonstrated that most common type was plexiform as it is seen in 35 patients, followed by follicular and acanthomatous ameloblastoma in 20 each, granular in 7, desmoplastic in 2 and basal in 1 patient. The difference was statistically significant ($P < 0.05$).

Table 3: Histological subtypes as per different Anatomical location

Types	Maxilla	Mandible
Plexiform	5	30
Follicular	8	12
Granular	2	5
Desmoplastic	2	0
Acanthomatous	7	13
Basal	1	0
Total	25	60

Table 3 shows that 25 cases were seen in maxilla and 60 were in mandible. The difference was significant ($P < 0.05$).

soft-tissue variant. Seven (70%) of the 10 tumors were multilocular with a well-demarcated corticated border, and three cases (30%) were unilocular. Two cases showed a soap-bubble appearance. Histologically, five cases were unicystic, four were multicystic, one was desmoplastic and one was a peripheral variant. Follow-up ranged from 12 to 34 months and there were no signs of recurrence in any of the patients.

Ameloblastoma is common entity seen mostly in posterior mandible in molar, ramus region. Numerous studies have been done to assess cases of ameloblastoma. In our study we also tried to evaluate different histological type in different age groups. The limitation of present study is small sample size.

5. Conclusion

Authors found that ameloblastoma is a common tumour occurring in all age groups. The most common histologically type recorded in our study was plexiform and mandible the most frequent site as compared to maxilla. However, large scale studies need to be done to substantiate the results.

6. Source of Funding

None.

7. Conflict of Interest

None.

References

1. Shear M, Singh S. Age-standardized incidence rates of ameloblastoma and dentigerous cyst on the Witwatersrand, South Africa. *Community*

Dent Oral Epidemiol. 1978;6(4):195–9.

2. Barnes L, Eveson JW, Reichart P, Sidransky D. World Health Organization classification of tumors, pathology and genetics. Head and neck tumors. Lyon: IARC Press; 2005.
3. Hertog D, Schulten EA, Leemans CR, Winters HA, Van der Waal I. Management of recurrent ameloblastoma of the jaws; a 40-year single institution experience. *Oral Oncol.* 2011;47:145–6.
4. Gilihamse M, Leemans CR, Winters HA, Schulten EA, van der Waal I. Metastasizing ameloblastoma. *Int J Oral Maxillofac Surg.* 2007;36:462–6.
5. Generson RM, Porter JM, Stratigos GT. Mural odontogenic epithelial proliferations within the wall of a dentigerous cyst: Their significance. *Oral Surg Oral Med Oral Pathol.* 1976;42:717–21.
6. Siar CH, Lau SH, Ng KH. Ameloblastoma of the Jaws: A Retrospective Analysis of 340 Cases in a Malaysian Population. *J Oral Maxillofac Surg.* 2012;70(3):608–15.
7. Jing W, Xuan M, Lin Y, Wu L, Liu L, Zheng X, et al. Odontogenic tumours: a retrospective study of 1642 cases in a Chinese population. *Int J Oral Maxillofac Surg.* 2007;36(1):20–5.
8. Tawfik MA, Zyada MM. Odontogenic tumors in Dakahlia, Egypt: analysis of 82 cases. *Oral Surg Oral Med Oral Pathol Oral Radiol Endod.* 2010;109:67–73.
9. Arotiba GT, Ladeinde AL, Arotiba JT, Ajike SO, Ugboko VI, Ajayi OF. Ameloblastoma in Nigerian Children and Adolescents: A Review of 79 Cases. *J Oral Maxillofac Surg.* 2005;63(6):747–51.
10. Chidzonga MM, Perez VML, Alvarez ALP. Ameloblastoma. *Oral Surg Oral Med Oral Pathol Oral Radiol Endod.* 1996;82:38–41.
11. Figueiredo NR, Dinkar AD, Meena M, Satoskar S, Khorate M. Ameloblastoma: A clinicoradiographic and histopathologic correlation of 11 cases seen in Goa during. *Contemp Clin Dent.* 2008;5(2):160.

Author biography

Supriya Singh Senior Lecturer

Rohit Singh Senior Lecturer

Kumar Anand Reader

Aaysha Tabinda Nabi Reader

Irfanul Huda Reader

Qalbi Fatima Post Graduate Student

Cite this article: Singh S, Singh R, Anand K, Nabi AT, Huda I, Fatima Q. Assessment of cases of ameloblastoma in different age groups- A clinico- histological study. *J Oral Med, Oral Surg, Oral Pathol, Oral Radiol* 2020;6(2):67-70.