



Original Research Article

To compare outcome of minimally invasive Anterograde Titanium Elastic Nailing(RTEN) with that of a standard plating technique for the treatment of displaced Midshaft Clavicular Fracture (MSCFs).

Sumit Jain Sethia¹, Vinod K Gautam¹, Vishal M Mehta^{1,*}, Sagar R Kothiya¹¹Dept. of Orthopaedics, Govt. Medical College, Bhavnagar, Gujarat, India

ARTICLE INFO

Article history:

Received 11-08-2020

Accepted 19-10-2020

Available online 30-12-2020

Keywords:

RTEN

Plating and MSCF

ABSTRACT

Background: The follow-up observational study between TENS and PLATE group in Displaced Midshaft Clavicular fracture conducted in the Department of Orthopaedics, Sir Takhtsinhji Hospital, Bhavnagar, after getting permission from ethical committee.

Materials and Methods: All patient coming to Sir Takhtsinhji General Hospital, Bhavnagar with midshaft clavicular fracture and who admitted for surgery and met the criteria was included in this study. Patients with fractures older than 4 weeks or with pathological fractures or those having associated head injury or having bilateral fracture was excluded from the study. After explaining the purpose of the study, a written informed consent was taken from all the participants before data collection. The data were recorded in a predesigned and pretested proforma. Data was collected from past records, and in subsequent 6 weeks, 3 and 6 months postoperative follow up.

Result: At the end of the study, we had 15 patients in the Plate group and 15 in the TEN group for comparison. In the Plate group, we had 08 male and 07 female patients, whereas there were 09 male and 06 female patients in the TEN group. The Duration of Surgery was 71.34 ± 6.67 in the Plate group and 48 ± 5.60 in the TEN group. The use of minimally invasive antegrade TEN for fixation of displaced midshaft clavicle fractures is recommended. The functional outcome at 3 months was good in 14 cases (46.66%), adequate in 16 patients (53.34%). Out of all the good outcomes, 9 cases (60%) were from TEN group while 5 patients (33.3%) from plate group.

Conclusion: All patients were evaluated at 6 weeks, 3 and 6 months with follow up radiologically by x-rays. In our study Road Traffic Accident was the most common cause for clavicle fractures. Fall on out stretched hand was the commonest mechanism of injury. We studied the fracture pattern (intra operative finding) based on mode of injury and mechanism of injury. From this AO 2B2 (comminuted mid shaft fracture) is associated with high velocity injury and direct impact on the shoulder.

© This is an open access article distributed under the terms of the Creative Commons Attribution License (<https://creativecommons.org/licenses/by/4.0/>) which permits unrestricted use, distribution, and reproduction in any medium, provided the original author and source are credited.

1. Introduction

The name clavicle originates from the Latin word clavis which means key. Clavicula is a diminutive of clavis and means small key, referring to its size and the fact that the clavicle is able to rotate around its axis enabling full range of motion of shoulder girdle. Clavicle acts as bony connection between thorax and shoulder girdle while contributing to

movements around the shoulder.¹

It is the common bone to fracture accounting for 4-12% of all fractures and 44-66% fractures around shoulder. Of all clavicle fractures midshaft fractures contribute around 80% of cases.² In 94% of cases it follows direct trauma whereas rest cases occur due to fall on outstretched hand.³ Midshaft fracture commonly occurs in young adult whereas lateral and medial end clavicle fracture is more common in elderly.⁴ More than 200 methods of operative and nonoperative methods for management of clavicle fractures

* Corresponding author.

E-mail address: drvishalmehta3011@gmail.com (V. M. Mehta).

have been described. These methods can be roughly divided into operative and non operative methods.

Most commonly used nonoperative method is clavicle brace and an arm sling. It has advantage of being noninvasive and absence of exposure to anesthesia. However, nonoperative methods are said to be associated with risk of non-union, residual deformity and patient dissatisfaction. Most clavicular fractures still are treated closed and heal uneventfully without serious consequences.⁵

Nonoperative management was widely recommended for middle third fracture given higher union rate with nonunion of 0.03 to 6.2%.⁵

Falls onto the affected shoulder leading to a bending force account for most (87%) of clavicular fractures, with direct impact accounting for only 7% and falls onto an outstretched hand accounting for 6%.

2. Materials and Methods

The follow-up observational study between TENS and PLATE group in displaced midshaft clavicular fracture conducted in the Department of Orthopaedics, Sir Takhtsinhji Hospital, Bhavnagar, permission was taken from ethical committee.

All patient came to Sir Takhtsinhji General Hospital, Bhavnagar with midshaft clavicular fracture and who admitted for surgery and met the criteria was included in this study. Patients with fractures older than 4 weeks or with pathological fractures or those having associated head injury or having bilateral fracture was excluded from the study. After explaining the purpose of the study, a written informed consent was taken from all the participants before data collection. The data were recorded in a predesigned and pretested proforma. Data was collected from past records, and in subsequent 6 weeks, 3 and 6 months postoperative follow up. All information along with identity of participants was kept confidential.

2.1. Inclusion criteria

Age group 20 to 60yrs, displaced unilateral midshaft clavicle fracture within last 4 weeks with no cortical contact or shortening over 2cm and Fracture tenting or compromising skin with axial mal alignment.

2.2. Exclusion criteria

Fracture with marked comminution, Fracture Older than 4 weeks, Pathological fractures, Open fracture, Congenital anomaly or Bone disease, Bilateral clavicular fracture, Fracture associated with Neurovascular injuries, Segmental fractures & Fracture associated with Head injury.

2.3. Investigations

1. Radiography: Plain radiographs of clavicle, anteroposterior view and 45 degree cephalic tilt view was taken to assess the site of fracture, type of fracture, displacement of fracture and comminution. The fracture was classified according to OTA (Ortho Trauma Association) and Robinson's classification. Affected arm immobilized with arm-sling or clavicle brace.
2. Laboratory investigations: Complete haemogram, renal function test, ECG and Chest X-ray were done and PAC (pre anaesthetic checkup) completed.

2.4. Procedure

After anesthesia patient placed in supine position with sandbag underneath scapula in a radiolucent table. With an image intensifier on the ipsilateral side by rotating the image 45 degrees caudal and 45 degrees cephalad orthogonal views of the clavicle can be obtained. A vertical skin incision around 0.5 cm was made just lateral to the sternoclavicular joint. The subcutaneous fat was incised along with platysma. The pectoral fascia was divided in line with the skin incision followed by careful elevation of the underlying musculature from the clavicle. An entry portal is made with a drill or awl and appropriate size nail is inserted (2.5/3.0 mm). Attempt made for close reduction of fracture. If close reduction not possible incision given at fracture site and at that time, the nail was used to create a path in the lateral end of the clavicle for subsequent easy access. The nail was then passed from the medial side and across the reduced fracture into the lateral end of clavicle. Under radiographic control, the IM device is passed across the fracture site and seated in the far fragment. The fracture is checked clinically and radiographically to ensure correct alignment, length, and rotation. After reaching the end point, the fracture was compressed and the nail was cut close to the entry point to minimize soft tissue irritation, at the same time leaving sufficient length behind for easy extraction later on. The fascia and skin were closed in layers.

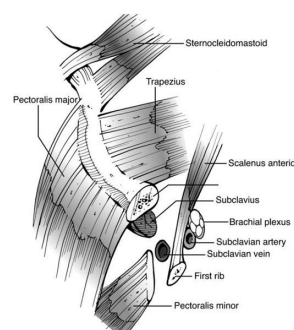


Fig. 1: Neurovascular anatomy of clavicle

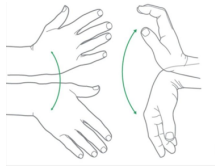


Fig. 2: Movement of open hand side to side and wrist in up-down

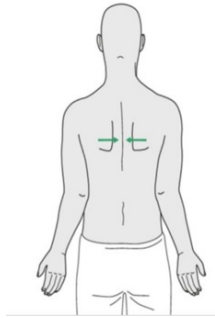


Fig. 3: Squeezing the shoulder blades together while shoulder remain

Clinical cases 1: TENS nailing

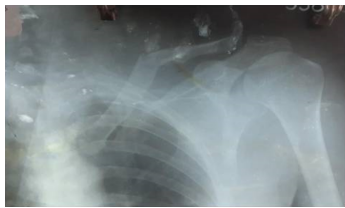

Fig. 4: Pre-operative

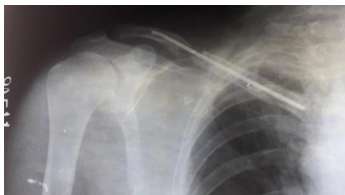

Fig. 5: Post-operative

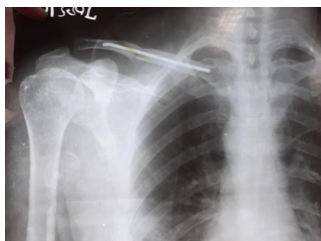

Fig. 6: Post-operative

Clinical case 2: Clavice plating

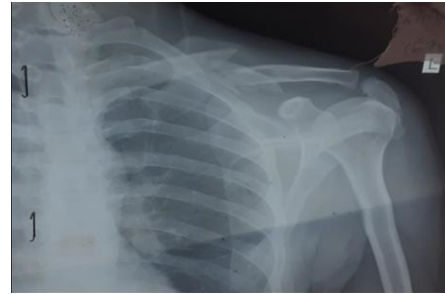

Fig. 7: Pre-op x-ray

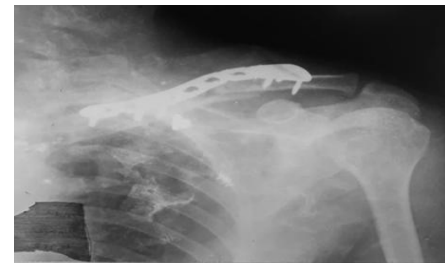

Fig. 8: Post-op x-ray

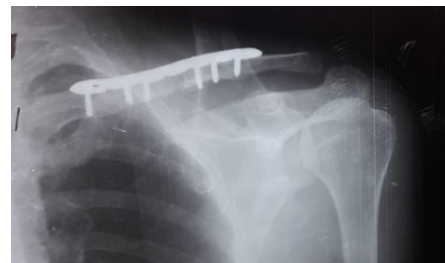


Fig. 9: Follow-up xray 3 month

3. Results

At the end of the study, we had 15 patients in the plate group and 15 in the TEN group for comparison. In the plate group, we had 08 male and 07 female patients, whereas there were 09 male and 06 female patients in the TEN group. The Duration of Surgery was 71.34 ± 6.67 in the plate group and 48 ± 5.60 in the TEN group. The use of minimally invasive antegrade TEN for fixation of displaced midshaft clavicle fractures is recommended

4. Discussion

Clavicle fractures have been treated till so long time by conservative means like “figure of 8 bandage”. But because of significantly higher nonunion rates (ranging between 10% — 15%). Recently operative treatment is

Table 1: Age distribution

Age	Management		Total
	TEN group	Plating group	
20-30 years	03	02	05
31-45years	10	12	22
46-60 years	02	01	03
Total	15	15	30

Table 2: Mode of injury

MOI		Management		Total	%
		TEN group	ORIF with plating		
Fall on outstretched hand		02	01	03	10%
	RTA	13	14	27	90%
Total		30	30	30	100%

Table 3: Outcome comparisons

Variable	TEN group	Management Plating group	P Value
Duration of Surgery	48±5.60	71.34±6.67	<0.0001
Mean wound size(cm)	3.79±0.24	11.166±0.47	<0.0001
Average blood loss(ml)	42±7.27	133±10.31	<0.0001
Mean hospital stay (days)	2.8±0.77	4.4±0.507	<0.0001
Shortening of clavicle(mm)	4.433±0.97	2.926±0.92	<0.0002
Asymmetry	–	–	–
Union time	17.7±1.360	20.7±1.177	<0.0001

Table 4: Fracture distribution(as per AO classification)

AO class	Tens group	Plate group
B1 Fracture	11	5
B2 fracture	04	10
Overall (B1+B2)	15	15

Table 5: Comparison of average constant score

Duration	Tens group (Mean SD)	Plate group (Mean SD)	p value
6 Week	68.266±1.831	66.6±2.063	<0.0266
3 Months	80.266±2.017	78.533±2.200	<0.0325
6 Months	88.866±1.685	86.800±2.145	<0.0066

Table 6: Functional outcome of each patient was noted by constant and Murley score and graded as below.

Total score	Result
90-100	Excellent
80-89	Good
70-79	Adequate
0-69	Poor

Table 7:

Total I score	Nail			Plate			Result
	6 Week	3 Month	6 Month	6 Week	3 Month	6 Month	
90-100			5			2	Excellent
80-89		9	10		5	13	Good
70-79	4	6		1	10		Adequate
0-69	11			14			Poor
Total		15			15		

Table 8: Cosmetic complication

Complication	TEN group		ORIF with plating	
	No of cases	%	No of cases	%
Hypertrophic callus	01	6.66	00	–
Hypertrophic scar	00	–	03	20%
Implant prominence under skin	02	13.33%	03	20%

recommended for displaced shaft clavicle fracture to improve functional and cosmetic outcome.^{6,7}

The AO/OTA fracture and dislocation classification compendium was updated in 2007 to include recent developments including a unified numbering scheme and measures to improve observer reliability. The clavicle is designated as segment 15, and is divided into the standard medial metaphyseal, diaphyseal, and lateral metaphyseal fractures. An important difference is that the metaphyseal fractures in this scheme are not one-third of the length of the bone but are shorter segments, according to the AO “rule of squares.” For the all-important diaphysis, there are simple (15-B1), wedge (15-B2), and complex (15-B3) subtypes.

Operative treatment has progressed from open reduction and fixation to closed reduction with intramedullary fixation. Extra-medullary fixation have been performed by using dynamic compression plate, reconstruction plate, pre-contoured plates, locking plates and now 3-D contoured plates. Intramedullary fixation can be done by smooth or threaded K-wires, Steinman pins, Knowles pins, Hagie pins, rush pins, cannulated screws or elastic nail.⁸

In our study, we have compared the results of anterosuperior plating versus IM fixation with TEN.

The use of the 3.5 mm reconstruction plating allowed adequate fixation. This was facilitated by its easier contouring to fit the S shape of the clavicle than for other plates, thereby providing maximum fracture stability. The technique provides stable fixation, avoids risk to the vital structures below the clavicle, and has a low rate of implant prominence and low incidences of nonunion and implant failure.⁹

4.1. Indications for operative treatment of clavicular fractures are

Displacement greater than 2cm, Increasing comminution greater than 3 fragments, shortening greater than 2cm, neurovascular injury or compromise that is progressive or that fails to reverse after the closed reduction of the fracture. Open fracture with impending soft tissue compromise. Segmental fractures, Multiple traumas, when mobility of the patients is desirable and closed methods of immobilization are impractical or possible, Bilateral clavicle fractures and ipsilateral upper rib fractures, floating shoulder, progressive neurological deficit. Cosmetic reasons and patient motivation for rapid rehabilitation.

In the plate group good to excellent results were achieved in 35 of 37 patients, compared with all good to excellent

results in 34 patients of the TEN group. Overall, there were no unsatisfactory results in our study, whereas the incidence of unsatisfactory results after operative treatment of DMCFs is 5.3% in literature.¹⁰

The average time to achieve union in this study was significantly faster in the TEN group than in the plate group ($P = 0.025$). This can be explained by the less soft tissue dissection in the TEN group. The plating provides absolute stability resulting in primary bone healing, whereas TEN provides relative stability leading to secondary bone healing by callus formation.

5. Conclusion

The use of minimally invasive antegrade TEN for fixation of displaced midshaft clavicle fractures is recommended in view of faster fracture union, lesser morbidity, better cosmetic results, easier implant removal and fewer complications; although for comminuted fractures plating remains the procedure of choice. All patients were evaluated at 6 weeks, 3 and 6 months with follow up radiologically by x-rays. In our study road traffic accident was the most common cause for clavicle fractures. Fall on outstretched hand was the commonest mechanism of injury. We studied the fracture pattern (Intra operative finding) based on mode of injury and mechanism of injury. From this AO 2B2 (Comminuted mid shaft fracture) is associated with high velocity injury and direct impact on the shoulder.

6. Source of Funding

None.

7. Conflict of Interest

The author(s) declare that there is no conflict of interest.

References

1. Moore KL, Dalley AF. Clinically oriented anatomy. 3rd ed. and others, editor. Pennsylvania, United States: Lippincott Williams & Wilkins; 1992.
2. Egol KA, Koval KJ, Zuckerman JD. Handbook of fractures. 4th ed. Pennsylvania, United States: Wolters Kluwer/Lippincott Williams & Wilkins Health; 2010.
3. Stanley D, Trowbridge EA, Norris SH. The mechanism of clavicular fracture. A clinical and biomechanical analysis. *J Bone Joint Surg Br.* 1988;70(3):461–4.
4. Robinson CM. Fractures of the clavicle in the adult. *J Bone Joint Surg Br.* 1998;80(3):476–84.

5. Rowe CR. An atlas of anatomy and treatment of midclavicular fractures. *Clin Orthop Relat Res.* 1968;58:29–42.
6. Mckee MD, Wild LM, Schemitsch EH. Midshaft malunions of the clavicle. 2003;85(5):790–7.
7. Zlowodzki M, Zelle BA, Cole PA, Jeray K, Mckee MD. Evidence-Based Orthopaedic Trauma Working Group. Treatment of acute midshaft clavicle fractures: Systematic review of 2144 fractures: On behalf of the Evidence-Based Orthopaedic Trauma Working Group. *J Orthop Trauma.* 2005;19(5):504–7.
8. Assobhi JEH. Reconstruction plate versus minimal invasive retrograde titanium elastic nail fixation for displaced midclavicular fractures. *J Orthop Traumatol.* 2011;12(4):185–92.
9. Chen YF, Wei HF, Zhang C, Zeng BF, Zhang CQ, Xue JF. Retrospective comparison of titanium elastic nail (TEN) and reconstruction plate repair of displaced midshaft clavicular fractures. *J Shoulder Elbow Surg.* 2012;21:495–501.
10. Assobhi JEH. Reconstruction plate versus minimal invasive retrograde titanium elastic nail fixation for displaced midclavicular fractures. *J Orthop Traumatol.* 2011;12(4):185–92.

Author biography

Sumit Jain Sethia, 3rd Year Resident

Vinod K Gautam, Professor and HOD

Vishal M Mehta, Assistant Professor

Sagar R Kothiya, Senior Resident

Cite this article: Sethia SJ, Gautam VK, Mehta VM, Kothiya SR. To compare outcome of minimally invasive Anterograde Titanium Elastic Nailing (RTEN) with that of a standard plating technique for the treatment of displaced Midshaft Clavicular Fracture (MSCFs).. *Indian J Orthop Surg* 2020;6(4):341-346.