



Original Research Article

A study comparing the efficacy of a combination of arthroscopic capsular release with sub acromial decompression, rotator interval release along with manipulation under general anesthesia and only manipulation under general anesthesia in the treatment of shoulder primary adhesive capsulitis

D S Bhamare¹, Kenchi Charith Nagarjun^{1,*}, Sai Kishan Sirasala¹, Purvam Jivrajani¹, Girish Nathani

¹Dept. of Orthopaedics, Dr. D.Y. Patil Medical College and Research Centre, Pune, Maharashtra, India



ARTICLE INFO

Article history:

Received 27-10-2020

Accepted 05-11-2020

Available online 30-12-2020

Keywords:

Adhesive capsulitis

Arthroscopic capsular release

Sub-acromial decompression

Manipulation under general

anesthesia

ABSTRACT

Introduction: Adhesive capsulitis is one of the shoulder's most common benign disorders. Its etiology varies from post-traumatic, association with diabetes and hypothyroidism to idiopathic. According to many research studies it is a self-limiting condition, according to its natural history it takes around 9 months to 2 years to resolve. Patient has to suffer the morbidity until then. To hasten the resolving process many treatment methods have been proposed ranging from non-invasive types like physiotherapy and manipulation under GA to minimally invasive types like local infiltration of steroid, platelet rich plasma, hyaluronic acid and arthroscopic capsular release. In this study a comparison has been made between the efficacy of combination of arthroscopic capsular release with sub acromial decompression, rotator interval release plus MUGA and only MUGA. The results obtained in the study are also discussed and compared with the existing literature.

Materials and Methods: An prospective interventional study of 40 patients aged between 30 to 60 years suffering from primary adhesive capsulitis refractory to treatment with physiotherapy [Dr. Brian Dierckman protocol] and analgesics for a period of 6 months, hence treated with combination of arthroscopic adhesiolysis with sub acromial decompression, rotator interval release plus MUGA and only MUGA was done. Patients have been randomly allocated into 2 groups (20 patients in each group) by simple random sampling using chits. The outcome of the patients in each group has been observed and followed up to a period of 6 months.

Result: Statistically there is a significant difference between the outcomes of only MUGA and combination of arthroscopic adhesiolysis with sub acromial decompression, rotator interval release and MUGA. Arthroscopic adhesiolysis with sub acromial decompression, rotator interval release and MUGA shows superior results in both the Oxford shoulder score and visual analogue scale from 1 month follow up to 6 months follow up.

Conclusion: This study hence-forth brings the superior efficacy of combination of arthroscopic capsular release with sub acromial decompression, rotator interval release and MUGA compared to only MUGA over a follow up period of 6 months in a study group of 40 patients who are refractory to conservative treatment for 6 months.

© This is an open access article distributed under the terms of the Creative Commons Attribution License (<https://creativecommons.org/licenses/by/4.0/>) which permits unrestricted use, distribution, and reproduction in any medium, provided the original author and source are credited.

1. Introduction

In 3 percent-5 percent of the general population annually adhesive capsulitis (AC) occurs. The most common type of adhesive capsulitis of shoulder is Idiopathic.

* Corresponding author.

E-mail address: kcharithnagarjuna@gmail.com (K. C. Nagarjun).

Diabetes mellitus, Disorders of thyroid gland, Dupuytren's contractures, autoimmune disorders, treatment of breast malignancies, trauma and surgery are the other common conditions to which this has been attributed.^{1,2}

The regular care and control of the condition includes the usage of NSAIDs, local corticosteroid injections, physiotherapy, hydro dilation, arthroscopic release, and manipulation under anesthesia. Our aim is therefore to study and compare the clinical efficacy of the capsule's manipulation under General Anesthesia and Combination of Arthroscopic Release with Sub acromial decompression, Rotator interval release, and Manipulation under General Anesthesia in the treatment of Shoulder Primary Adhesive Capsulitis.

2. Materials and Methods

A prospective interventional study was conducted from June 2018 to June 2020 with a sample size of 40 patients who were diagnosed with primary adhesive capsulitis of shoulder.

Age group of participants was 30 to 60 years. All patients with comorbidities were excluded from study. Patients were initially treated conservatively with analgesics and physiotherapy with Dr. Brian Dierckman protocol for a good period of 6 months. Patients who have not improved with conservative treatment were randomly allocated with simple random sampling into 2 groups.

Group 1: Who were treated with only manipulation under general anesthesia.

Group 2: Who were treated with a combination of arthroscopic release of capsule with sub acromial decompression, rotator interval release plus manipulation under general anesthesia.

20 cases were included in each group. Pre-procedural and post-procedural limitation of activities of daily living of the patients due to frozen shoulder is evaluated with Visual Analogue Scale[VAS] and Oxford Shoulder Scores[OSS]. Data was collected and analyzed by SPSS software. Anova tests were applied to compare the scores obtained from 2 groups.

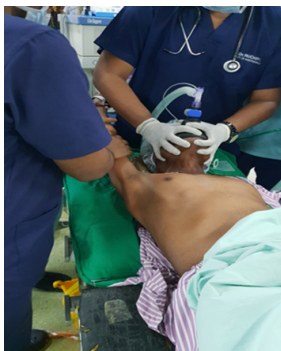

Fig. 1:

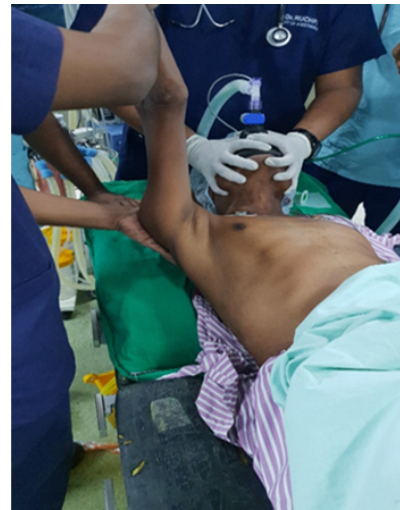

Fig. 2:

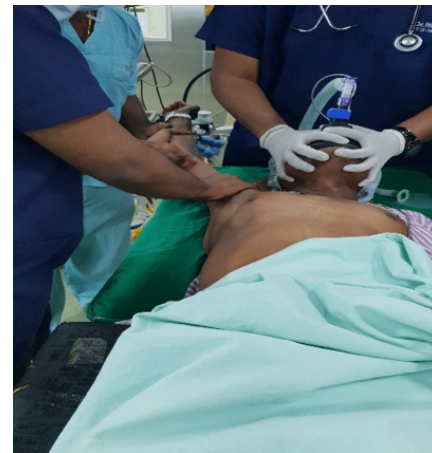

Fig. 3:

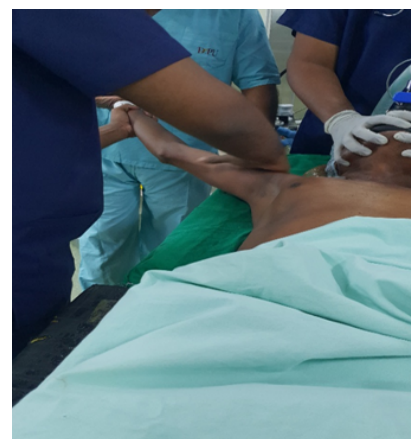

Fig. 4:

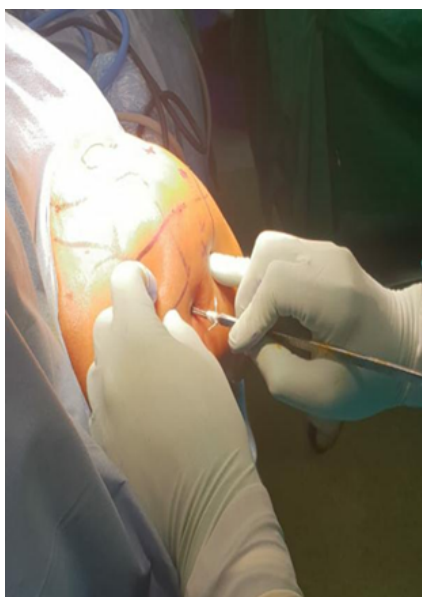

Fig. 5:



Fig. 6:

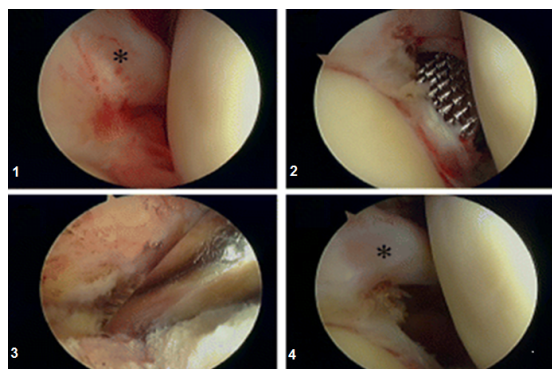


Fig. 7: * Long head of biceps.

Procedure of an arthroscopic adhesiolysis of frozen shoulder.

1. Arthroscopic picture showing long head of biceps[LHB] with synovium over coracohumeral ligament.
*Asterisk is LHB.
2. Rasp is used outside the labrum along the neck of glenoid bone.
3. Sub acromial decompression performed with the help of an abradar arthroscopically.
4. After releasing the capsule arthroscopically coracohumeral ligament attached to long head of biceps is removed and widening of joint space is done.

3. Results

1. Most of the study population were female (24) while males were 16 in number. No significant association was found between gender among both the groups.
2. Right side (19) and left side (21) were comparably affected in study population. Right was dominant side in most of the patients undergoing ACR with SAD, RIR plus MUGA and only MUGA.
3. Mean age of patients was 47.95 years with standard deviation of 6.7.

Pre-procedural and post-procedural mean [Including both only MUGA and combination of ACR with SAD, RIR plus MUGA] of VAS and OSS at 1 week, 1 month, 3 months and 6 months follow up is given below.

1. Pre-procedural mean OSS was 49.9, mean OSS at 1 week, 1 month, 3 months and 6 months follow up was 42.4, 35.4, 29.7, 23.7 respectively. gradual decline in OSS was observed with respect to time.
2. Decreasing trend of mean VAS was observed with respect to time interval, mean pre-procedural VAS was 7.13 while post procedural VAS was 4.8

3.1. Week follow-up

1. Mean OSS in MUGA was 44.4 while in ACR with SAD, RIR plus MUGA was 40.55.
2. Mean VAS in MUGA was 3.2 while in ACR with SAD, RIR plus MUGA was 2.3
3. Significant association was found in 1 week follow up VAS score and OSS among both methods.

3.2. Month follow-up

1. Mean OSS in MUGA was 39.2 while in ACR with SAD, RIR plus MUGA was 31.6.
2. Mean VAS in MUGA was 2.6 while in ACR with SAD with MUGA was 1.
3. Significant association was found in 1 month follow up VAS score and OSS among both methods.

Table 1: Comparison of mean OSS and VAS among both procedures for treatment of shoulder primary adhesive capsulitis. (Pre-procedural)

Oxford shoulder score pre-procedural.	Mean	Std. deviation	P value
MUGA	49.7	3.326	0.75
ACR with SAD with MUGA	50.1	4.459	
Total	49.9	3.888	
VAS score pre-procedural.	Mean	Std. deviation	P value
MUGA	6.65	0.933	0.005
ACR with SAD with MUGA	7.6	1.095	
Total	7.13	1.114	

Mean OSS in MUGA was 49.7 while in ACR with SAD, RIR plus MUGA was 50.1.

Mean VAS in MUGA was 6.65 while in ACR with SAD, RIR plus MUGA was 7.6.

Significant association was found in pre procedural VAS score among both methods.

Table 2: Comparison of mean OSS and VAS among both procedures in the treatment of shoulder primary adhesive capsulitis. (3 month follow up)

OSS at 3 month follow up.	Mean	Std. deviation	P value
MUGA	34.78	4.4	0.00
ACR with SAD with MUGA	24.35	3.02	
Total	29.71	6.474	
VAS at 3 month follow up.	Mean	Std. Deviation	P value
MUGA	1.94	0.873	0.00
ACR with SAD with MUGA	0.47	0.514	
Total	1.23	1.031	

Mean OSS in MUGA was 34.78 while in ACR with SAD, RIR plus MUGA was 24.35.

Mean VAS in MUGA was 1.94 while in ACR with SAD, RIR plus MUGA was 0.47.

Significant association was found in 3 month follow up in VAS score and OSS among both methods.

4. Discussion

A comparative Study comparing the efficacy of arthroscopic capsular release with sub acromial decompression, rotator interval release along with manipulation under general anesthesia and only manipulation under general anesthesia in the treatment of shoulder primary adhesive capsulitis. In the treatment of a frozen shoulder, there are many popular strategies: ranging from supervised neglect [Dierecks RL et al.,]³ physiotherapy [Donner et al.,]⁴ [Russel et

Table 3: Comparison of mean OSS and VAS among both procedures in the treatment of shoulder primary adhesive capsulitis. (6 month follow up)

OSS at 6 month follow up.	Mean	Std. deviation	P value
MUGA	30	4.442	0.00011
ACR with SAD with MUGA	17.94	2.968	
Total	23.79	7.149	
VAS at 6 month follow up.	Mean	Std. Deviation	P value
MUGA	1.47	0.8	0.000041
ACR with SAD with MUGA	0.29	0.47	
Total	0.88	0.88	

Mean OSS in MUGA was 30 while in ACR with SAD, RIR plus MUGA was 17.94.

Mean VAS in MUGA was 1.47 while in ACR with SAD, RIR plus MUGA was 0.29.

Significant association was found in 6 month follow up VAS score and OSS among both methods.

al.,]⁵ corticosteroid infiltration, [Carrette S]⁶, Ryabs I,⁷ Manipulation Under Anaesthesia (MUA) [Kivimäki J et al.,]⁸ Arthroscopic Capsular Release (ACR) [Beimers L et al.,]⁹ arthrographic capsular distension [Buchbinder R et al.,]¹⁰ and stretching devices [Ibrahim M et al.,].¹¹ The best regimen for treatment has not been developed yet.

Conservative care appears to be appropriate for most cases, taking into account all this, and nearly complete recovery happens in two or three years.¹² Most scholars note that failure of at least 6 to 12 months of effective non-operational therapy is a sign for more invasive treatments.¹³ However, as more invasive procedures are performed early in the disease, it is debated whether the duration of the disease will be reduced.¹⁴

A Dennis L et al.,¹⁴ research survey among health care specialists (orthopaedic surgeons, general physicians, physiotherapists) revealed that in the painful phase, most professionals suggested non-operative treatment, including oral analgesia and physiotherapy. Most of them focused on professional experience and training rather than published research to choose treatment. MUGA is comparatively straightforward to implement and time-saving. ACR is visually regulated, but physically more challenging, time-consuming, and has its own unique dangers (e.g. chondrolysis due to coagulation thermal heat, damage to the axillary nerve). In comparison, a combination of partial ACR accompanied by gentle shoulder joint manipulation seems to be a secure alternative. This significantly lowers dangers associated with MUGA alone, since the manipulation requires less force. For such a

mixed treatment, a specific indication is not obvious, but is recommended for most patients. Hence, our study helps in providing a statistical significance in comparing the efficacy of combination of arthroscopic capsular release with SAD, RIR plus MUGA and only MUGA in the management of primary adhesive capsulitis of shoulder.

5. Conclusion

At the end of this study, it is concluded that a combination of arthroscopic capsular release with sub acromial decompression, rotator interval release along with MUGA has a better outcome in comparison to only MUGA in the treatment of shoulder primary adhesive capsulitis which has not responded to 6 months of conservative treatment with analgesics and physiotherapy.

6. Source of Funding

None.

7. Conflict of Interest

None.

References

1. J N. Adhesive shoulder capsulitis. A review of the pathologic observations of shoulder peri-arthritis. *J Bone Surg Joint Am.* 1945;27:211–22.
2. Codman EA. The shoulder. Boston: Thomas Todd; 1934.
3. Diercks RL, Stevens M. Gentle thawing of the frozen shoulder: A prospective study of supervised neglect versus intensive physical therapy in seventy-seven patients with frozen shoulder syndrome followed up for two years. *J Shoulder Elbow Surg.* 2004;13(5):499–502.
4. Doner G, Guven Z, Atalay A, Celiker R. Evaluation of Mulligan's technique for adhesive capsulitis of the shoulder. *J Rehabil Med.* 2013;45(1):87–91.
5. Russell S, AJariwala, Conlon R, Selfe J, JRichards, MWalton, et al. A blinded, randomized, controlled trial assessing conservative management strategies for frozen shoulder. *J Shoulder Elbow Surg.* 2014;23(4):500–7.
6. Carette S, Moffet H, Tardif J, Bessette L, Morin F, Frémont P, et al. Intraarticular corticosteroids, supervised physiotherapy, or a combination of the two in the treatment of adhesive capsulitis of the shoulder: A placebo-controlled trial. *Arthritis Rheum.* 2003;48(3):829–38.
7. Ryans I. A randomized controlled trial of intra-articular triamcinolone and/or physiotherapy in shoulder capsulitis. *Rheumatol.* 2005;44(4):529–35.
8. Kivimäki J, Pohjolainen T, Malmivaara A, Kannisto M, Guillaume J, Seitsalo S, et al. Manipulation under anesthesia with home exercises versus home exercises alone in the treatment of frozen shoulder: A randomized, controlled trial with 125 patients. *J Shoulder Elbow Surg.* 2007;16(6):722–6.
9. Beimers L, Murell GAC. Arthroscopic capsular release for idiopathic adhesive capsulitis. *J Bone Joint Surg Am.* 2013;94:1208–16.
10. Buchbinder R, Green S, Youd JM, Johnston RV, Cumpston M. Arthrographic distension for adhesive capsulitis (frozen shoulder). *Cochrane Database Syst Rev.* 2008;007005(1):32–9.
11. Ibrahim M, Donatelli R, Hellman M, Echternach J. Efficacy of a static progressive stretch device as an adjunct to physical therapy in treating adhesive capsulitis of the shoulder: a prospective, randomised study. *Physiother.* 2014;100(3):228–34.
12. Kelley MJ, Shaffer MA, Kuhn JE, Michener LA, Seitz AL, Uhl TL, et al. Shoulder Pain and Mobility Deficits: Adhesive Capsulitis. *J Orthop Sports Phys Ther.* 2013;43(5):1–31.
13. Robinson CM, Seah KTM, Chee YH, Hindle P, Murray IR. Frozen shoulder. *J Bone Joint Surg Br.* 2012;94(1):1–9.
14. Harris DJO, Biggs DJ, Fitisialos DP, Mackay M. The resistant frozen shoulder. Manipulation versus arthroscopic release. *Clin Orthop Relat Res.* 1995;(319):238–48.

Author biography

D S Bhamare, Professor

Kenchi Charith Nagarjun, Junior Resident

Sai Kishan Sirasala, Junior Resident

Purvam Jivrajani, Junior Resident

Girish Nathani, Senior Resident

Cite this article: Bhamare DS, Nagarjun KC, Sirasala SK, Jivrajani P, Nathani G. A study comparing the efficacy of a combination of arthroscopic capsular release with sub acromial decompression, rotator interval release along with manipulation under general anesthesia and only manipulation under general anesthesia in the treatment of shoulder primary adhesive capsulitis. *Indian J Orthop Surg* 2020;6(4):336-340.