



Original Research Article

Study of implant removal due to various indications in a tertiary care hospital - A retrospective Study

Pagadpally Girish¹, T Sundararajan^{1,*}, Mahendhira Varman J¹, F Abdul Khader¹¹Dept. of Orthopaedics, Shvi Sathya Sai Medical College & Research Institute, Ammapettai, Tamil Nadu, India

ARTICLE INFO

Article history:

Received 23-08-2020

Accepted 05-11-2020

Available online 30-12-2020

Keywords:

Implant failure

Fracture

Implant

Infected

Implant removal

ABSTRACT

Introduction: Fracture management have improve along with the advance of technology. Depending on bone and site of fracture, latest contour plates and nails are available. Even after the advance in implant material. On the other hand, controversy still persist among surgeons on cardinal indication required for implants removal. Implant removal mainly depend on the patient's symptoms. The aim of the study to detect the main causes for implant removal.

Objective: To survey the primary cause for implant removal along with detecting which implants requires removal in orthopaedic surgeries.

Materials and Methods: All adult patients who were admitted for implant removal in the orthopaedic ward.

Results: A study group of 89 patients, 73 males and 16 females. The mean age of the study group was 38 years. The causes for implant removal were sorted into four categories: 1) Pain/discomfort, 2) Infection, 3) implant failure or resorption 4) Elective (patient's choice). Depending on our survey, implants frequently removed are distal Tibial/Ankle plates (14.45%), Femoral Intramedullary (IMIL) nails (13.25%), Olecranon both wires and plates (12.04%), Tibial IMIL nails and Patellar tension band wires (9.53%).

Discussion and Conclusion: Clinical indications for implant removal has not been properly specified. According to our study pain / discomfort was the most dominant reason for implant removal (37.1%). The second common indication was infection (26.96%) removing the implant was mandatory. Third indication was Implant failure in symptomatic patients as a result of poor quality implants, inadequate or faulty implant and uncooperative patients. Fourth indication was on patients demand. Implant removal is a laborious surgery as factors like bone ingrowth and wear of the implants which makes it an onerous removal.

© This is an open access article distributed under the terms of the Creative Commons Attribution License (<https://creativecommons.org/licenses/by/4.0/>) which permits unrestricted use, distribution, and reproduction in any medium, provided the original author and source are credited.

1. Introduction

Fracture management have improve along with the advance of technology. Depending on bone and site of fracture, latest contour plates and nails are available. Due to the advancement, various options are available for surgical management for fracture in this century.^{1,2} Especially in the design of the implants like Intramedullary (IM) nails, plates, screws especially for peculiar bone frames and enhancing rate of union and the efficacy of the treatment. Titanium

alloys and stainless steels are most common material used in manufacturing of orthopaedic implants,^{3,4} as it is lighter in weight and resistant to infection.^{3,4} In some situation, implants after fulfilling its purpose may be detected as a foreign object by the body itself and produce reaction against it.

Removal of asymptomatic implant has still some controversy among surgeons all over the world due absence of evidence based guidelines.^{5,6} A standard protocol is followed to remove the implants after the fracture bones unites, in children,⁷ as a caution not to interrupt growth plates, or infuse foreign body reaction, secondary infection

* Corresponding author.

E-mail address: vrthothocare@gmail.com (T Sundararajan).

and corrosion.⁷ The cardinal for implant removal are for pain relief and for functional improvement. The procedure is a laborious surgery and may lead to risks of neurovascular injury or refractures.^{8–11} Our study is to survey the primary indications for implant removal along with identifying which implants requires implant removal in orthopaedic surgeries

2. Materials and Methods

A Retrospective cohort study done on datas of 89 patients admitted for implant removal from January 2017 to January 2020. About 112 patients were selectively chosen. Patients were selected based on inclusion criteria. The inclusion criteria were adult patients admitted for implant removal in the wards of orthopaedic department, with age ranging between 18 to 55 years, all patients should have all the required investigations performed such as routine blood investigation, xray of the site of implant removal at the time of admission. Written documentation of acquired consent for the surgery, post operatively management and discharge summary should be present, follow ups and the outcome after the removal of the study group should be noted. The exclusion criteria were children below 16 years, previous surgeries like K-wire fixation, external fixator in situ, cases with joint prostheses in situ, loss of important documented data mention in the inclusion criteria. The 23 patients were excluded for reasons of improper documentation and having addition comorbidities (such as diabetic with irregular taking of medication).

3. Results

In 89 Patients, 73 males (82%) and 16 were females (18%). Their ages ranged from 18 to 55 years with a mean age of 38 years. The prime causes for implant removal were found in four categories: 1) Pain/discomfort, 2) Infection, 3) Implant failure or resorption 4) Elective (patient's choice) [Table 1].

1. 33 patients had pain / discomfort / prominence (37.1%). The duration from fracture fixation varied from 6 months to 84 months, an average of 38 months. According to our survey frequently removed implants were Patella tension band wiring (TBW) – 12, Olecranon TBW/plates – 9, Distal Humeral plates – 8 and Femoral IM nail – 4. The mean duration of hospitalization of the studied patients were 7 days with consecutively 6 months follow-ups, the outcome showed 30 out of 33 patients acquired complete pain relief (90.9%) and remaining 3 patients still had with mild pain / discomfort (9.09%).
2. 24 patients (26.96%) acquired implant removal due to infected implants insitu. The duration from fracture fixation varied from 2 months to 56 months, an average of 47.57 months. 23 patients fracture appeared to be united while removing the infected implants, one

patient's fracture appeared not united and managed furtherly with external fixators. According to our survey frequently removed implants were Distal Tibial/Ankle plates and screws - 11, Proximal Tibial plates - 9 and Olecranon plates - 4. Mean duration of hospitalization of the studied patients were 7 days with consecutively follow ups, the outcome showed 21 out of 24 patients acquired a complete recovery from infection (87.5%) while 3 patients developed chronic osteomyelitis with discharge. [Chart 2 Figures 2 and 3].

3. 8 patients (8.98%) acquired implant removal along with revision osteosynthesis on the account of implant failure. The average duration from primary procedure was 2-12 months. According to our survey frequently removed implants were Femoral IMIL nails - 2, Distal Tibial plates -3, humeral shaft dynamic compression plate - 1 and cannulated cancellous screws in the Femoral neck -2 [Chart 3, Figure 4]. The follow-up after a month from fixation surgery revealed an extensive bone resorption from under both bones forearm plating [Figure 5] on further management, both the plates were removed. On subsequent follow-up, there were no further complications.
4. 24 patients (26.97%) acquired removal of their implants on their own will, in spite of being asymptomatic [Chart 4].

Further analysis of the data, there were no major vascular injury or refracture during any implant removal. A patient after getting distal humeral plates removed showed ulnar nerve palsy and recovered on further management of physiotherapy. An infected Tibial IMIL nail developed into chronic osteomyelitis which was manage by through wound wash and sequestrectomy.

4. Discussion

The study was to detect the main causes for implant removal along with detecting which implants requires implant removal in orthopaedic surgeries The study was done from documented data of 89 adult patients who were admitted for implant removal which were selectively chosen from 112 adult patients data from a tertiary care hospital.

AO association recommends on timely implant removal,^{12,13} Clinical indications for implant removal has not been properly specified. Implant removal is a laborious surgery as factors like bone ingrowth and wear of the implants which makes it an onerous removal and may lead to risks of neurovascular injury or refractures.^{8–11}

In the study we found male preponderance, but the majority patients were male for implant removal (82%), similar finding were found one study showed a male preponderance (189 out of 275 patients)¹⁴ and another study showed 30 (75%) were males out of 40 patients.¹⁵ There appears to be a strong male preponderance in implant

removal surgeries. The study would be much accurate if the ratio of male to female patients would have been equal. In our study 30 out of 33 patients acquired complete pain relief (90.9%) and remaining 3 patients still had with mild pain / discomfort (9.09%) which were similarly noted in other studies.^{16–18} In another study after implant removal of 51 patients who were asymptomatic, ten (20%) patients developed symptoms after the removal.¹⁹ According to our study pain / discomfort was the most cardinal reason for implant removal (37.1%) similar result were noted in other studies.^{20,21} The second common indication was infection (26.96%) removing the implant was mandatory. A study made a statement that 5% of all implant removal may get infected.²² Third indication was Implant failure in symptomatic patients as an output of poor quality implants, inadequate or faulty implant and uncooperative patients 3 other studies showed similar result.^{23–25} Fourth indication was on patients demand.

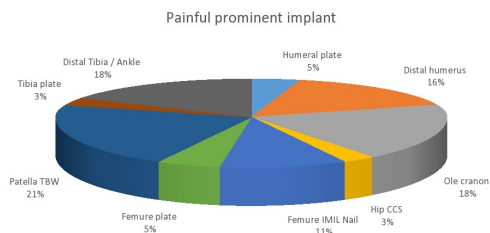


Chart 1:

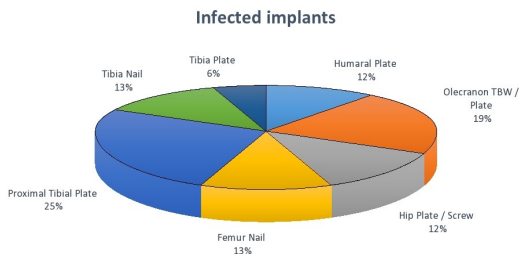


Chart 2:

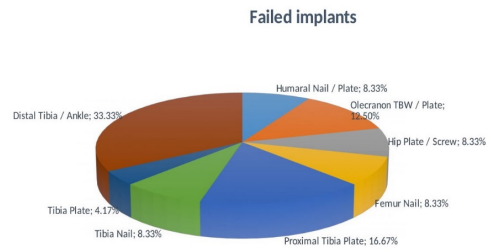


Chart 3:

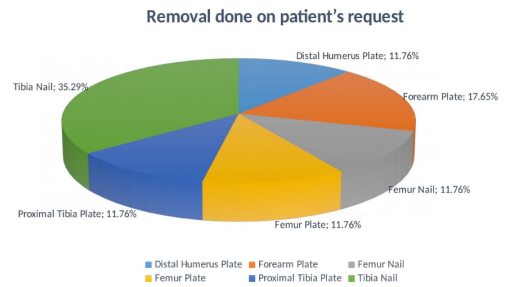


Chart 4:

5. Conclusion

Symptomatic patients requires compulsory implant removal. Pain and protruding implants are the most dominant reason for implant removal. Infection comes to the next then comes implant failure, bone resorption and on patient's demand. The implants having direct contact with weight bearing require removal.³ Implant removal is a laborious surgery as factors like bone ingrowth and wear of the implants which makes it an onerous removal. There is no certainty of 100% relief of symptom after implant removal.

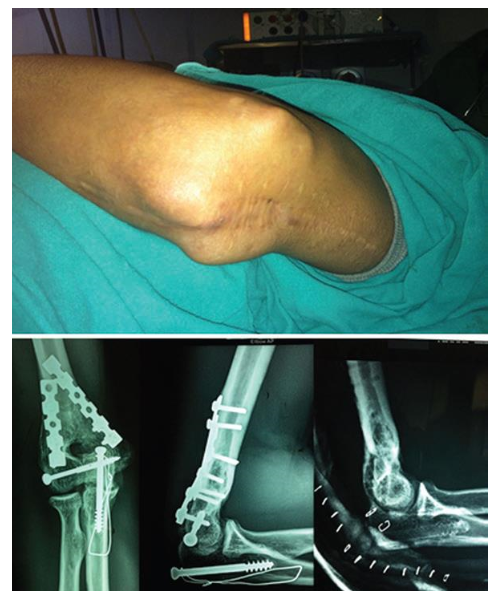

Fig. 1:

Table 1: Distribution of cases

S. No.	Type of implant	Prominent implants	Infected implants	Implant failure	Elective	Other reasons
1.	Humeral diaphysis nail/plate	2	2	1		
2.	Distal humeral plates	6			2	
3.	Olecranon TBW/plates	7	3			
4.	Forearm plates				3	1
5.	Hip plates and screws	1	1	2		
6.	Femoral nails	4	2	3	2	
7.	Femoral plates	2			2	
8.	Patella TBW	8				
9.	Proximal tibial plates		4		2	
10.	Tibial nails		2		6	
11.	Tibial plates	1	1			
12.	Distal tibial / ankle implants	2	8	2		

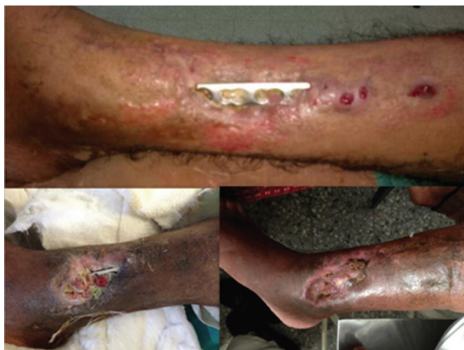

Fig. 2:

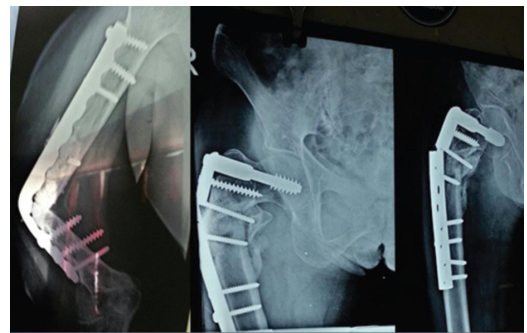


Fig. 4:

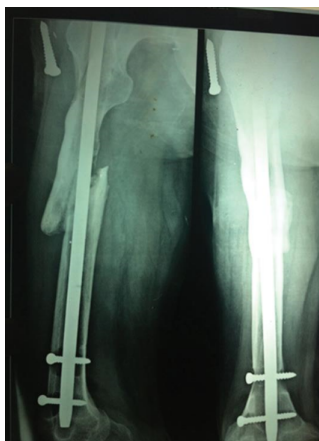

Fig. 3:

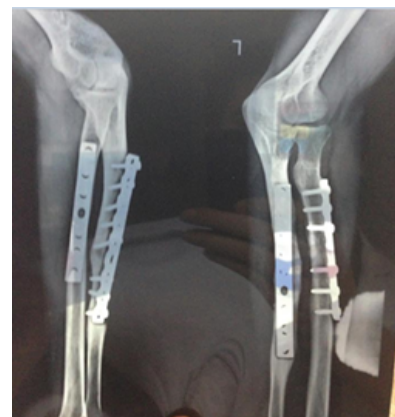

Fig. 5:

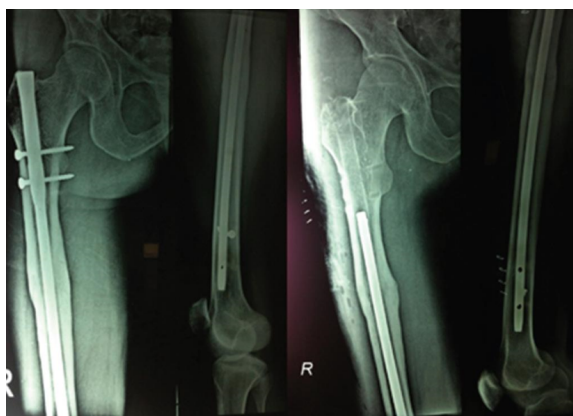


Fig. 6:

Table 2: AO guidelines for timing of implant removal in uncomplicated fracture healing

S. No.	Bone Fracture	Time after implantation in months
1.	Malleolar fractures	8-12
2.	Tibial pilon	12-18
3.	Tibial shaft plate	12-18
4.	Tibial intramedullary (IM) nail	18-24
5.	Proximal tibia	12-18
6.	Patella TBW	8-12
7.	Femoral condyles	12-24
8.	Femoral shaft single plate	24-36
9.	Femoral shaft double plates	18-24
10.	Femoral intramedullary (IM) nail	24-36
11.	Peritrochanteric and femoral neck fractures	12-18
12.	Pelvis	From 10 th month
13.	Upper extremity	12-18

Source: Canale and Beaty, eds. Campbell's Operative Orthopedics 11/e

6. Source of Funding

Nil.

7. Conflicts of Interest

Nil.

References

- Sahito B, Ahmed N, Faheem NB, Memon A, Mehboob G. Indication and complications for implant removal in femoral fractures. *J Pak Orthop Association*. 2012;24:115–35.
- Vos DI, Verhofstad MHJ. Indications for implant removal after fracture healing: a review of the literature. *Eur J Trauma Emerg Surg*. 2013;39(4):327–37.
- Krischak GD, Gebhard F, Mohr W, Krivan V, Ignatius A, Beck A, et al. Difference in metallic wear distribution released from commercially pure titanium compared with stainless steel plates. *Arch Orthop Trauma Surg*. 2004;124(2):104–13.
- Serhan H. Is galvanic corrosion between titanium alloy and stainless steel spinal implants a clinical concern? *Spine J*. 2004;4(4):379–87.

- Loder RT, Feinberg JR. Orthopaedic implants in children: survey results regarding routine removal by the pediatric and nonpediatric specialists. *J Pediatr Orthop*. 2006;26(4):510–9.
- Molster A, Behring J, Gjerdet NR, Ekeland A. Fjerning av osteosyntesemateriale. *Tidsskrift-Norske Laegeforening*. 2002;122(23):2274–6.
- Schmittenebecher PP. Implant removal in children. *Eur J Trauma Emerg Surg*. 2013;39(4):345–52.
- Beaupré GS, Csongradi JJ. Refracture Risk After Plate Removal in the Forearm. *J Orthop Trauma*. 1996;10(2):87–92.
- Davison BL. Refracture following plate removal in supracondylar-intercondylar femur fractures. *Orthopedics*. 2003;26(2):157–9.
- Langkamer VG, Ackroyd CE. Removal of forearm plates. A review of the complications. *J Bone Joint Surg Br*. 1990;72(4):601–4.
- Sanderson PL, Ryan W, Turner PG. Complications of metalwork removal. *Injury*. 1992;23(1):29–30.
- Busam ML, Esther RJ, Obremskey WT. Hardware Removal: Indications and Expectations. *J Am Acad Orthop Surg*. 2006;14(2):113–20.
- Hanson B, van der Werken C, Stengel D. Surgeons' beliefs and perceptions about removal of orthopaedic implants. *BMC Musculoskelet Disord*. 2008;9(1):73.
- Shrestha R, Shrestha D, Dhoju D, Parajuli N, Bhandari B, Kayastha SR, et al. Epidemiological and outcome analysis of orthopedic implants removal in Kathmandu University Hospital. *Kathmandu Univ Med J*. 2013;11(2):139–43.
- Abidi SA, Umer MF, Ashraf SM, Mehdi SH, Ahmed SK, Shaikh IA, et al. Outcome of painful implant removal after fracture union. *Pak J Surg*. 2012;28(2):114–21.
- Keating JF, Orfaly R, O'Brien PJ. Knee Pain After Tibial Nailing. *J Orthop Trauma*. 1997;11(1):10–13.
- Brown CMC, Gustilo T, Shaw AD. Knee Pain After Intramedullary Tibial Nailing: Its Incidence, Etiology, and Outcome. *J Orthop Trauma*. 1997;11(2):103–5.
- Dodenhoff RM, Dainton JN, Hutchins PM. Proximal thigh pain after femoral nailing: causes and treatment. *J Bone Joint Surg Br*. 1997;79(5):738–41.
- sling TG, Hufner T, Hankemeier S, Zelle BA, Heine AM, Krettek C, et al. Femoral Nail Removal Should Be Restricted in Asymptomatic Patients. *Clin Orthop Relat Res*. 2004;423:222–6.
- Minkowitz RB, Bhadsavle S, Walsh M, Egol KA. J Bone Joint Surg Am. *J Bone Joint Surg Am*. 2007;89(9):1906–12.
- Brown OL, Dirschl DR, Obremskey WT. Incidence of Hardware-Related Pain and Its Effect on Functional Outcomes After Open Reduction and Internal Fixation of Ankle Fractures. *J Orthop Trauma*. 2001;15(4):271–74.
- Trampuz A, Widmer AF. Infections associated with orthopedic implants. *Curr Opin Infect Dis*. 2006;19(4):349–56.
- Zimri F, Mateen M. Broken orthopaedic implant: an experience at PIMS. *Ann Pak Inst Med Sci*. 2009;5(3):136–76.
- Peivandi MT, Yusof-Sani SM, Amel-Farzad H. Exploring the reasons for orthopedic implant failure in traumatic fractures of the lower limb. *Archives of Iranian medicine*. *Arch Iran Med*. 2013;16(8):478–82.
- Sharma AK, Kumar A, Joshi GR, John JT. Retrospective Study of Implant Failure in Orthopaedic Surgery. *Med J Armed Forces India*. 2006;62(1):70–2.

Author biography

Pagadpally Girish, Assistant Professor

T Sundararajan, Associate Professor

Mahendhira Varman J, Associate Professor

F Abdul Khader, Professor & HOD

Cite this article: Girish P, T Sundararajan, Varman J M, Khader FA. Study of implant removal due to various indications in a tertiary care hospital - A retrospective Study. *Indian J Orthop Surg* 2020;6(4):322-327.