



## Original Research Article

## Functional and Radiological outcome of Limb Reconstruction system (LRS) in infected nonunion of Tibia

Apser Khan<sup>1</sup>, Animesh Kumar Singh<sup>1,\*</sup>, S K Kaushik<sup>1</sup>, Sanjay Gupta<sup>1</sup>, Rahul Verma<sup>1</sup>

<sup>1</sup>Dept. of Orthopaedics, SRMS-IMS, Bhoji Pura, Uttar Pradesh, India



## ARTICLE INFO

## Article history:

Received 15-06-2020

Accepted 18-06-2020

Available online 19-09-2020

## Keywords:

LRS

Infected non-union

Bone regenerate

Resected bone

ASAMI score

## ABSTRACT

**Introduction:** Infected non-union of tibial diaphysis has been a challenging problem. Tibia being subcutaneous bone, fracture healing especially following compound fracture with any pre or postoperative infection leads to notorious non union. Though there have been various treatment modalities to deal with the condition, Limb reconstruction system (LRS) provides simple effective and versatile treatment modality where liberal resection of long segment of infected bone, can be reproduced by combining the masqueteel technique with the distraction osteogenesis. It's light weight and allows better wound management, makes it more patients compliant.

**Materials and Methods:** In this retrospective study, 20 patients of infected non-union of tibial diaphysis were treated by using the Limb reconstruction system during April 2017 to may 2019 at our institute. The final assessment was done upon only those patients who were followed for at least one year post-operatively, using Association for the Study and Application of Methods of Ilizarov (ASAMI) score.

**Results:** According to ASAMI score, bony results were excellent in 75%, good in 10%, fair in 5% and poor in 10% and functional results were excellent in 60%, good in 20%, fair in 10% and poor in 10% of patients. The mean bone resection was 7.3 cm, the mean duration of bone transport was 10.4 weeks, the mean bony union time was 11.1 weeks and the mean duration of consolidation of regenerate was 37.8 weeks.

**Conclusion:** The LRS is simple effective and versatile treatment modality in infected non-union of tibia. It not only provides bone transport, fusion of the bone ends and finally consolidation of the regenerate on itself but also facilitates in dealing with limb length discrepancies along with early mobilization and better wound management.

© 2020 Published by Innovative Publication. This is an open access article under the CC BY-NC license (<https://creativecommons.org/licenses/by-nc/4.0/>)

### 1. Introduction

The growing incidence of high velocity road traffic accident has lead to increased number of complex compound injuries, which subsequently has give rise to the greater number of infected non union cases.<sup>1</sup> Treatment of compound fracture of tibia has always been a challenging problem because of chances of delayed union, mal-union and infection. In 1-10 % of cases operated, implant and bone gets infected because of various reasons.<sup>2</sup> Chances of infection and non union are very high in tibia being subcutaneous bone, having less vascularity. Inability to achieve union in a fracture of long bone for a period of 8

to 9 months after the trauma due to persistent infection is supposed to be the infected non Union.<sup>3-5</sup> Many a times compound fracture tibia are managed by external fixator or internal fixation<sup>6,7</sup> by nail or plate with open or closed reduction, lands in infection that may be responsible for non-union. Bony ends become avascular due to thrombosis of micro-vasculature and haversian canaliculi system<sup>8</sup> and fracture fragment ends become sclerosed in a case of non-union. Many modalities have been devised to treat the infected non-union of long bones including external fixator, ilizarov ring fixator, antibiotic nails and external plates etc. The treatment duration in such cases becomes prolonged with multiple surgeries, disability and social stigma.<sup>9</sup> Due to prolonged immobilization various co-morbidities develop

\* Corresponding author.

E-mail address: [aks.ms.orth@gmail.com](mailto:aks.ms.orth@gmail.com) (A. K. Singh).

like stiffness and deformity at the adjacent joints, osteopenia, disuse atrophy and limb length discrepancy, posing various problems in treatment and outcome.<sup>10</sup> Recently limb reconstruction system has been used to treat the infected non-union after resection of infected and sclerosed bone at the fracture ends creating a bone gap, antibiotic spacer application and doing the bone transport from either end of the tibia. In this retrospective study we have assessed the functional and radiological outcome of LRS in the treatment of infected non-union of tibia.

## 2. Materials and Methods

We analysed 20 patients with infected non-union of tibial diaphysis treated by using the LRS after resection of infected and sclerotic bone at the fracture ends and doing bone transport from either end of tibia during April 2017 to May 2019 at SRMS Institute of Medical Sciences, Bareilly. Preoperative and monthly follow up post operative X-ray of the affected leg with AP and lateral view including knee and ankle joint were obtained and analysed till the completion of one year postoperatively. Preoperative X-rays were used to assess the length of resection of the infected and sclerosed bone. In the first stage thorough debridement of wound was done. Infected and fibrotic tissue was completely excised. Any implant Nail/Plate was removed. Infected bone was excised till the bleeding ends appear (paprika sign). Any sinus tract, if present was excised. Medullary canal was opened; end was reamed with flexible reamers. Length of excised fragment was measured and antibiotic spacer with appropriate antibiotic was put in place to fill gap. LRS was applied medially or antero-medially with three clamps. Wound was closed either primarily or flap cover was done in the same setting. Patients had been allowed ambulation with protected weight bearing and ROM exercise of the knee and the ankle joint was started on the very next day. Systemic antibiotic were continued for 4-6 weeks. After 4-6 weeks time, when infection got controlled and parameters like TLC, DLC, CRP, ESR came down to the normal level, the second stage surgery, in the form of antibiotic spacer removal and corticotomy at one suitable end of tibial metaphysis was done. A compression distraction device (CD device) was applied. Again patients were allowed protected weight bearing and ROM exercise of the knee and the ankle joint was started on the very next day. Distraction osteogenesis at the corticotomy site was started after 10 days, at the rate of 1 mm / day in 4 steps to fill the gap. Patients had been followed once monthly and X-ray was obtained to assess growth and maturation of the bony regenerate and range of movements at the ankle and the knee joints. After complete restoration of excised bone by the new regenerate, LRS was left in place till full consolidation of the bone regenerate. The union at the fracture ends was achieved by the compression at bony ends using CD device.

## 3. Results

Results of 20 patients were assessed (n=20), mean age 43.1 yrs (23-58 yrs), male: female ratio 5.6 : 1, average follow-up period 52.2 weeks, average bone resected 7.3 cm (3-12 cm), average duration of bone transport 10.4 weeks (4-17 weeks), an average union time of bone ends 11.1 weeks (8.5-12 weeks), average duration of consolidation of regenerate 37.8 weeks (34-40 weeks).

Bony results and functional results were assessed according to ASAMI Score.

Bony results excellent – 75%, good-10%, fair - 5% and poor – 10%.

Functional results were excellent - 60%, good- 20%, fair – 10% and poor – 10%.

Out of 20 patient, 1 patient developed severe equinus deformity at ankle joint and 1 patient had limb length discrepancy >3.5 cm. Six patient had superficial pin tract infection.

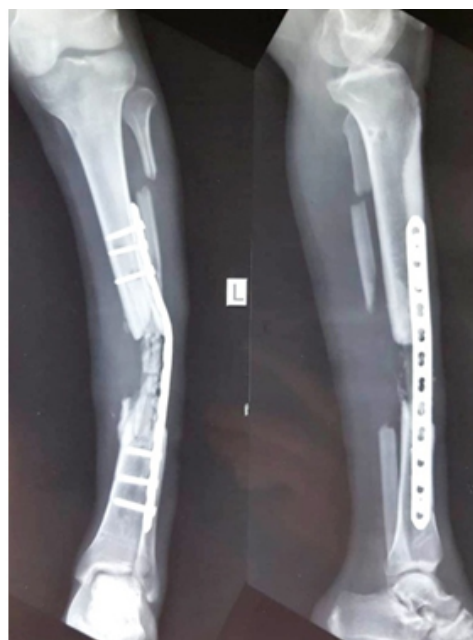

Fig. 1: Infected Non-union with implant failure

## 4. Discussion

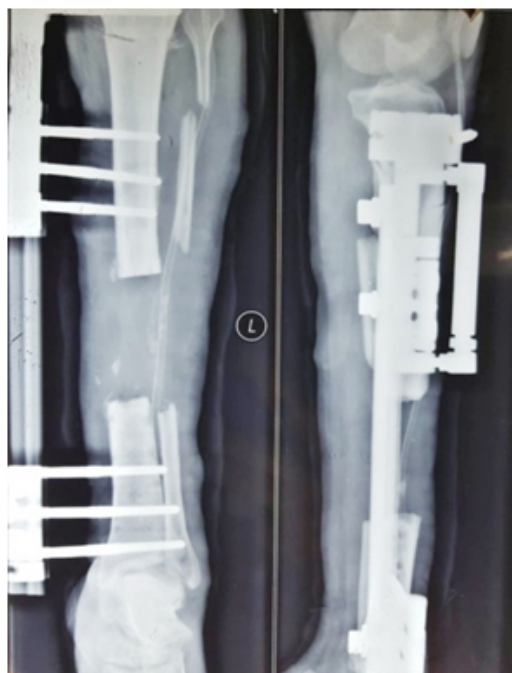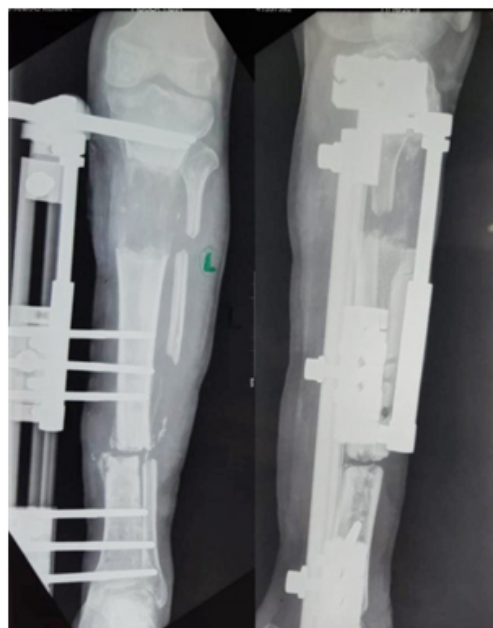
Management of infected non-union is aimed to control the infection and to promote union at the fracture site with a proper alignment of the fracture fragments along with the maintenance of normal length and restoration of movements at the adjacent joints and getting a fully functional and painless limb. The segment of infected bone was resected till the bleeding ends appear (paprika sign).<sup>11</sup> Distraction osteogenesis was done at the rate of 1 mm / day in 4 steps to fill the gap.<sup>12</sup> It took around 4 weeks to 17 weeks depending upon the length of excised bone.<sup>13</sup> In our Study treatment of

**Table 1:**

S. No.	Criteria	Results
1	Mean age	43.1 yrs
2	M:F	5.6:1
3	Average bone gap (after infected bone resection)	7.3 cm
4	Average duration of bone transport	10.4 wks
5	Average union time	11.1 wks
6	Average duration of consolidation of regenerate	37.8 wks

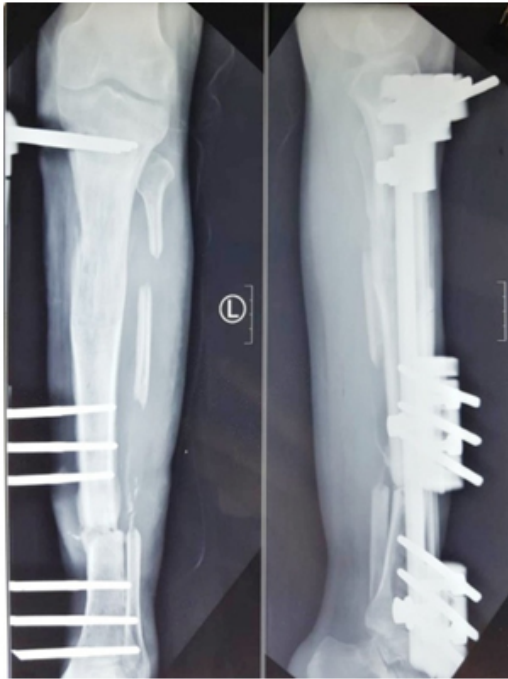**Table 2: Bony and functional outcome according to ASAMI score**

<b>Bony Outcome</b>			
S. No.	Results	No of Patient	Percentage
1	Excellent	15	75%
2	Good	2	10%
3	Fair	1	5%
4	Poor	2	10%
<b>Functional Outcome</b>			
S. No.	Results	No of Patient	Percentage
1	Excellent	12	60%
2	Good	4	20%
3	Fair	2	10%
4	Poor	2	10%

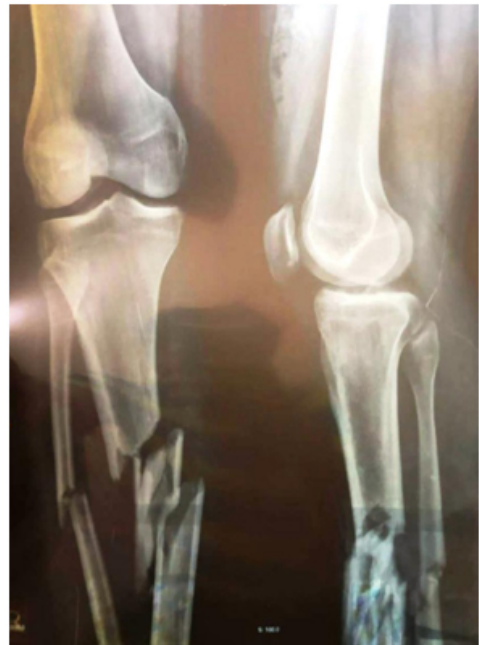**Fig. 2:** Resected infected bone segment with corticotomy**Fig. 3:** Bone transport with regenerate replacing resected bone length

infected non-union of tibia 90% patient showed successful Union in 8 to 12 weeks period which is comparable to other studies Garcia-Climbrelo et al,<sup>14</sup> Gajbhiye AI et al.,<sup>15</sup> and Patil S et al.<sup>16</sup> In majority of the patients range of motion was not much impaired. Average follow-up was for the 18 months ranging from 12 to 24 months study is comparable

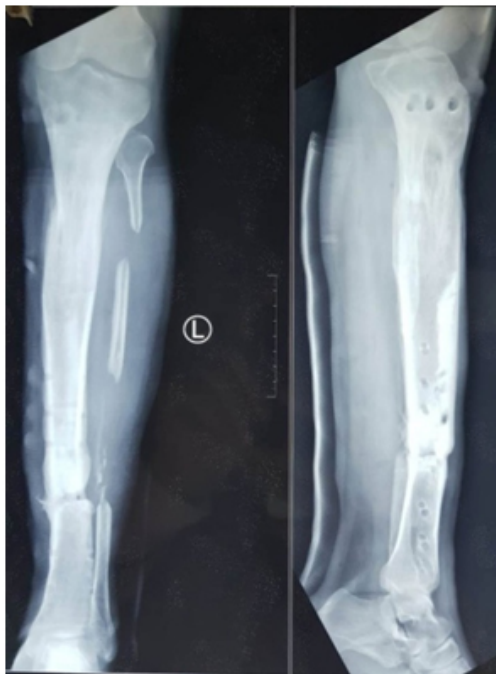
to Ajmera A et al.<sup>17</sup> Mean bone transport was 3 to 12 cm comparable to the other studies like Donnan L.T et al.<sup>18</sup> and Sen et al.<sup>19</sup> Mean duration of LRS application was 52.2 weeks. One patient had severe equines deformity at ankle joint as the patient did not comply with the ROM exercise. Another patient developed shortening of limb > 3.5 cm as



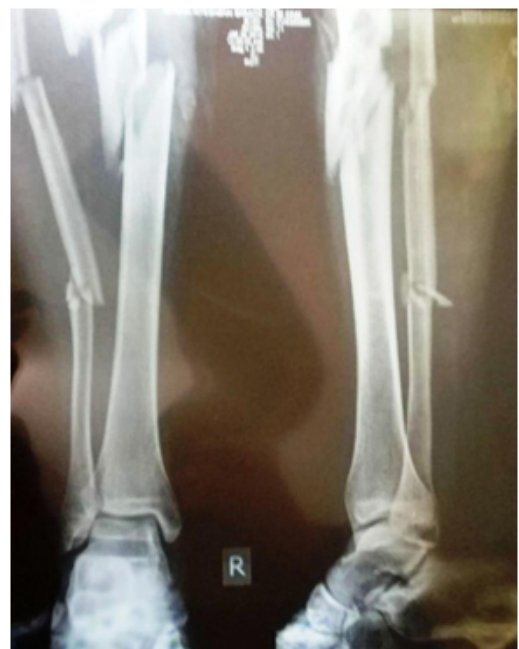**Fig. 4:** Regenerate consolidation with bone endsunion



**Fig. 6:** Comminuted tibial shaft fracture

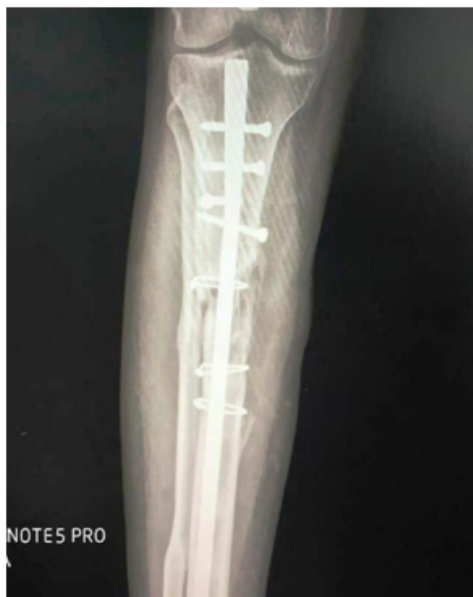

**Fig. 5:** Removal of LRS with application PTB

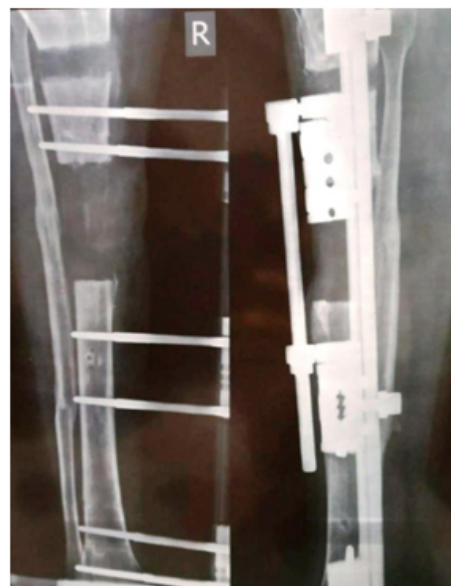

**Fig. 7:** Comminuted tibial shaft fracture

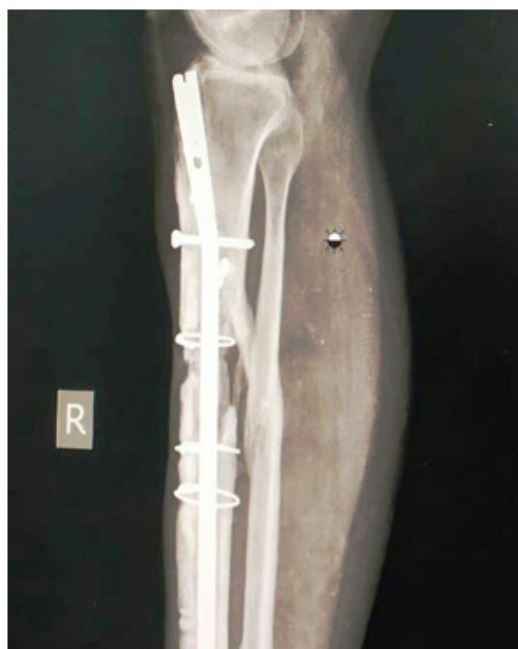



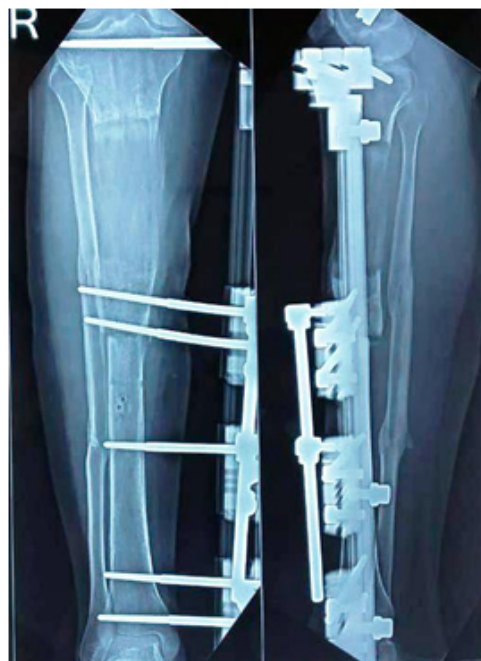**Fig. 8:** Tibial interlocking nail in situ



**Fig. 10:** Corticotomy with bone transport

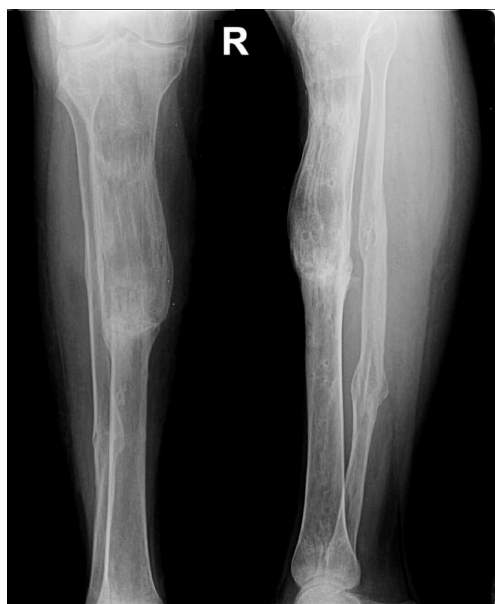

**Fig. 9:** Tibial interlocking nail in situ



**Fig. 11:** Bone transport with regenerate replacing resected bone length

he discontinued bone transport because of severe pain. One case developed loosening of the pin in which we had to re adjust the frame and change the pin. LRS is easy to handle and apply in comparison to ilizarov fixator, though that is also equally good to achieve union in infected non-union cases but LRS is compatible, light weighted simple design and short learning curve to apply. Wound care is easy and permits early mobilisation and rehabilitation. It provides more stability because of the tapered pins. Axial



**Fig. 12:** Removal of LRS and regenerate consolidation with bone ends union

compression can be achieved at the fracture site by using the compression-distraction device.

## 5. Conclusion

The LRS is simple effective and versatile treatment modality in infected non-union of tibia where iatrogenic resection of long segment of infected bone can be reproduced by combining the masquelet technique with the distraction osteogenesis. This mono-planer rail fixator not only provides corticotomy, bone transport, fusion of the bone ends and finally consolidation of the regenerate on itself but also facilitates in dealing with limb length discrepancies, along with early mobilization and easy dressing of the wound. It's simple method of bone transport on CD device and being light weight makes patient more compliant for this exhaustive duration. As our study group is small more extensive study on large number of patients is needed to establish LRS as definitive treatment modality in infected non-union of tibial diaphysis.

## 6. Source of Funding

None.

## 7. Conflict of Interest

None.

## References

1. Pal CP, Kumar H, Kumar D, Dinkar KS, Mittal V, Singh NK. Comparative study of the results of compound tibial shaft fractures

2. treated by Ilizarov ring fixators and limb reconstruction system fixators. *Chin J Traumatol.* 2015;18(6):347–51.
3. Romanò CL, Pellegrini A, Tinti G, Meani E. Quaderni di Infezioni Osteoarticolari. Infection after osteosynthesis: the conservative surgical treatment. 2001;2:3–16.
4. Campbell's operative orthopaedics. 10th ed.; 2002.
5. Panagiotis M. Classification of non-union. *Inj.* 2006;37(9):927.
6. Mahaluxmivala J, Nadarajah R, Allen PW, Hill RA. Ilizarov external fixator: acute shortening and lengthening versus bone transport in the management of tibial non-unions. *Inj.* 2005;36(5):662–8.
7. Melendez E, Colon C. Treatment of open tibial fractures with the orthofix fixator. *Clin Orthop.* 1989;241:224–30.
8. Ong CT, Choon DSK, Cabrera NP, Maffulli N. The treatment of open tibial fractures and of tibial non-union with a novel external fixator. *Inj.* 2002;33(9):829–34.
9. Chapman's orthopaedic surgery. 3rd ed.; 2001.
10. Sancheti PK, Patel SK, Rocha S, Shyam AK. Use of antibiotic cement-impregnated intramedullary nail in treatment of infected non-union of long bone. *Indian J Orthop.* 2009;43(4):396–402.
11. Dendrinis GK, Kontos S, Lyritis E. Use of Ilizarov technique for Treatment of nonunion of the tibia associated with infection. *J Bone Joint Surg Am.* 1995;77(6):835–46.
12. Cierny G, Mader JT, Penninck JJ. A clinical staging system for adult osteomyelitis. *Contemp Orthop.* 1985;10:17–37.
13. A.S.A.M.I group. Operative principles of Ilizarov; 1991.
14. Guidera K, Hess W, Highhouse KP, Ogden JA. Extremity lengthening: results and complications with the Orthofix system. *J Pediatr Orthop.* 1991;11:90–4.
15. García-Cimbrelo E, Martí-González JC. Circular external fixation in tibial Nonunions. *Clin Orthop Relat Res.* 2004;419:65–70.
16. Gajbhiye AI, Goyal SS, Kumar MM. Dorai Kumar Outcomes of mono-lateral limb reconstruction system in infected non-union of long bones. *J Res Orthop.* 2018;4(1):27–32.
17. Patil S, Montgomery R. Management of complex tibial and femoral nonunion using the Ilizarov technique, and its cost implication. *J Bone Joint Surg Br.* 2006;88:928–4.
18. Jain S, Mukherjee A, Ajmera A, Verma A, Agrawal M. Outcome of limb reconstruction system in open tibial diaphyseal fractures. *Indian J Orthop.* 2015;49(4):429–35.
19. Donnan LT, Saleh M, Rigby AS, McAndrew A. Radiographic Assessment of Bone Formation in Tibia During Distraction Osteogenesis. *J Pediatr Orthop.* 2002;22(5):645–51.
20. Sen C, Kocaoglu M, Eralp L, Gulsen M, Cinar M. Bifocal Compression-Distraction in the Acute Treatment of Grade III Open Tibia Fractures With Bone and Soft-Tissue Loss. *J Orthop Trauma.* 2004;18(3):150–7.

## Author biography

**Apser Khan** Associate Professor

**Animesh Kumar Singh** Assistant Professor

**S K Kaushik** Associate Professor

**Sanjay Gupta** Professor and Head

**Rahul Verma** Junior Resident

**Cite this article:** Khan A, Singh AK, Kaushik SK, Gupta S, Verma R. Functional and Radiological outcome of Limb Reconstruction system (LRS) in infected nonunion of Tibia. *Indian J Orthop Surg* 2020;6(3):198-203.