



Case Report

Non traumatic avascular necrosis of navicular with subluxation of talonavicular joint

Ramneesh Kohli^{1,*}, Ashish Arya², Ashish Kohli¹

¹Dept. of Orthopaedics, Kohli Hospital, Yamunanagar, Haryana, India

²Dept. of Orthopaedics, Kalpana Chawla Government Medical College, Karnal, Haryana, India



ARTICLE INFO

Article history:

Received 19-05-2020

Accepted 22-05-2020

Available online 07-07-2020

Keywords:

Navicular

Talonavicular joint

ABSTRACT

There are various osseous pathologies affecting the tarsal navicular which lead to mid foot pain. These vary from stress fractures and coalitions to overt fractures. Rarely, there is interruption of vascular supply. In children, it is called Koehler disease. In adults, avascular necrosis of navicular is called Mueller –Weiss syndrome. A case of non traumatic avascular necrosis of navicular is presented here.

© 2020 Published by Innovative Publication. This is an open access article under the CC BY-NC license (<https://creativecommons.org/licenses/by-nc/4.0/>)

1. Introduction

Non traumatic avascular necrosis of navicular is a rare condition. Conservative treatment is usually sufficient in most of the cases. Rarely, few patients may fail conservative treatment and may require surgical intervention. Surgical techniques described include drilling decompression and various arthrodesis procedures based upon surgeon preference.^{1–10}

In this article, we present a case of osteonecrosis of navicular with arthritis and subluxation of talonavicular joint. The patient was treated by arthrodesis of talonavicular joint.

2. Case Presentation

A 50 year old male, policeman by occupation presented left mid foot pain without any history of trauma. He was treated conservatively with medication and insole for 10 months. Patient symptoms did not improve radiograph showed osteonecrosis of navicular with subluxation of talonavicular joint.

At the time of presentation, his left foot was swollen and had point tenderness at the position of talonavicular joint. His pre operative JSSF¹¹ (Japanese Society for Surgery of the Foot) midfoot scale score was 83 points.

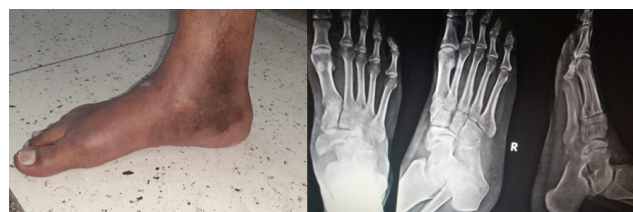

Fig. 1:

Radiograph showed increased radiodensity and subluxated talonavicular joint with arthritic changes of talonavicular joint. CT scan showed diffuse sclerosis and marginal irregularities of the navicular.

3. Surgical Technique

Arthrodesis of talonavicular joint was selected as the treatment as both joint surfaces were arthritic. The talonavicular joint was exposed through a dorsal medial incision just medial to tibialis anterior tendon. The adjacent

* Corresponding author.

E-mail address: dr.ramneesh@gmail.com (R. Kohli).

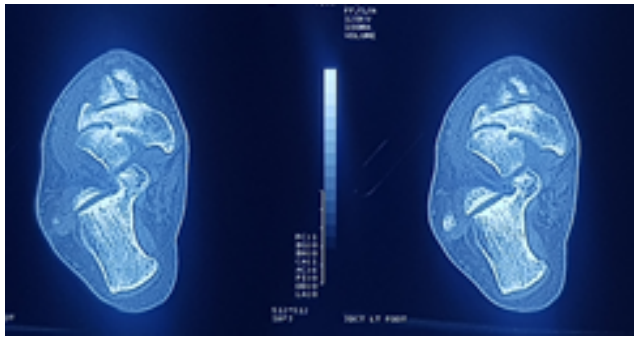


Fig. 2:

necrotic surfaces of talus and navicular were excised and bone defect was reconstructed using tricortical bone graft from iliac crest. Arthrodesis was performed using two 4.5MM cancellous screws. The ankle was immobilised in a cast for 6 weeks after surgery. Partial weight bearing with PTB cast was permitted after removal of cast.

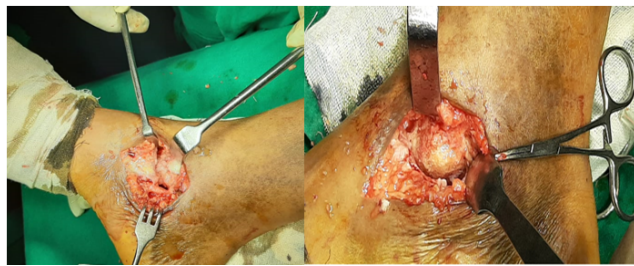


Fig. 3:

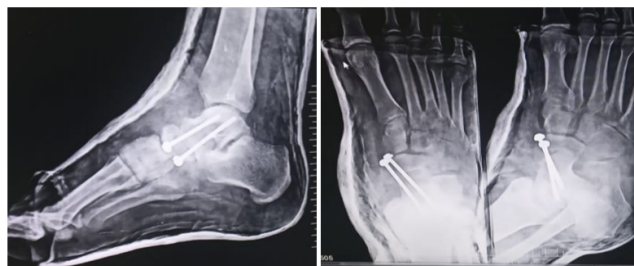

Fig. 4:

Follow up radiograph showed good union and at one year JSSF score of 97.

4. Discussion

Spontaneous osteonecrosis of tarsal navicular is called Mueller Weiss syndrome. The secondary causes include rheumatoid arthritis, trauma, corticosteroid use and chronic renal failure. It has been postulated that chronic disorder of load distribution with altered foot biomechanics causes disruption of microvascular system of the navicular.

The navicular receives its blood supply from 15 -20 branches of dorsalis pedis artery and brancheortions from the medial plantar artery. They penetrate the navicular circumference of navicular radially. The plantar aspect of the bone is supplied by medial plantar artery.¹²The lateral portion of the navicular is more likely affected by maldistribution of blood flow which is seen as collapse of lateral part of navicular and increased radiodensity on radiograph and arthritic changes in the midfoot.

No standard operative technique is described because of small number of cases in all series and different grades of severity of disease. The aim of surgical procedure is to restore length of medial column of foot.¹² The various techniques described are core decompression, talonavicular arthrodesis and triple arthrodesis. The appropriate surgery is planned according to grade of disease.^{4,5,9} Percutaneous core decompression is selected with no specific changes on radiographs.⁵ For a patient with perinavicular arthritis, arthrodesis procedure is chosen. The fixation may be done using screws only or using low profile plates. Treatment using debridement followed by a free medial femoral condyle vascularised bone graft was described in 2013.⁶ This treatment is believed to be highly invasive and requires complicated operative procedure.

The present case was classified as stage 3 of Maceira classification due to compression of navicular was seen with arthritic changes. Therefore, patient was planned for talonavicular arthrodesis. In the operation, necrotic part of the bone was removed, edges freshened and bone graft was harvested from iliac crest followed by arthrodesis of talonavicular joint using 4.5 mm screws. In the present case patient had good result with improved functional scoring.

5. Conclusion

The use of talonavicular arthrodesis from the medial aspect is a reasonable for spontaneous osteonecrosis of navicular with arthritis. Fixation with screws is mandatory for joint fusion.

6. Source of Funding

None.

7. Conflict of Interest

None.

References

1. Aktas E, Ayanoglu T, Hatipoglu Y, Kanatli U. Spontaneous and bilateral avascular necrosis of the navicula: Müller-Weiss disease. *Ekleml Hastalıkları ve Cerrahisi*. 2016;27:179-82.
2. Reade B, Atlas G, Distazio J, Kruljac S. Mueller-weiss syndrome: An uncommon cause of midfoot pain. *J Foot Ankle Surg*. 1998;37(6):535-9.
3. Cao HH, Tang KL, Xu JZ. Peri-navicular arthrodesis for the stage III Müller-Weiss disease. *Foot Ankle Int*. 2012;33(6):475-8.

4. de Retana PF, Maceira E, Fernández-Valencia JA, Suso S. Arthrodesis of the talonavicular-cuneiform joints in Müller-Weiss disease. *Foot Ankle Clin.* 2004;9(1):65–72.
5. Janositz G, Sisák K, Tóth K. Percutaneous decompression for the treatment of Mueller–Weiss syndrome. *Knee Surg, Sports Traumatol, Arthrosc.* 2011;19(4):688–90.
6. Levinson H, Miller KJ, Adams SB, Parekh SG. Treatment of Spontaneous Osteonecrosis of the Tarsal Navicular With a Free Medial Femoral Condyle Vascularized Bone Graft. *Foot Ankle Specialist.* 2014;7(4):332–7.
7. Lui TH. Arthroscopic triple arthrodesis in patients with Müller Weiss disease. *Foot Ankle Surg.* 2009;15(3):119–22.
8. Maceira E, Rochera R. Müller-Weiss disease: clinical and biomechanical features. *Foot Ankle Clin.* 2004;9(1):105–25.
9. Tan A, Smulders YCMM, Zöphel OT. Use of Remodeled Femoral Head Allograft for Tarsal Reconstruction in the Treatment of Müller-Weiss Disease. *J Foot Ankle Surg.* 2011;50(6):721–6.
10. Tosun B, Al F, Tosun A. Spontaneous Osteonecrosis of the Tarsal Navicular in an Adult: Mueller-Weiss Syndrome. *J Foot Ankle Surg.* 2011;50(2):221–4.
11. Niki H, Aoki H, Inokuchi S. Development and reliability of a standard rating system for outcome measurement of foot and ankle disorders II: interclinician and intraclinician reliability and validity of the newly established standard rating scales and Japanese Orthopaedic Association rating scale. *J Orthop Sci.* 2005;10(5):466–74.
12. Sarrafian SK, Kelikian AS. Sarrafian's Anatomy of the Foot and Ankle. 3rd ed.; 2011.

Author biography

Ramnessh Kohli Consultant

Ashish Arya Assistant Professor

Ashish Kohli Consultant

Cite this article: Kohli R, Arya A, Kohli A. Non traumatic avascular necrosis of navicular with subluxation of talonavicular joint. *Indian J Orthop Surg* 2020;6(2):137-139.