



Original Research Article

A comparative study of functional and radiological outcome in management of type IIIB tibial fractures by AO and ilizarov external fixator

Ramesh Krishna K¹, Suresh Kumar G^{1,*}, Aradhana T R¹

¹Dept. of Orthopaedics, Bangalore Medical College and Research Institute, Bangalore, Karnataka, India



ARTICLE INFO

Article history:

Received 20-03-2020

Accepted 22-05-2020

Available online 07-07-2020

Keywords:

Type IIIB tibia fractures

Ilizarov external fixator

AO external fixator

ASAMI score

ABSTRACT

Background and Objectives: Tibia fractures are relatively common & Annual incidence of open tibial fracture is 11.5 /1,00,000 persons. Majority of these fractures are open diaphyseal fractures, of which 60% are Gustillo type III. Open fractures of tibia are more commonly seen than any other long bones because of the subcutaneous location of the bone.

External fixators offer several advantages in management of open tibial fractures. AO and Ilizarov are types of external fixators. Ilizarov technique is cost effective, primary and definitive treatment and offer acceptable stability for the fracture, minimal operative trauma and good access to soft tissues and offers high union rates. AO is simple and safe to apply can be used in management of open tibial fractures.

This study was conducted to determine the comparison of Radiological & Functional outcome & complications of the acute Open tibial fractures treated with primary Ilizarov external fixator and AO external fixator.

Materials and Methods: Randomized comparative Study period was from November 2017 to May 2019. Age group between 18– 60 years was considered. The follow up would be for one year. Initially for every 3 weeks in first 6 weeks for wound care, every 6weeks for one year and assessed by Radiological evidence of union of fracture and Functional assessment by Patient's Functional and Bone results are assessed based on ASAMI and functional assessment done by knee and ankle joint Range of motion & complications.

Results: This is a prospective study population consists of 40 patients with IIIB open Tibia fractures of mean age in AO group is 44.3 +/- 10.6 years with male preponderance. In AO group majority of fractures were 42B3 (40%) & 43A3 (35%). Ilizarov group majority are 43A3 (25%), 15% fractures of each 41A3, 42A1, 42A3 & 42C3. Mean Radiological union time was 22.84 +/- 2.3 weeks in AO group, 24.95 +/- 4.6 weeks in Ilizarov group & Non union rate is 1 (5%) case in both the group. ASAMI bone results & functional results was Excellent (25%), Good (70%) & Poor(5%) in AO group, whereas in Ilizarov group Excellent (65%), Good (30%) & Poor (5%). Ilizarov has good Functional scoring when compare to AO group. common complications encountered were Pin Tract Infections, pain, stiffness, limp. In AO group pin tract infections were seen in 50%(n-10) & In Ilizarov group pin tract infections were seen in 20%(n- 4). No case developed deep Infection, or Unacceptable malunion.

Conclusion: Ilizarov external fixator being minimally invasive procedure interferes less with the blood supply. The construct is ring fixator, safe, stable (three dimensional stability) and enable the patient early Weight bearing after surgery and high union rates, even in highly comminuted fractures.

© 2020 Published by Innovative Publication. This is an open access article under the CC BY-NC license (<https://creativecommons.org/licenses/by-nc/4.0/>)

1. Introduction

Open fractures are those in which a bone or joint structure is exposed to the environment due to disruption of soft tissues

and overlying skin. due to subcutaneous position of tibia, fractures of the tibia more commonly result in open fracture than any other long bone, direct injury is usually high energy and results in open fracture. Gustilo Anderson classified open fractures into three types that is type I,II,III (IIIA, IIIB,IIIC).¹ The frequency of open long bone fractures

* Corresponding author.

E-mail address: susangee83@gmail.com (S. Kumar G).

approximately 11.5 per 100,000 persons per year. Majority of these fractures are open diaphyseal fractures of which 60% are Gustillo type III0.²

External fixators offer several advantages in management of open tibial fractures. AO and Ilizarov are types of external fixators. Ilizarov technique is cost effective, primary and definitive treatment and offer acceptable stability for the fracture, minimal operative trauma and good access to soft tissues and offers high union rates.^{3,4} AO is simple and safe to apply can be used in management of open tibial fractures.^{5,6}

Gavril. A. Ilizarov devised Ilizarov technique of treatment in open tibial fractures. Despite of technical difficulties, Ilizarov method is now used worldwide for treatment of open fractures.⁷ The construct is ring fixator, safe, stable and enable the patient early Weight bearing after surgery and high union rates, even in highly comminuted fractures.⁸ The Ilizarov method relies on distraction osteogenesis and advantages compare to AO external fixator is its relative stability (angular, rotational, and alignment) and immediate post operative weight bearing which is difficult in AO external fixators. Use of thin k-wires (1.5mm&1.8mm) offers minimum traumatic effects on bone when compared to AO external fixator. The efficiency of treatment in Ilizarov is higher than AO external fixation.⁹

Open tibial fractures which needs flap coverage should be treated with high priority of radical debridement and early flap coverage preferably in first 5days.¹⁰

The purpose of study is to compare Ilizarov technique and AO External fixation in open tibial fractures in terms functional and radiological outcome.

2. Materials and Methods

This is a Randomized, comparative study conducted on Patients of either sex with open tibial fractures satisfying inclusion criteria admitted in Victoria hospital and Bowring and Lady Curzon hospital attached to Bangalore Medical College and Research Institute, Bangalore during November 2017 to August 2019.

Cases satisfying the inclusion criteria were included. According to the hospital statistics, an average number of 20 patients satisfying the inclusion criteria have been treated by Ilizarov technique and 20 patients treated by AO external fixator in the previous 2 years. Cases will be randomized by simple random sampling.

2.1. Inclusion criteria

Patients between 18-60 years of age Fresh, Open Tibia fractures (type IIIB)¹ were included in this study.

2.2. Exclusion criteria

We excluded Patients who are not willing to provide informed consent, Closed Tibia fractures, Pathological

fractures, Type I, IIIA & IIIC fractures, Intra Articular Fractures, Floating knee and Polytrauma patients

2.3. Procedure

After obtaining written informed consent will be taken from the patients fulfilling the inclusion and exclusion criteria. Demographic data, history, clinical examination and details of investigations will be recorded in the study proforma after admission. Preoperative work up done and patients will be divided into two groups based on method of treatment they will get. These patients will be randomized by simple random sampling and treated with Ilizarov and AO Biplanar external fixator. Early wound swab taken. All patients were started on triple antibiotics which includes 3rd generation Cephalosporins, Metranidazole for Anaerobic bacterial coverage and Aminoglycoside for gram negative bacterial coverage. All wounds were given thorough wound wash with normal saline in the emergency room as soon as the patient is received. Patients who required plastic surgery interventions were operated in the same sitting with plastic surgery procedures like flap coverage and SSG, if the wound was less contaminated. Frames will be removed after clinico-radiological union.

The follow up would be for one year. Initially for every 3 weeks in first 6 weeks for wound care, every 6weeks for one year and assessed by Radiological evidence of union of fracture and Functional assessment by Patient's Functional and Bone results are assessed based on ASAMI (Association for the study and application of the methods of Ilizarov) criterion and complications. The data will be recorded in the appropriate proforma.

Data collected was tabulated. Continuous variables were expressed as mean+/- SD and analysed within the groups using repeated measured ANOVA. Intergroup comparison will be done using unpaired 't' test. Categorical variables will be expressed as percentage or proportion and analysed using Chi square test.

3. Results

In our study most of the cases are observed in patients of age group 51 to 60 years, they Occupy 32.5 % and 27.5 % cases were observed in age group 41-50 years age and 17.5% of cases were observed in 31-40 age group occupying the lowest. Hence most of the fractures were observed in 31-40 age groups. Mean Age in AO group is 44.3 +/- 10.6 years and Ilizarov group is 41.15 +/- 11.8 years with male preponderance in the Gender Distribution of both Groups, being 90 % and 90 % in Group A and B, respectively. According to our study males are more prone to fractures when compared to females.

Subjects in our series are more affected on right side (57.5 %) when compared to left side (42.5 %). In AO group majority of fractures were 42B3 (40%) & 43A3 (35%) and

Table 1: Demographic details

S. No	Variable	AO Group (N =20)	Ilizarov Group(N=20)
1	Age (years)	44.3 +/- 10.6	41.15 +/- 11.8
2	Sex	M : F = 18 : 2	M : F = 18:2
3	Side	R : L = 12 : 8	R : L = 11 : 9
4	Ankle spanning	3	1
5	Duration on fixator(weeks)	22.85 +/- 2.2	24.1 +/- 4.9
6	Secondary procedures	5	1
7	Radiological union time	22.84 +/- 2.3	24.9 +/- 4.6

Table 2: ASAMI score – BR (Bone results & functional results)

ASAMI Score - BR - 48 WKS	AO external fixation	Ilizarov technique	Total	Chi square	p value
Excellent	5 25.0%	13 65.0%	18 45.0%	6.756	0.034
Good	14 70.0%	6 30.0%	20 50.0%		
Poor	1 5.0%	1 5.0%	2 5.0%		
Total	20 100.0%	20 100.0%	40 100.0%		

Table 3: Distribution of complications

Complications	AO external fixation		Ilizarov technique		Chi square	p value
	n	%	n	%		
Pin tract infection	10	50	4	20	3.956	0.096
Pain	7	35	8	40	0.107	0.744
Stiffness	5	25	3	15	0.625	0.429
Limb length Discrepancy	2	10	1	5	4.111	0.391
Deformity/Malunion	4	20	2	10	0.784	0.661
Non union	1	5	1	5	0	1

Table 4: AO Group

S. No	Variable	Our study	Sm. Esmailnejad Ganji et al ⁹	Sanaullah et al ⁵	Mehtab Piwani et al ⁶
1	Mean age (years)	44.3+/-10.6	31.3+/-10.9	32 +/- 15	34.7 +/- 5.8
2	Union time (weeks)	22.84+/-2.3	23.4+/-8.5	23.4	20.6
3	Non Union (%)	5	11.7	7	3.3
4	Malunion (%)	20	18.3	7	3.3
5	ASAMI Score (%)	95	65	-	-
6	PTI (%)	50	24	31	6.6

Table 5: Ilizarov Group

S. No	Variable	Our Study	SM. Esmailnejad Ganji et al ⁹	Naveed Wani et al ⁷	Laishram Birendro Singh et al ⁴
1	Mean age (years)	41.1+/-11.8	32.3+/-11.2	36.4	39.1
2	Union time (weeks)	24.9+/-4.6	21+/-7.4	24.9 +/-5.1	24.5
3	Non union (%)	5	10	0	0
4	Malunion (%)	10	10	0	15
5	ASAMI score (%)	95	87	-	-
6	PTI (%)	20	31	25	33.3

On comparing both Groups, Ilizarov group is better in respect to ASAMI score, malunion and pin tract infections rates.

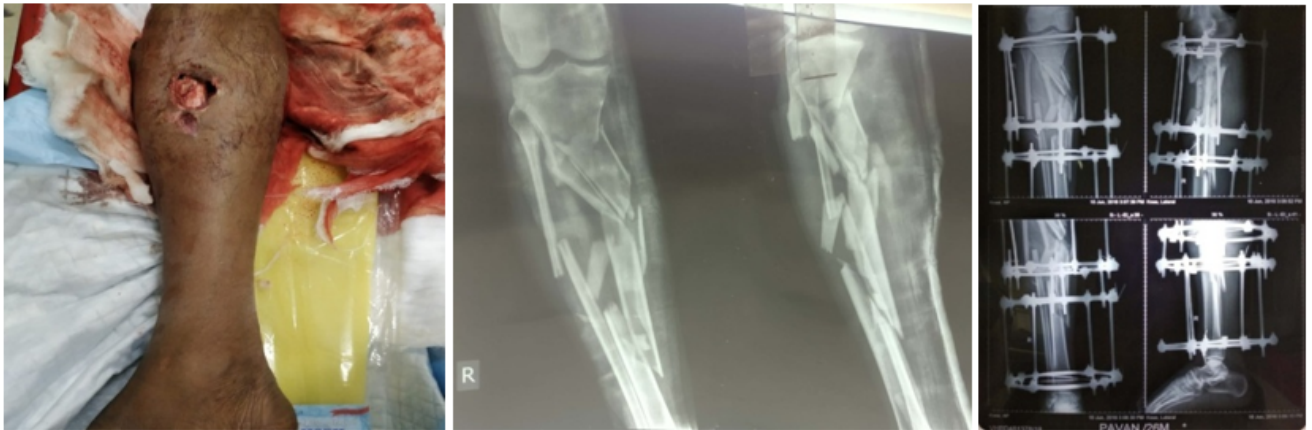

Fig. 1: Pre op images & Post op x-ray(Ilizarov Group)

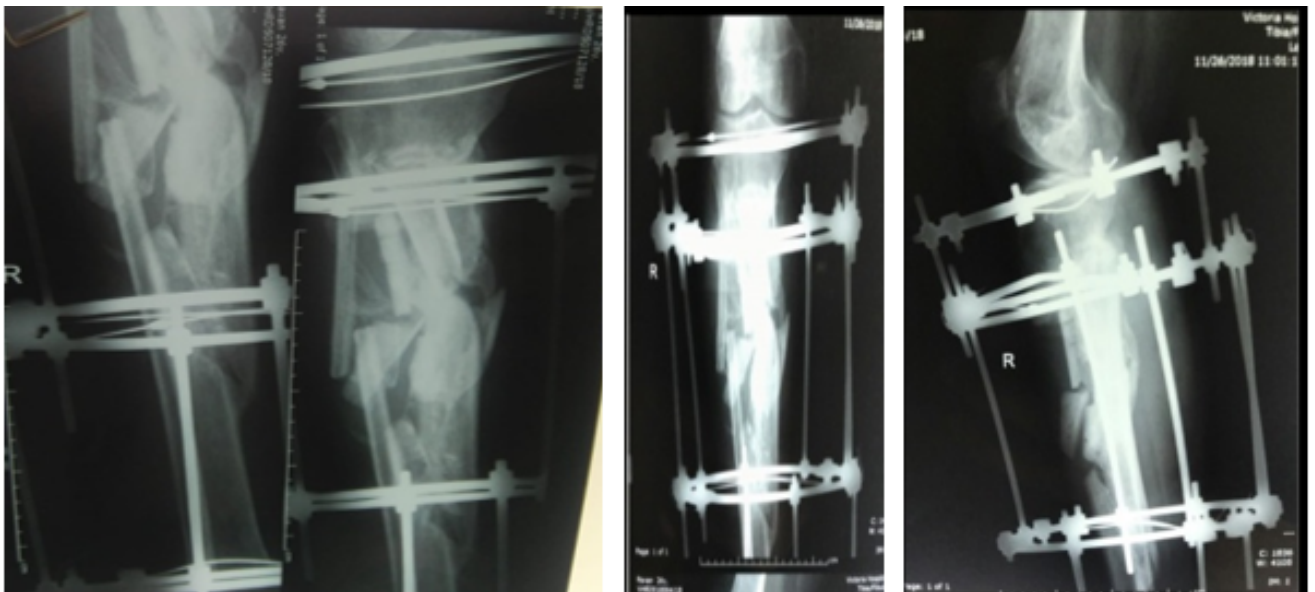


Fig. 2: Shows follow up x-ray at 12 weeks & 24 weeks(Ilizarov Group)

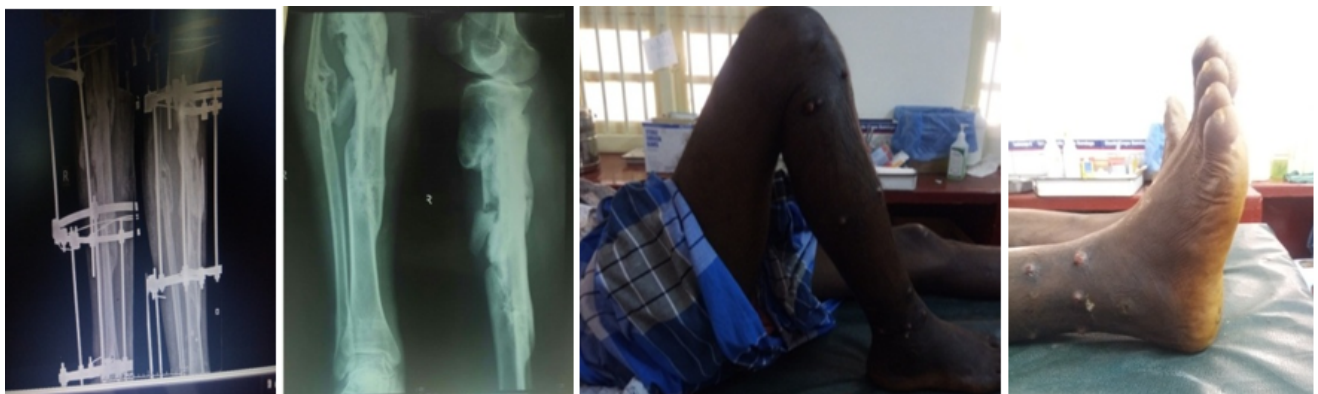

Fig. 3: Shows follow up x-ray ROM at 32 weeks(Ilizarov Group)

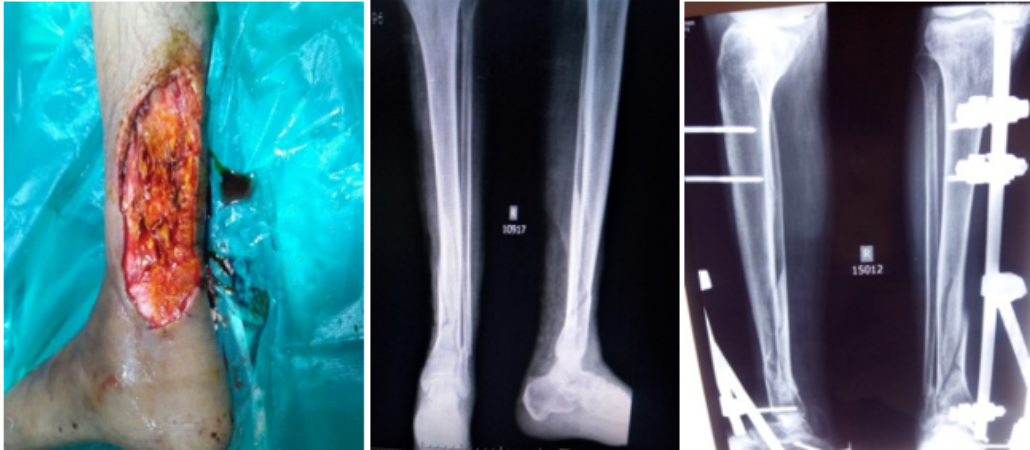

Fig. 4: Wound, Pre op & post op images (AO Group)

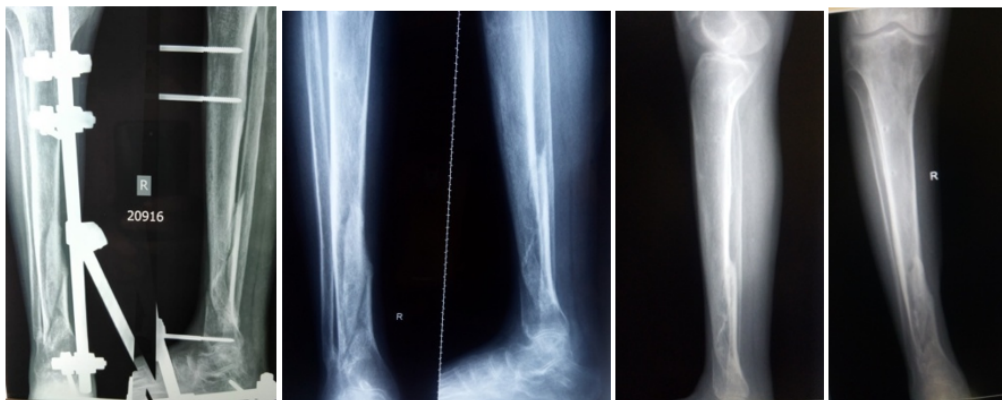


Fig. 5: Shows follow up x-ray at 24 & 32 weeks (AO Group)

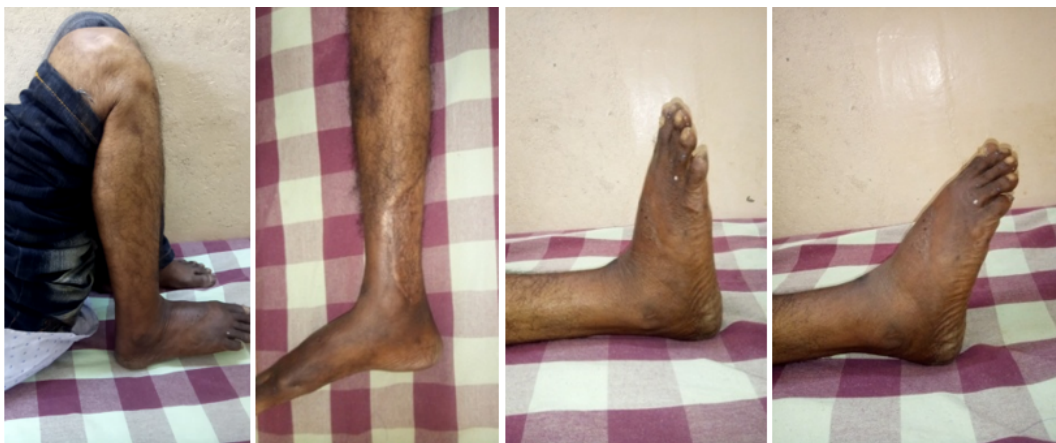

Fig. 6: Shows ROM (AO Group)

42A3 (20%) 41A3 (5%). Ilizarov group majority are 43A3 (25%), 15% fractures of each 41A3, 42A1, 42A3 & 42C3 and 41A2 (10 %), 43A1 (5%).

Ilizarov external fixator is a Ring fixator, we used 4 Rings construct in 70% of cases and 3 Rings in 30% of cases. In AO external fixator we used BIPLANAR external fixator in all cases. In AO group 6 pins construct were 12 (60%), 5 pins -7 (35%) & 7 pins - 1 (5%). In Ilizarov group majority were 8 pins construct (16 (80%), 9 pins - 3 (15%), 6 pins -1(5%). AO group Ankle spanning was done for 3 cases (15%) & Ilizarov group 1 case (5%). Mean duration on Fixator was 22.85 +/- 2.27 weeks in AO group, and 24.1 +/- 4.1 weeks in Ilizarov group. Secondary Procedure was done in 5 cases (SSG) (35%) in AO group, 1 case (Fasciocutaneous Flap) (5%) in Ilizarov group. Mean Radiological Union Time was 22.84 +/- 2.3 weeks in AO group, 24.95 +/- 4.6 weeks in Ilizarov group & Non Union rate is 1 (5%) case in both the group.

In our study ASAMI bone results & functional results was Excellent (25%), Good (70%) & Poor (5%) in AO group, whereas in Ilizarov group Excellent (65%), Good (30%) & Poor (5%). Ilizarov has good Functional scoring when compare to AO group most common complications encountered were Pin Tract Infections, pain, stiffness, limp.

In AO group pin tract infections were seen in 50 % (n-10), pain in 35% (n-7), stiffness 25% (n- 5), limb length discrepancy in 20% (n- 2), deformity 20% (n- 4), Non union 5%(n-1), limp 30% (n- 6).

In Ilizarov group pin tract infections were seen in 20% (n- 4), pain in 40 % (n- 8), stiffness 15% (n- 3), limb length discrepancy in 5% (n- 1), deformity 10 % (n- 2), Non union 5% (n- 1), limp 20% (n- 4) & Refracture in 1 case due to self fall from bike during treatment.

Pin tract infections were easily managed by oral antibiotics and local Neomycin skin ointment, stiffness was improved by extensive physiotherapy, pain was managed with analgesics and reassurance. Limb Length Discrepancy (shortening) was less than 2cm, which was corrected by shoe rise. No case developed deep Infection, or Unacceptable malunion.

4. Conclusion

Tibia is most common bone to be fractured in polytrauma.

Invariably fractures of tibia are complex in nature as it is subcutaneous in whole of its length. External fixators are the mainstay of treatment in open fractures.

AO and Ilizarov are types of external fixators. Ilizarov technique is cost effective, primary and definitive treatment and offer acceptable stability for the fracture, minimal operative trauma and good access to soft tissues and offers high union rates.

AO external fixator is simple and safe to apply can be used in management of open tibial fractures. Ilizarov external fixator is a very good modality in treating such kind

of fractures where internal fixation can lead to disasters.

Ilizarov external fixator being minimally invasive procedure interferes less with the blood supply. The construct is ring fixator, safe, stable (three dimensional stability) and enable the patient early Weight bearing after surgery and high union rates, even in highly comminuted fractures.

Radiological Union time is almost same in both techniques.

Bone loss, Malunion, Non union, and limb length discrepancy can be addressed with this fixator simultaneously along with fracture treatment because of its versatility.

Pin tract infection is the most common problem faced, higher with AO External fixator than Ilizarov technique, however this can be treated successfully.

Due to early post operative weight bearing and almost during whole course of treatment in Ilizarov technique, hence ability to carry out Activity of Daily Living and in some cases their professional work, patient satisfaction is high. The Problems, Obstacles and Complications of using the Ilizarov external fixation itself is a small price to pay to minimize major complications of open methods.

5. Source of Funding

None.

6. Conflict of Interest

None.

References

1. Wood GW, Beatty JH, Daugherty K, Jones L. Campbell's General principles of fracture management. In: Canale operative orthopaedics. vol. 3. 12th ed. Philadelphia: Elsevier Mosby; 2013.
2. Rajashekar S, Dheenadayalan J, Devendra P, Ramesh P, Kulkarni GS, Babhulkar S. Open fractures. In: Text book of orthopedics and trauma. vol. 3. India: Jaypee; 2016. p. 829–37.
3. Foster PAL, Barton SB, Jones SCE, Morrison RJM, Brittany S. The treatment of complex tibial fractures by ilizarov method. *J Bone Jt Surg.* 2012;94(12). doi:10.1302/0301-620X.94B12.29266.
4. Singh LB, Singh ID, Singh CA. Treatment of open fractures by ilizarov technique. *IOSR - Journal of dental and medical sciences.* *J Dent Med Sci.* 2016;15(12):18–22.
5. Sanaullah KS, Ali B, Hakeem A, Ahmed I, Khan MA. AO external fixator in the management of open fracture of tibia. *Rawal Med J.* 2016;41(4):459–61.
6. Piwani M, Bhutto IA, Ahmed I. Evaluation of AO external fixator in the management of open diaphysal fracture of tibia Gustilo type IIIA and III B. *Gomal J Med Sci.* 2015;13:66–9.
7. Wani N, Baba A, Kangoo K, Mir M. Role of early Ilizarov ring fixator in the definitive management of type II, IIIA and IIIB open tibial shaft fractures. *Int Orthop.* 2011;35(6):915–23.
8. Nesari S, Wali P, Pasha M. Treatment of tibial fractures by Ilizarov technique: A longitudinal study. *IJSS J Surg.* 2015;1(6):6–9.
9. Ganji SME, Bahrain M, Joker F. Ilizarov versus AO external fixator for treatment of tibia open fractures. *Iran Red Crescent Med J.* 2011;13(12):868–72.
10. Kamath JB, Shetty MS, Joshua TV, Kumar A, Harshvardhan, Naik DM. Soft tissue coverage in open fractures of tibia. *Indian J Orthop.* 2012;46(4):462–9.

Author biography**Ramesh Krishna K** Professor & HOD**Suresh Kumar G** Post Graduate**Aradhana T R** Assistant Professor

Cite this article: Krishna K R, Kumar G S, Aradhana T R . A comparative study of functional and radiological outcome in management of type IIIB tibial fractures by AO and ilizarov external fixator. *Indian J Orthop Surg* 2020;6(2):90-96.