



Case Report

Aggressive uncommon pediatric renal tumor: Rhabdoid tumor of kidney

Sarojini Raman^{1,*}, Goutami Das Nayak¹, Madhusmita Mohanty¹,
Subrat Kumar Mohanty², Urmila Senapati¹

¹Dept. of Pathology, Kalinga Institute of Medical Sciences, Bhubaneswar, Odisha, India

²Dept. of Pediatric Surgery, Kalinga Institute of Medical Sciences, Bhubaneswar, Odisha, India



ARTICLE INFO

Article history:

Received 23-03-2021

Accepted 07-04-2021

Available online 19-05-2021

Keywords:

Rhabdoid tumor

Kidney neoplasm

ABSTRACT

Rhabdoid tumor of kidney is one of the uncommon pediatric renal neoplasms with highly aggressive clinical course. We are presenting a case of 1 year child with abdominal distension and hematuria. On Contrast enhanced computed tomography (CECT) a heterogenous mass in lower pole of kidney was detected. Histopathological and immunohistochemical study after radical nephrectomy revealed Malignant rhabdoid tumor of kidney. It has a tendency to metastasize early and it is associated with synchronous presence of other malignancies. No definite effective treatment for this tumor is available till now. This further necessitates the early diagnosis and prompt management which can be life saving for the patient. We are presenting this case to emphasize on its rarity and aggressive clinical behaviour.

© This is an open access article distributed under the terms of the Creative Commons Attribution License (<https://creativecommons.org/licenses/by/4.0/>) which permits unrestricted use, distribution, and reproduction in any medium, provided the original author and source are credited.

1. Introduction

Incidence of childhood cancers is 1% of all cancers and pediatric renal tumors constitute 6-7% of all childhood cancers.^{1,2} Rhabdoid tumor of kidney (RTK) accounts for 0.9% among the pediatric renal tumors as per the International Society of Pediatric Oncology (SIOP) data and 1.8% of malignant childhood renal tumors according to National Wilms Tumor Study Group (NWTS).³ It has been reported in liver, pancreas, gastrointestinal tract, retroperitoneum, mediastinum, urinary bladder, soft tissue (malignant rhabdoid tumors) and central nervous system (known as atypical teratoid/rhabdoid tumors).⁴ We are reporting the case due to its rarity and aggressive clinical behaviour.

2. Case History

A 1-Year male child was admitted in paediatric surgery OPD with the complains of lump in the abdomen

since 1 month and hamaturia since 8 days. He had no known comorbidities. On examination his pulse rate was 80 per minute and BP was 140/70 mm of Hg. On inspection he had an ill-defined lump of about 5x5cm in the left lumbar region. Swelling moved vertically with respiration. On palpation there was an ill-defined mass of about 7x7cm extending from left subcostal margin till 1cm above left antero-superior iliac spine (ASIS). Lower margin of mass was well-defined and upper margin extended beyond subcostal region. It was firm to hard in consistency, and was ballotable. Contrast enhanced computed tomography (CECT) revealed a well defined exophytic soft tissue mass in left lower pole showing internal necrosis and haemorrhage without any calcification (Figure 1 A). Mass was displacing small and large bowel antero-medially and left ureter medially with no evidence of any infiltration to ureter or adjacent bowel. No extension of lesion/ thrombus in left renal vein/IVC(Inferior vena cava) was noted. No retroperitoneal lymphadenopathy was seen. The radiological diagnosis was s/o Wilms Tumour. Routine complete blood count (CBC) showed TLC-8800/cmm, Hb-11.3 gm/dl, TPC-4.12 Lakh /cmm.

* Corresponding author.

E-mail address: sraman10371@gmail.com (S. Raman).

Liver function test (LFT) was unremarkable. A/G ratio was 2.44, sr. Urea-21mg/dl, sr Creatinine-0.15mg/dl, sr Sodium-135mmol/L, sr Potassium-4.4mmol/L, sr Calcium-9.2mg/dl, sr Phosphorus-5.3 mg/dl, sr Uric acid-4.9 mg/dl. Final clinical Diagnosis was Wilms Tumour Of Left Kidney. Patient underwent Radical Nephrectomy under GA. Intraoperatively a solid mass was seen arising from the lower pole of the left kidney with necrotic areas. It was adherent to the transverse and descending colon.

Grossly the radical nephrectomy specimen measured 13x8.5x6.5cms. The tumor was in lower pole and mid region of kidney, sparing the upper pole and almost dwarfing the remnant normal kidney. Capsule appeared to be intact. Tumor measured 10x5.3x4.5cms. Normal renal parenchyma measured 2.5x3x2.5cms. Cut section of tumor was variegated with areas of hemorrhage and necrosis. Ureter measured 8.5cms long. Grossly adrenal gland was not identified. 4 lymphnodes isolated (Figure 1 B). Histology sections showed tumor cells invading renal pelvi-calyceal system, renal sinus fat and lymphovascular spaces in renal sinus. Gerota's fascia, renal vascular cut margins were free of tumor. Tumor cells were arranged in diffuse pattern surrounding thin walled blood vessels. Tumor cells were mildly pleomorphic, polygonal in shape, had abundant eosinophilic cytoplasm, eccentric nuclei, vesicular chromatin and thick nuclear membrane. Many cells showed prominent nucleoli and intracytoplasmic eosinophilic globules (Figure 2 A). Both typical and atypical mitotic figures were seen. Vascular invasion was present. The differentials in this cases were tumours with rhabdoid morphology in kidney namely Wilms tumor and Collecting duct carcinoma. Monophasic Wilms tumor with dominant rhabdoid morphology is very rare. Collecting duct carcinoma arises in adult age group. Moreover, after extensive areas of sectioning classical collecting duct carcinoma or Wilms tumor morphology could not be detected. So both were ruled out. Further IHC study for Vimentin, Pax 8, CD99 was done to rule out the two differentials. IHC revealed Vimentin positivity in >95% of tumor cells. Pax8 & CD99 were negative (Figure 2 B,C,D). So final diagnosis was Rhabdoid tumor of kidney, high grade, pathologic stage pT2 N0 MX.

3. Discussion

Beckwith and Palmer first described the entity in 1978 as "rhabdomyosarcomatoid variant of Wilms tumor" due to the histologic similarity of the tumor cells to rhabdomyoblasts. Later with further immunohistochemical and cytogenetic studies it was confirmed to be a separate distinct tumor entity.⁵ Clinically patients present with mass in abdomen, hematuria and pain. RTK has propensity to metastasize very early to distant sites. Symptoms arising from metastases are common at diagnosis, which mainly affect the lungs, liver, brain, and less commonly bone.⁶ Radiological evaluation

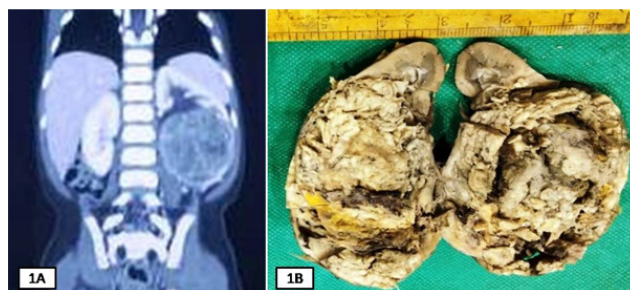


Fig. 1: A: CECT reveal a left renal tumor; B: Grossmicro photograph shows tumor occupying lower and mid region of kidney (100 x)

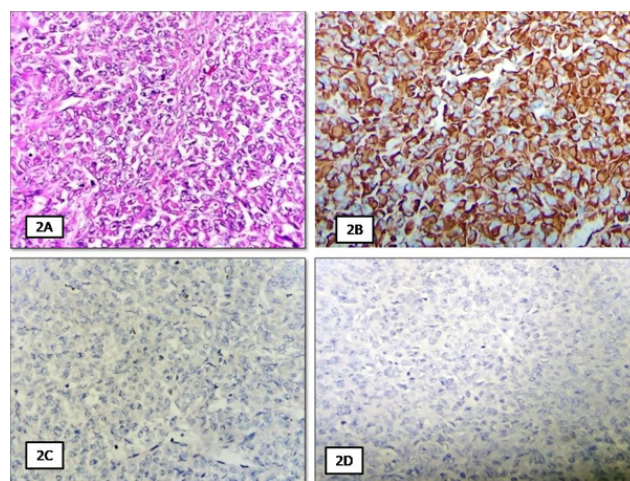


Fig. 2: A: Sheets of tumor cells separated by delicate fibrovascular septa (H&E stain, 100x); B: Tumor cells positive for Vimentin (IHC, 100x); C: Tumor cells negative for PAX8 (IHC, 100x); D: Tumor cells negative for CD99 (IHC, 100x)

can help in differentiating RTK from its closest mimicker i.e. Wilms tumor. Presence of lobulated heterogeneous mass with areas of hemorrhage, necrosis and calcification, sub-capsular fluid accumulations, vascular and local invasion is more favourable for RTK.⁷

Histologically the tumour cells have characteristic eccentric vesicular nuclei and eosinophilic cytoplasmic inclusions. Ultra structurally the inclusions are the irregularly distributed intermediate filament aggregates. Renal tumors having rhabdoid cellular morphology are Ewings sarcoma of kidney, desmoplastic small round cell tumor (DSRCT), pediatric CNS atypical teratoid / rhabdoid tumor, melanoma and collecting duct carcinoma of kidney. Clinical correlation, extensive histological sampling and IHC helps in excluding the differentials. The tumor cells are diffusely positive for vimentin and epithelial membrane antigen (EMA) and focal positive for cytokeratin (CK), neuron-specific enolase (NSE), S-100 protein(s-100) and synaptophysin.⁸

Chromosomal abnormalities associated with RTK are monosomy 22 and homozygous mutations and/or deletions of SMARCB1 genes responsible for gene transcription and tumor suppressive action. Biallelic inactivation of tumor suppressor gene INI1 leads to loss of nuclear expression of INI1/BAF47 protein, which is essential for development of both renal and extrarenal rhabdoid tumors.⁹ No effective treatment regimen has been established till now. The prognosis is dismal. Prognosis depends on the stage of the tumor at the time of diagnosis, age of patient and genetic factors. Mortality is 80-90% despite intensive multimodal chemotherapy, radiotherapy and/or surgical treatment.¹⁰

4. Conclusion

Rhabdoid tumor has clinical and good number of morphological differentials. Its clinical course and prognosis is worst. It is resistant to different treatment modalities and metastasizes widely. All these factors make it one of the most notorious pediatric neoplasms which should be diagnosed by the clinicians and pathologists at the earliest to save the life of patients.

5. Source of Funding

None.


6. Conflict of Interest

None.

References

- Bernstein L, Linet M, Smith MA, Olshan AF. Renal tumors. In: Ries LAG, Smith MA, Gurney JG, editors. Cancer Incidence and Survival among Children and Adolescents: United States SEER Program 1975-1995. National Cancer Institute, SEER Program. Bethesda, NIH Publ; 1999. p. 79–90.
- Bozlu G, Çıtak EC. Evaluation of renal tumors in children. *Turk J Urol*. 2018;44(3):268–73.
- Weeks DA, Beckwith JB, Mierau GW, Luckey DW. Rhabdoid tumor of kidney: a report of 111 cases from the National Wilms Tumor Study Pathology Center. *Am J Surg Pathol*. 1989;13:439–58.
- Parham DM, Weeks DA, Beckwith JB. The clinicopathologic spectrum of putative extrarenal rhabdoid tumors: an analysis of 42 cases studied with immunohistochemistry or electron microscopy. *Am J Surg Pathol*. 1994;18:1010–29.
- Sreedhar D, Shetty MVK, Choudhary A, Prasad KK, Naik N, Prasad BR. Malignant rhabdoid tumour of kidney - a rare aggressive tumour. *J Clin Sci Res*. 2016;5(1):61. doi:10.15380/2277-5706.jcsr.14.069.
- Ayaria Y, Rhoumaa SB, Boussaffaa H, Krartia M, Charfib L, Jrade M. Malignant rhabdoid tumor in a solitary kidney arising in an adult patient with chronic obstructive renal calculi. *Int J Surg Case Rep*. 2019;58:85–7.
- Chung CJ, Lorenzo R, Rayder S, Schemankewitz E, Guy CD, Cutting J, et al. Rhabdoid tumors of the kidney in children: CT findings. *Am J Roentgenol*. 1995;164(3):697–700. doi:10.2214/ajr.164.3.7863897.
- Peng HQ, Stanek AE, Teichberg S, Shepard B, Kahn E. Malignant Rhabdoid Tumor of the Kidney in an Adult: A Case Report and Review of the Literature. *Arch Pathol Lab Med*. 2003;127(9):e371–3. doi:10.5858/2003-127-e371-mrto tk.
- Ogino S, Ro JY, Redline RW. Malignant rhabdoid tumor: a phenotype? An entity?—a controversy revisited. *Adv Anat Pathol*. 2000;7:181–90.
- Trabelsi F, Bouthour H. Rhabdoid Tumor of the Kidney: A New Case of Prenatal Diagnosis with Metastases Immediately. *Med Surg Urol*. 2016;5(3):1–3. doi:10.4172/2168-9857.1000167.

Author biography

Sarojini Raman, Associate Professor  <https://orcid.org/0000-0002-9691-8486>

Goutami Das Nayak, Assistant Professor

Madhusmita Mohanty, Assistant Professor

Subrat Kumar Mohanty, Consultant Pediatric Surgeon

Urmila Senapati, Professor & HOD

Cite this article: Raman S, Nayak GD, Mohanty M, Mohanty SK, Senapati U. Aggressive uncommon pediatric renal tumor: Rhabdoid tumor of kidney. *Indian J Pathol Oncol* 2021;8(2):299-301.