



Original Research Article

Diagnostic utility of VEGF in breast lesions

H B Shashidhar¹, Aruna Lahari N^{1,*}, Bharathi M¹¹Dept. of Pathology, Mysore Medical College and Research Institute, Mysore, Karnataka, India

ARTICLE INFO

Article history:

Received 07-12-2020

Accepted 07-01-2021

Available online 19-05-2021

Keywords:

Breast cancer

Immunohistochemistry

VEGF

ABSTRACT

Introduction: Breast cancer has been one of the frequent cancers among women. VEGF is a potent angiogenic factor, contributes to tumor angiogenesis and is upregulated in various cancers. It plays a critical role in cancer progression and is of prognostic significance in breast cancers.

Aim: The aim of the study was to analyse the VEGF expression in various breast lesions ranging from benign to malignant in comparison with normal breast.

Materials and Methods: The study was done on 20 cases of normal breast, 40 cases of benign breast lesions and 40 cases of malignant breast lesions. The VEGF immunohistochemical overexpression was studied on formalin fixed paraffin embedded tissue sections.

Results: Statistical analysis using Chi square test was done and p value of <0.05 was considered significant. The intensity of VEGF expression was graded and score was assigned to each case.

Conclusions: The study revealed significant correlation between VEGF expression and malignancies of breast. It was noted that positive tumor cases had poor prognosis and had biologically aggressive behavior.

© This is an open access article distributed under the terms of the Creative Commons Attribution License (<https://creativecommons.org/licenses/by/4.0/>) which permits unrestricted use, distribution, and reproduction in any medium, provided the original author and source are credited.

1. Introduction

Around worldwide Breast cancer has been considered the most common cancer and it has caused higher rates of mortality and morbidity among women.¹ Several studies have been performed to demonstrate genetic changes and oncogene protein products which affect the mechanism of progression and differentiation of tumor growth. Angiogenesis is critical for the survival and progression for the tumor development and metastases to distant sites.^{2,3}

Vascular endothelial growth factor (VEGF) is a potent angiogenic factor and is crucial factor for tumor development, progression and metastasis.^{4,5} VEGF signaling helps in evading apoptotic stimuli in tumor cells and also beneficial in tumor migration and invasion.⁶⁻⁸ VEGF is an upregulated biomarker in various solid cancers including breast cancer. In comparison with normal or benign breast tissues, malignant breast lesions showed

higher levels of VEGF.⁹

Several studies have showed results that VEGF expression in tumour tissue has significant correlation with microvessel density and associated with poor prognosis.^{10,11} Our main objective was to study expression of VEGF mainly in breast cancer so that it can be useful for therapeutic purpose. And also its expression was studied in the normal breast and in benign breast lesions.

2. Materials and Methods

2.1. Study design

A retrospective study was conducted in the department of Pathology at Mysore Medical College and Research Institute during period of January 2019 to March 2020.

2.2. Source of data

A total of 100 cases were included out of which 20 cases were of normal breast tissue, 40 cases of benign breast

* Corresponding author.

E-mail address: aruna.n1910@gmail.com (A. Lahari N).

lesions and 40 cases of malignant lesions. The study group included women aged between 15 and 70 years irrespective of any other morbidity.

20 cases of normal breast tissue obtained from benign breast lesions are taken as control group. 40 cases of benign breast lesions including fibroadenoma and fibrocystic disease were compared with 40 cases of malignant lesions of study group which were between the age group of 15 and 70 years.

2.3. Specimen collection and examination

Tumour and breast tissue samples that have been obtained during surgery were sent to the Department of pathology, Mysore medical college and research institute, for histopathological diagnosis. Tumour tissue samples with invasive breast cancer were used, as well as normal breast tissue samples from patients with benign breast diseases.

The diagnosis was performed with hematoxylin-eosin stained sections. Tumours were classified according to the World Health Organization criteria. Modified Scarff-Bloom-Richardson grading system was used to assign grade to tumours. Tumour size was graded in three categories: I (tumour size was 0,1-2 cm), II (tumour size was 2-5 cm), and III (tumour size was >5 cm).

Appropriate formalin fixed paraffin embedded tissue sections were subjected to immunohistochemistry using VEGF antibody, VEGF immunoreactivity was considered as any positive staining in the cytoplasm of cells. The intensity of stained was graded as shown in Table 1.

Statistical analysis was performed using Chi square chart. If the p value was < 0.05, it was considered statistically significant.

3. Results

The study included normal breast tissue of 20 cases, benign breast lesions of 40 cases and invasive carcinoma breast of 40 cases.

The cases shown in Table 3 were in the age group between 15 and 70 years. The study showed that maximum were in age group of 31 to 45 years of age and accounted to 38% of total number of cases.

The Table 4 showed that out of 20 benign breast lesions 7 cases showed VEGF overexpression. 3 cases had moderate VEGF intensity and 4 cases with strong intensity.

According to Table 5, among malignant breast lesions 22 cases showed VEGF overexpression, maximum number of cases had moderate expression, around 30% had strong intensity and 24% with mild intensity.

Table 6 showed majority of the malignant cases belonged to higher grade and stage II followed by grade II and Stage III. Least number of cases were in grade I and stage I.

Table 7 showed VEGF expression in 10 out of 14 cases in stage II, 13 out of 15 cases in stage III and 9 out of 10

cases in stage IV.

Representative photographs of fibroadenoma breast in hematoxylin, positive staining of VEGF in fibroadenoma, invasive ductal carcinoma breast in hematoxylin 20x, 40x, positive VEGF staining in invasive ductal carcinoma breast 20x and 40x are shown in Figures 1, 2, 3, 4, 5 and 6 respectively.

Table 1: VEGF overexpression scoring

Score	Interpretation
0	Negative: None or <5% tumor cells positive
1	Mild: 5-10% tumor cells positive
2	Moderate: <25% tumor cells positive
3	Strong: 25-50% tumor cells positive
4	Highly strong: >50% tumor cells positive

Table 2: Distribution of cases

Nature of breast tissue	No of cases
Normal	20
Benign	40
Malignant	40
Total	100

Table 3: Age wise distribution of cases

Age group	No of cases
15-30	35
31-45	38
45-60	17
61-75	10
Total	100

Table 4: Pattern of VEGF expression in benign breast lesions

Intensity of staining VEGF	No of cases	Percentage
1	0	0
2	3	43
3	4	57
4	0	0

Table 5: Pattern of VEGF expression in malignant breast lesions

Intensity of staining of VEGF	No of cases	Percentage
1	8	24
2	15	46
3	10	30
4	0	0

4. Discussion

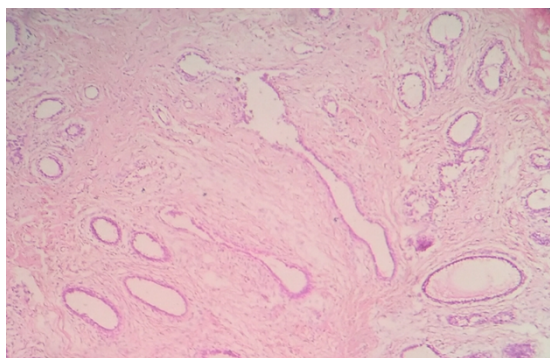
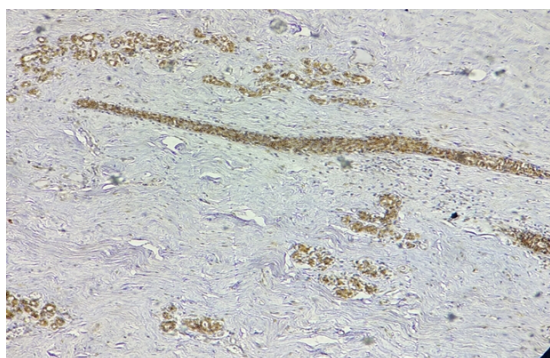
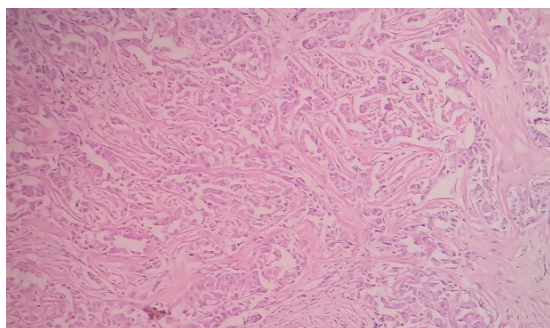
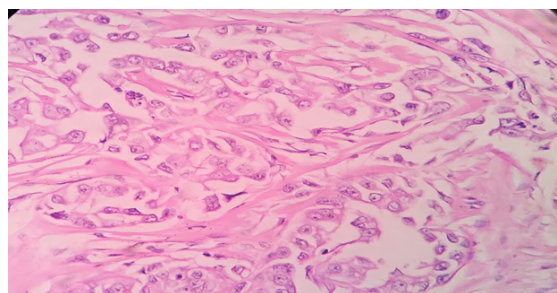
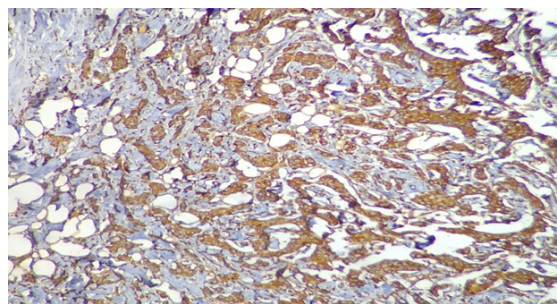
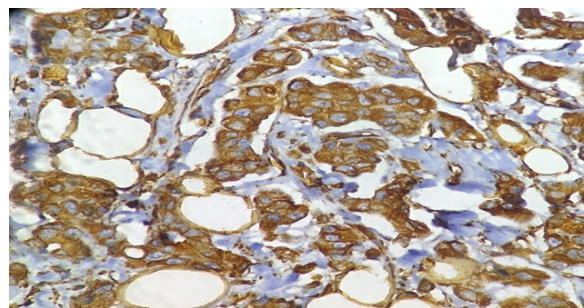
The results showed no significant correlation between VEGF overexpression and age. This is due to natural course of disease frequently occurring in older women. The results

Table 6: Grading of breast cancer

Grade	No of cases
I	4
II	16
III	20

Table 7: Staging of malignant breast lesions

Stage	Positive	Negative	Total
I	1	0	1
II	10	4	14
III	13	2	15
IV	9	1	10

**Fig. 1:** Fibroadenoma of breast (20x)**Fig. 2:** VEGF positive staining of fibroadenoma (20x)**Fig. 3:** Invasive ductal carcinoma breast (20x)**Fig. 4:** Invasive ductal carcinoma breast (40x)**Fig. 5:** Invasive ductal carcinoma breast showing positive staining of VEGF (20x)**Fig. 6:** Invasive ductal carcinoma showing positive staining of VEGF (40x)

are consistent with studies done by Obermair A et al and Li J et al.^{12,13}

The conducted study showed that VEGF expression was absent in the normal breast tissue comparable to studies conducted by Esraa A et al. and Yasushi Nakamura et al., showed negative expression of VEGF in the normal breast tissues.^{14,15}

The study showed that out of 40 cases of benign lesions of breast, 7 cases showed positive staining in benign breast lesions accounting to 17.5% which was almost nearing to the results of ES Al Harris et al.¹⁶ who had got around 19% positive staining in benign breast lesions. 33 cases showed positive staining in malignant breast lesions accounting to 82.5% which is similar to the study conducted by Yasushi Nakamura et al. who reported 83.7%.¹⁷ It was higher than the study conducted by Melanie Schmidt et al. who reported

60% VEGF overexpression in breast cancer.¹⁸

In relation to grading of tumors, the immunohistochemical expression of VEGF showed that 4 cases were grade 1 positive, 16 cases were grade 2 positive and 20 cases were grade 3 positive. There was statistically significant correlation of VEGF overexpression with grading of tumors. This was similar to studies conducted by Konecny GE et al. and Shankar R et al.^{19,20}

In stage, I tumors, a case showed overexpression of VEGF, out of 14 cases belonging to stage II maximum cases expressed VEGF overexpression and in stage IV all cases were positive for staining except for a single case. The number of cases were more in higher stage and there was statistically significant correlation of VEGF overexpression with staging of tumors. These findings were comparable to studies performed by AL-Harris et al.¹⁶ who found that staging of breast and VEGF overexpression had significant correlation.

5. Conclusion

VEGF overexpression can be used as a prognostic tool and for therapeutic purpose. It's overexpression in benign breast lesions may be associated with increased risk for development of breast cancer. Henceforth, advanced research is essential to study the risk of progression of benign lesions into cancer.

Since the VEGF overexpression showed statistical significance with grade and stage of tumor, it can be considered that positive tumors have poorer prognosis and aggressive behavior. The breast cancer genesis is a complex process, multifactorial and has very less understanding about the genetic changes. Much more research in this progress is needed to know the etiopathogenesis to integrate better therapeutic strategies.

6. Source of Funding

None.

7. Conflict of Interest

None.

References

- Berry DA, Cronin KA, Plevritis S, Fryback DG, Clarke L, Zelen M, et al. Effect of Screening and Adjuvant Therapy on Mortality From Breast Cancer. *Obstet Gynecol Surv.* 2006;61(3):179–80. doi:10.1097/01.ogx.0000201966.23445.91.
- Folkman J. Tumor angiogenesis: therapeutic implications. *N Engl J Med.* 1971;285(21):1182–6.
- Price DJ, Miralem T, Jiang S, Steinberg R, Avraham H. Role of vascular endothelial growth factor in the stimulation of cellular invasion and signaling of breast cancer cells. *Cell Death Differ.* 2001;12(3):129–35.
- Folkman J. The role of angiogenesis in tumor growth. *Semin Cancer Biol.* 1992;3:65–71.
- Weidner N, Semple JP, Welch WR, Folkman J. Tumor Angiogenesis and Metastasis — Correlation in Invasive Breast Carcinoma. *N Engl J Med.* 1991;324(1):1–8. doi:10.1056/nejm199101033240101.

- Mercurio AM, Lipscomb EA, Bachelder RE. Non-Angiogenic Functions of VEGF in Breast Cancer. *J Mammary Gland Biol Neoplasia.* 2005;10(4):283–90. doi:10.1007/s10911-006-9001-9.
- Barr M, Hayes DB, Harme J. Vascular endothelial growth factor is an autocrine survival factor for breast tumour cells under hypoxia. *Int J Oncol.* 2008;32:41–8. doi:10.3892/ijo.32.1.41.
- Liang Y, Brekken RA, Hyder SM. Vascular endothelial growth factor induces proliferation of breast cancer cells and inhibits the anti-proliferative activity of anti-hormones. *Endocr Relat Cancer.* 2006;13(3):905–19. doi:10.1677/erc.1.01221.
- Rice A, Quinn CM. Angiogenesis, thrombospondin, and ductal carcinoma in situ of the breast. *J Clin Pathol.* 2002;55:569–74.
- Ferrara N, Gerber HP, LeCouter J. The biology of VEGF and its receptors. *Nat Med.* 2003;9(6):669–76. doi:10.1038/nm0603-669.
- Toi M, Matsumoto T, Bando H. Vascular endothelial growth factor: its prognostic, predictive, and therapeutic implications. *Lancet Oncol.* 2001;2(11):667–73. doi:10.1016/s1470-2045(01)00556-3.
- Obermair A, Kucera E, Mayerhofer K, Speiser P, Seifert M, Czerwenka K, et al. Vascular endothelial growth factor (VEGF) in human breast cancer: Correlation with disease-free survival. *Int J Cancer.* 1997;74(4):455–8. doi:10.1002/(sici)1097-0215(19970822)74:4<455::aid-ijc17>3.0.co;2-8.
- Li J, Song ST, Jiang ZF, Liu XQ, Yan LD. Significance of microvascular density and vascular endothelial growth factor in breast cancer. *Chin J Oncol.* 2003;25(2):145–8.
- Esraa A. Expression of VEGF in Breast lesions. *Breast Cancer Res Treat.* 2010;66:183–90.
- Nakamura Y, Yasuoka H, Tsujimoto M, Yang Q, Tsukiyama A, Imabun S, et al. Clinicopathological Significance of Vascular Endothelial Growth Factor-C in Breast Carcinoma with Long-Term Follow-Up. *Mod Pathol.* 2003;16(4):309–14. doi:10.1097/01.mp.0000062858.98295.9f.
- Al-Harris ES, Al-Janabi A, Al-Toriahi KM, Yasseen AA. Over expression of vascular endothelial growth factor in correlation to Ki-67, grade and stage of breast cancer. *Saudi Med J.* 2008;29(8):1099–1104.
- Nakamura Y, Yasuoka H, Tsujimoto M, Yang Q, Tsukiyama A, Imabun S, et al. Clinicopathological Significance of Vascular Endothelial Growth Factor-C in Breast Carcinoma with Long-Term Follow-Up. *Mod Pathol.* 2003;16(4):309–14. doi:10.1097/01.mp.0000062858.98295.9f.
- Schmidt M, Voelker HU, Kapp M, Dietl J, Kammerer U. Expression of VEGFR-1 (Flt-1) in breast cancer is associated with VEGF expression and with node-negative tumour stage. *Anticancer Res.* 2008;28(3A):1719–24.
- Konecny GE, Meng YG, Untch M, Wang HJ, Bauerfeind I, Epstein M, et al. Association between HER-2/neu and Vascular Endothelial Growth Factor Expression Predicts Clinical Outcome in Primary Breast Cancer Patients. *Clin Cancer Res.* 2004;10(5):1706–16. doi:10.1158/1078-0432.ccr-0951-3.
- Shankar R, Tiwary SK, Khanna R, Kumar M, Khanna AK. Tumor angiogenesis: determined by vegf expression, mags scoring, doppler study, as prognostic indicator in carcinoma breast. *Internet J Surg.* 2006;8(1):5.

Author biography

H B Shashidhar, Professor

Aruna Lahari N, Post Graduate

Bharathi M, Professor and HOD

Cite this article: Shashidhar HB, Lahari N A, Bharathi M. Diagnostic utility of VEGF in breast lesions. *Indian J Pathol Oncol* 2021;8(2):276-279.