



Original Research Article

A histopathological study of urinary bladder neoplasms

Preeti N Jhaveri¹, Seva V Makwana^{2,*}, Kishan K Oza¹, Cherry K Shah¹¹Dept. of Pathology, Smt. NHL Municipal Medical College, Ahmedabad, Gujarat, India²Rajsthan Hospital, Ahmedabad, Gujarat, India

ARTICLE INFO

Article history:

Received 07-10-2020

Accepted 26-10-2020

Available online 20-02-2021

Keywords:

Invasive papillary urothelial carcinoma

Muscle invasion

Urinary bladder neoplasms

ABSTRACT

Background: The present study was carried out to describe the Histopathological features of various neoplasms in the urinary bladder biopsies and to categorize the neoplastic lesions according to W.H.O (2016)/ISUP classification of urinary bladder tumors.

Materials and Methods: A total of 37 cases, 28 urinary bladder biopsies (TURBT) and 9 cystectomy specimens of urinary bladder neoplasia [histologically proved] of patients were studied retrospectively over the period from June 2016- Oct 2018 in Pathology department of Smt. N.H.L. medical college. All cases of urothelial carcinomas were graded histologically according to WHO (2016)/ISUP classification.

Results: Maximum numbers of patients are in age group 60-69 years. Males (78.37%) are more frequently affected as compared to female. The most frequent Neoplastic findings in Urinary bladder is Invasive Papillary Urothelial carcinoma (81.06%); Low grade (37.8%) being more common than High grade (35.14%). A large percentage (80%) of high grade invasive urothelial cell carcinomas presented with muscle invasion.

Conclusion: Invasion to the muscle propria layer correlates with high grade tumor. In 18.5% cases detrusor muscle was absent, hence the importance of including detrusor muscle in the biopsy specimens needs to be emphasized. We must accept the fact that grading is highly subjective and that in future various molecular and immunohistochemical studies will provide better reproducibility.

© This is an open access article distributed under the terms of the Creative Commons Attribution License (<https://creativecommons.org/licenses/by/4.0/>) which permits unrestricted use, distribution, and reproduction in any medium, provided the original author and source are credited.

1. Introduction

Urinary bladder neoplasm is responsible for significant morbidity and mortality. Urothelial carcinoma is the commonest type accounting for 90% of all primary tumors of the bladder.¹

Urinary bladder cancer is a complex and heterogeneous disease with a broad spectrum of histological findings and potentially lethal behavior. Despite advances in surgical techniques as well as intravesical and systemic therapies, patients with muscle invasive carcinoma experience disease progression, recurrence and eventual death.²

External risk factors are smoking, occupational carcinogens, artificial sweeteners, Schistosoma hematobium

infection in endemic areas.³

Although progress has been made in non-invasive imaging, bladder cancer diagnosis and treatment are done through physical examination, cystoscopic evaluation and histopathologic analysis.

2. Aims and Objectives

1. To describe the Histopathological features of various neoplasm in the urinary bladder biopsies.
2. To assess various types of urinary bladder neoplasm with regard to age and sex distribution.
3. To categorize the neoplastic lesions according to W.H.O (2016)/ISUP classification of urinary bladder tumors.

* Corresponding author.

E-mail address: drsevamakwana@gmail.com (S. V. Makwana).

3. Materials and Methods

3.1. Source of data

A total of 37 cases of urinary bladder neoplasm [histologically proven] of patients admitted in V.S.Hospital were studied over the period from June 2016- Oct 2018 in Department of Pathology. A detailed history was taken. Findings were recorded in the Performa designated for the study. Macroscopically various parameters like size, configuration and consistency were noted. Tissues were fixed adequately followed by standard processing and staining. All cases of urothelial carcinomas were graded histologically according to WHO (2016)/ISUP classification.

3.2. Inclusion criteria

All cystoscopic biopsies and radical cystectomy specimens that turned out to be neoplastic were included in the study.

3.3. Exclusion criteria

Autolysed specimen and inadequate biopsies were excluded from the study.

4. Results

In the present study, of total 37 patients - 29 were male and 8 female with M: F ratio of 3.63:1.

Table 1: Incidence of urinary bladder neoplasms with respect to gender

Histological Type	Male	Female	Total	Percentage (%)
Leiomyoma	0	1	1	2.70
PUNLMP*	2	1	3	8.11
Non-invasive Urothelial Carcinoma, Low Grade	1	2	3	8.11
Invasive Urothelial Carcinoma, Low Grade	13	1	14	37.84
Invasive Urothelial Carcinoma, High Grade	10	3	13	35.14
Squamous cell Carcinoma	2	0	2	5.41
Embryonal Rhabdomyosarcoma, Botryoid type	1	0	1	2.70
Total	29	8	37	100

*PUNLMP – Papillary Urothelial neoplasm of low malignant potential

Haematuria was the most common clinical symptoms in 86.48% cases followed by burning micturition (5.4%),

abdominal pain (5.4%) and incidental USG finding (2.7%).

Table 2: Age-wise distribution of urinary bladder neoplasms

Age group (years)	Total no. of patients	Percentage (%)
<30	1	2.70
30-39	3	8.11
40-49	7	18.92
50-59	8	21.62
60-69	10	27.03
70-79	7	18.92
80-89	1	2.70
Total	37	100

Lateral wall was the most common location of urinary bladder tumor comprising 46%, followed by anterior wall 22%, posterior wall and bladder neck 13% each.

Amongst 37 neoplastic lesions, 33 cases (89%) were of urothelial neoplasm, 2 cases of Squamous cell carcinoma, 1 case each of Embryonal Rhabdomyosarcoma and Leiomyoma.

Of 33 urothelial neoplasm cases, 6 cases were noninvasive urothelial neoplasm and 27 cases were invasive urothelial neoplasm.

Out of 6 cases of noninvasive urothelial neoplasm, low grade noninvasive papillary urothelial carcinoma was noted in 3 case and 3 cases were of papillary urothelial neoplasm with a low malignant potential (PUNLMP).

14 cases of low grade papillary urothelial carcinoma (PUCLG) and 13 cases of high grade papillary urothelial carcinoma (PUCHG) were noted of 27 invasive urothelial carcinoma cases.

Table 3: Presence of muscle invasion in urothelial bladder carcinoma

Grade	Muscle Invasion		Total
	Present	Absent	
Invasive Urothelial Carcinoma, Low Grade	2(16.67%)	10(83.33%)	12
Invasive Urothelial Carcinoma, High Grade	8(88.89%)	1(11.11%)	9
Total	10	11	21

According to the invasion, Lamina Propria invasion was present in 26 cases while the muscular invasion was present in 10 patients.

The detrusor muscle was absent in 6 cystoscopic biopsy. Hence, muscle invasion could be assessed in the remaining 21 cases. 10 cases showed muscle invasion of which 2 cases were of low grade and 8 cases were high grade Invasive Urothelial Carcinoma.

In the present study, differentiation was present in 2 cases and both of them showed squamous differentiation.

Out of the 27 cases of Urothelial Carcinoma, 11 were superficial /or in the early stage (pTa and pT1) and 10 cases were muscle invasive (pT2).

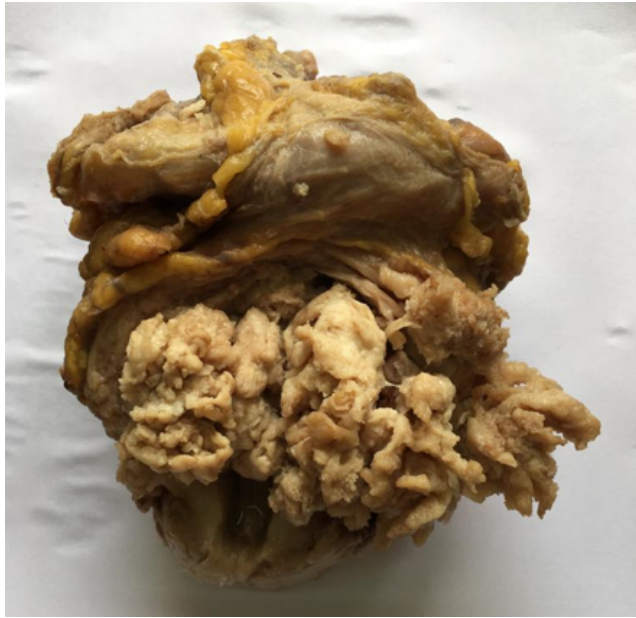

Fig. 1: Gross appearance of papillary urothelial carcinoma in radical cystectomy specimen

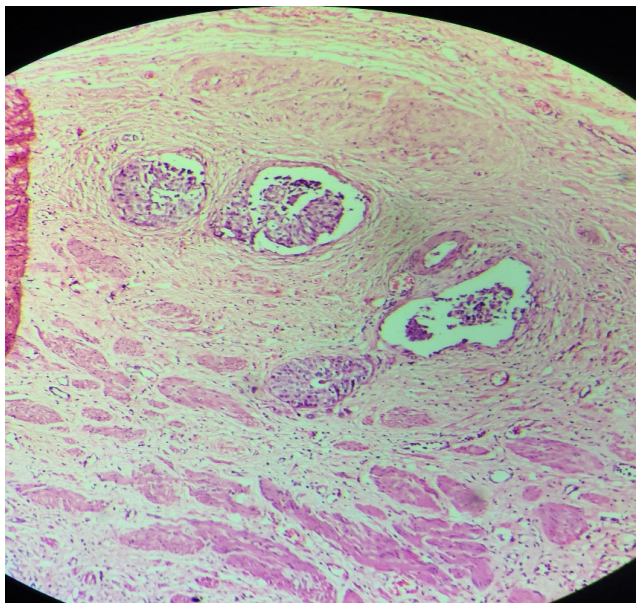


Fig. 2: Muscularis propria invasion (H&E Stain; 10x)

5. Discussion

In present study emphasis is kept on the histological grading and staging of bladder tumors. Bladder tumor diagnosis and monitoring is done by combination

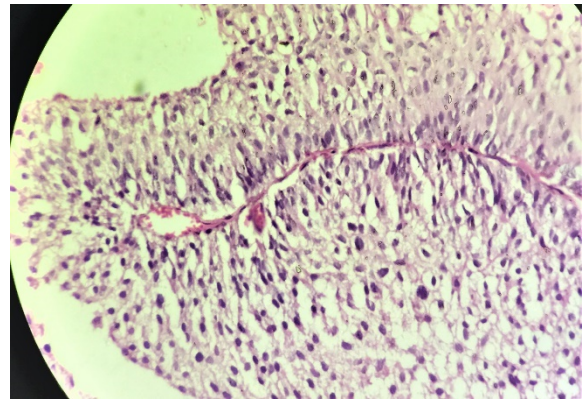


Fig. 3: Low grade papillary urothelial carcinoma (H&E Stain; 10x)

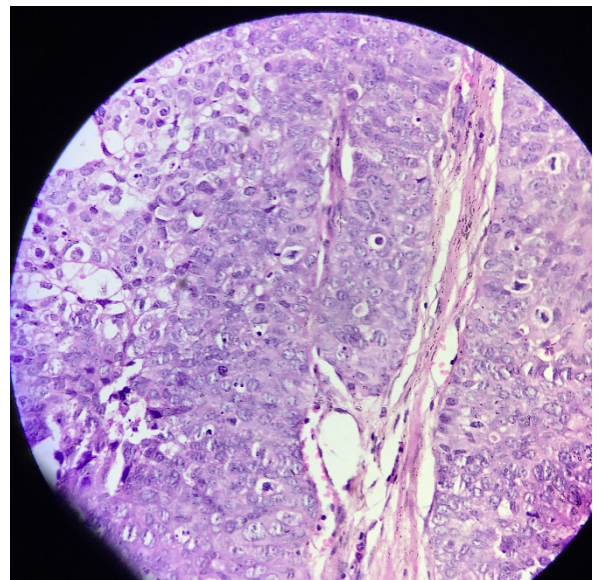


Fig. 4: High grade papillary urothelial carcinoma (H&E Stain; 10x)

of cystoscopy, histopathology and urine cytology,⁴ Histopathology remains mainstay for diagnostic and therapeutic purpose. Histopathology also poses limitations due to friable nature of bladder tumors, technical error and also interpretation errors from artifacts that mimic tumor. Excluding muscle fibers in cystoscopic biopsy can lead to incorrect histological grading and staging of the tumor. Most of the times these problems can be avoided by studying serial sections, using special stains and by encouraging inclusion of muscle layer during cystoscopic biopsy.

Present study showed peak age incidence of cases in 6th decade, 10 cases (27.02%) followed by the 5th decade, 8 cases (21.62%). Least number of cases was seen in 1st and 8th decade. This observation is well correlated with other studies.^{5,6}

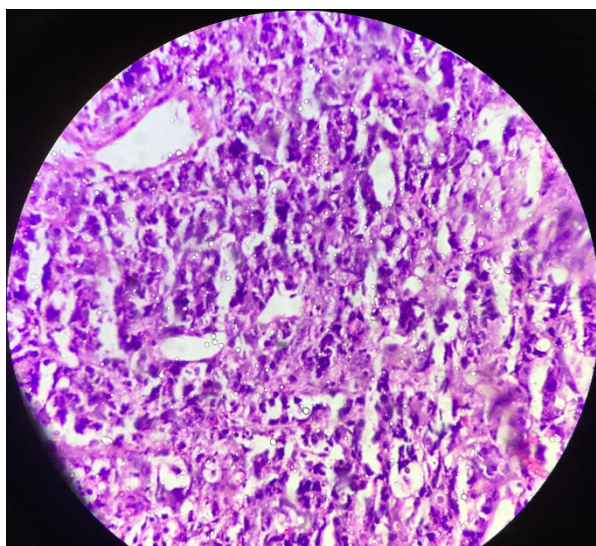


Fig. 5: Poorly differentiated urothelial Carcinoma (H&E Stain; 40x)

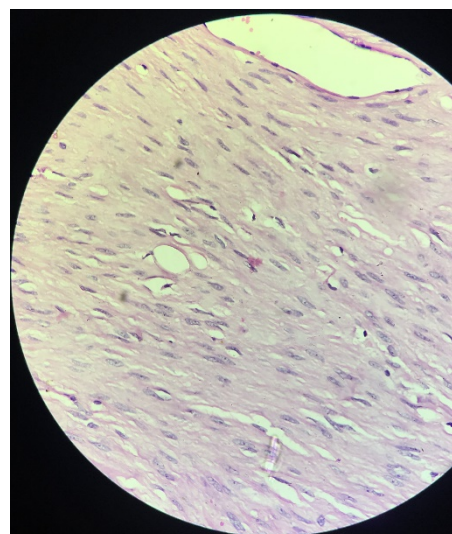


Fig. 7: Leiomyoma of urinary bladder (H&E Stain;10x)

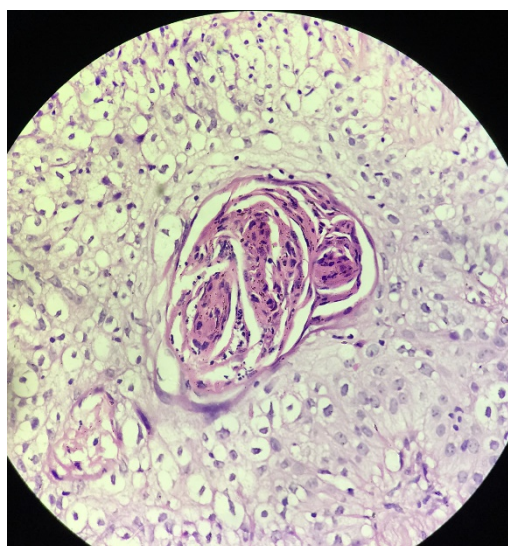


Fig. 6: Urothelial carcinoma with squamous differentiation (H&E Stain; 10x)

Cigarette smoking, industrial exposure to acrylamine in male leads to higher chance of bladder tumor in them.

Nearly 89% tumors were malignant in the present study, Urothelial carcinoma being the most common malignant lesion followed by Squamous cell carcinoma and Embryonal Rhabdomyosarcoma.

Detrusor muscle layer was absent in the 6 cystoscopic biopsies. This can lead to incorrect staging and grading of tumor. Hence, including muscle layer in the cystoscopic biopsy specimens is very important.

Of the remaining 21 cases that included muscle layer, muscle invasion was seen in 14% cases of low grade and

62% cases of high grade urothelial carcinoma. Similar observation was also made by Laishram et al.,⁷ and by Vaidya et al.⁵ From this we can say that muscle invasion also correlates to high grade tumor.

Cystectomy specimens showed 5 cases of High Grade Invasive urothelial carcinoma and 2 cases each of Low grade Invasive urothelial carcinoma and Squamous cell carcinoma out of 9 specimens received.

Cystoscopic biopsies of 7 patients who underwent cystectomy were accessed in our department previously.

Of these 7 cases, one case diagnosed as Invasive Urothelial carcinoma with squamous differentiation in cystoscopic biopsy was diagnosed as Squamous cell carcinoma in radical cystectomy specimen.

While another case of Invasive Urothelial carcinoma with squamous differentiation in radical cystectomy specimen was reported as Squamous cell carcinoma in cystoscopic biopsy.

This usually happens when only a small portion of is obtained in a biopsy specimen; problems rarely arise when the entire lesion is available for examination.

One case diagnosed as High grade invasive urothelial carcinoma in TURBT underwent chemotherapy treatment followed by Total cystectomy which showed no evidence of residual tumor.

Perivesical adipose tissue involvement (T3) by tumor was seen in 2 cases.

Two radical Cystectomy Specimen had lymph node metastasis.

Associated pathology included chronic cystitis in 3 cases, 1 case each of associated chronic pyelonephritis, chronic prostatitis and granulomatous inflammation.

6. Conclusion

In present study, Urothelial carcinoma was the commonest lesions seen in cystoscopic biopsies as well as cystectomy specimen. Males are more commonly affected than females. Majority of patients were in the age group of 50 to 70 years. A large percentage of high grade urothelial carcinomas presented with muscle invasion. Inclusion of muscle layer in the cystoscopic biopsy helps in accurate diagnosis and staging of tumor. This usually happens when only a small portion of a neoplasm is obtained in a biopsy specimen; problems rarely arise when the entire lesion is available for examination.

7. Conflict of Interest

The authors declare that there is no conflict of interest.

8. Source of Funding

None.

References

1. Rosai J. Rosai and Ackerman's surgical pathology. 11th ed. Edinburgh: Mosby; 2017.
2. Gray H. The anatomy of Human body. Philadelphia: Lea & Febiger; 1918.
3. Epstein JI. The lower urinary tract and male genital system. In: Kumar V, Abbas AK, Fausto N, editors. Robbins and Cotran Pathologic Basis of Disease. Philadelphia: Saunders; 2004. p. 1023–58.
4. Muhammed M, Javed IK, Altaf H, Manzoor H, Syed AN. Urinary bladder tumours in southern Pakistan: A histopathological perspective. *Middle East J Cancer*. 2014;5(3):167–73.
5. Vaidya S, Lakhey M, Sabira KC, Hirachand S. Urothelial tumours of the urinary bladder: A Histopathological study of cystoscopic biopsies. *JNMA J Nepal Med Assoc*. 0191;52:475–8.
6. Shrestha EP, Karmacharya K. Profiles of histopathological lesions of urinary bladder: A five years study. *J Pathol Nepal*. 2016;6(12):1001–4. doi:10.3126/jpn.v6i12.16287.
7. Laishram RS, Kipgen P, Laishram S, Khuraijam S, Sharma DC. Urothelial Tumors of the Urinary Bladder in Manipur: A Histopathological Perspective. *Asian Pac J Cancer Prev*. 2012;13(6):2477–9. doi:10.7314/apjcp.2012.13.6.2477.

Author biography

Preeti N Jhaveri, Assistant Professor

Seva V Makwana, Pathologist

Kishan K Oza, 2nd Year Resident

Cherry K Shah, Professor and HOD

Cite this article: Jhaveri PN, Makwana SV, Oza KK, Shah CK. A histopathological study of urinary bladder neoplasms. *Indian J Pathol Oncol* 2021;8(1):59-63.