



## Case Report

# Leiomyoadenomatoid tumour of testicular tunica – A rare entity

Chitrawati B Gargade<sup>1</sup>, Archana H Deshpande<sup>1,\*</sup>

<sup>1</sup>Dept. of Pathology, Andaman and Nicobar Islands Institute of Medical Sciences, Port Blair, Andaman & Nicobar, India



### ARTICLE INFO

#### Article history:

Received 24-11-2019

Accepted 02-01-2020

Available online 25-05-2020

#### Keywords:

Adenomatoid tumor

Leiomyoadenomatoid (LMAT) tumor

Tunica of testis

### ABSTRACT

Adenomatoid tumors are distinctive genital tract neoplasms that occur in both men and women. These are commonly located in epididymis, uterus, fallopian tubes, ovary, testicular tunica and spermatic cord. Rarely they are seen in extragenital locations like adrenal, bladder, pancreas, heart, pleura, mesentery, omentum and lymph nodes. Adenomatoid tumors arising from the testis are rare as compared to those arising from epididymis. Leiomyo-adenomatoid (LMAT) tumor is a variant of adenomatoid tumor with predominance of smooth muscle component. Twelve cases of Leiomyo-adenomatoid (LMAT) tumor of uterus and only three cases of LMAT of epididymis have been reported. We report an extremely rare case of LMAT arising from tunica of testis in a 58 year old male.

© 2020 Published by Innovative Publication. This is an open access article under the CC BY-NC-ND license (<https://creativecommons.org/licenses/by/4.0/>)

## 1. Introduction

Adenomatoid tumor is a benign tumor of mesothelial cells characterised microscopically by numerous gland-like spaces, tubules or cords lined by benign epithelial cells. The stroma consists of fibrous tissue and may contain smooth muscle. At the periphery the tumour shows lymphoid infiltrate. In some cases, smooth muscle component is more than adenomatoid component and mimic leiomyoma. The adenomatoid tumors with predominance of smooth muscle component are termed as Leiomyo-adenomatoid (LMAT) tumor.<sup>1,2</sup> Out of fifteen reported cases of Leiomyo-adenomatoid (LMAT) tumor; twelve are uterine and three are from epididymis. Leiomyoadenomatoid tumour having signet ring like epithelial cells and lymphoid infiltrate may sometimes mimic adenocarcinoma with desmoplasia. We are reporting this case of Leiomyo-adenomatoid (LMAT) tumor of testicular tunica in an adult male to recognize this rare entity.

## 2. Case History

A 58 year old male presented with progressively increasing painless swelling of the left scrotum for 6 months. There was no history of trauma. His past and personal history was insignificant. On local examination scrotum was enlarged with slightly irregular left testis at the lower pole. There was no palpable varicocele or hernial sac. The contralateral testis was normal. Routine laboratory tests including complete blood count, blood biochemistry, serum  $\alpha$ -fetoprotein, placental alkaline phosphatase, and  $\beta$ -human chorionic gonadotropin levels were within normal limits. Left orchidectomy was performed.

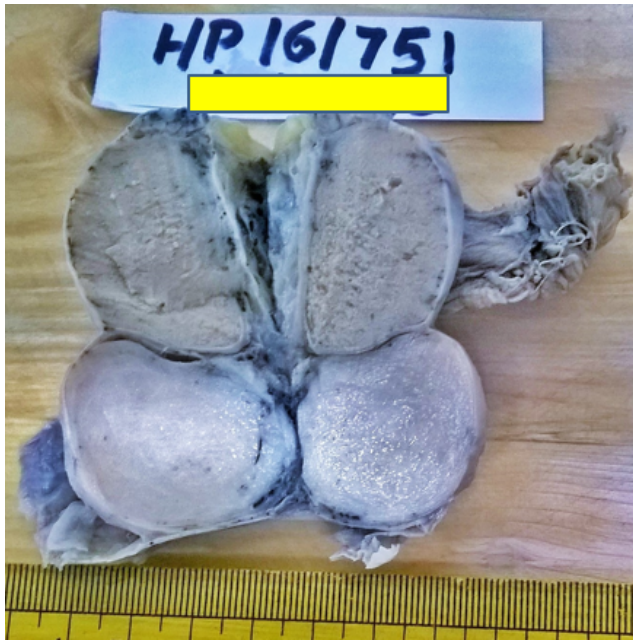Grossly, the left orchidectomy specimen measured 5.5 x 3.5 cm. Cut section showed a well circumscribed non-encapsulated, firm, homogenous grey white mass measuring 3.5 x 3.cms [Figure 1]. Surrounding testicular parenchyma was unremarkable. The spermatic cord and the epididymis appeared uninvolved.

Microscopically, a well demarcated mass separate from surrounding normal testicular tissue [Figure 2] was seen.

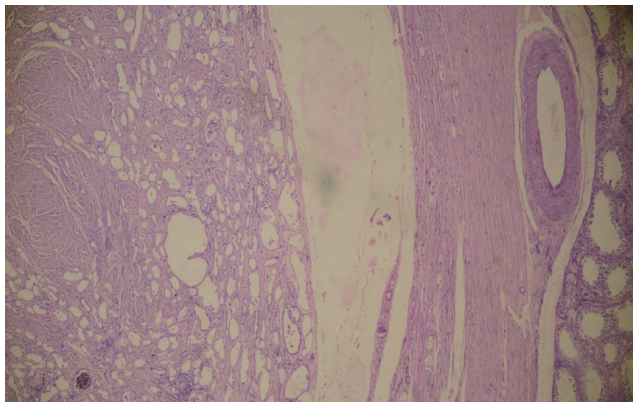
Tumour showed irregular slit like and glandular spaces lined by cells with moderate eosinophilic vacuolated cytoplasm and vesicular nuclei with inconspicuous nucleoli [Figure 3].

\* Corresponding author.

E-mail address: [ahdesh@gmail.com](mailto:ahdesh@gmail.com) (A. H. Deshpande).



**Fig. 1:** Gross: Well encapsulated homogeneous grey white tumor (marked with red arrow) arising from tunica testis with uninvolved testis (marked with black arrow), spermatic cord, epididymis



**Fig. 2:** LMAT tumor of testis with adjacent normal testis (H&E 40X)

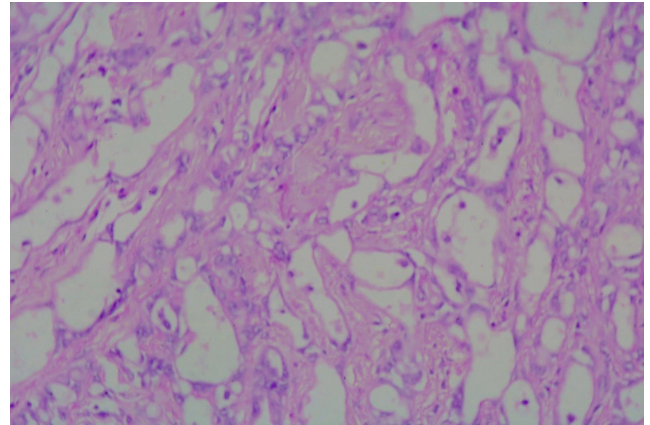
No increased mitotic activity, pleomorphism or nuclear hyperchromatism was seen. Stroma was composed of spindle cells predominantly [Figure 4].

Spindle cells were positive for smooth muscle actin on immunohistochemistry [Figure 5].

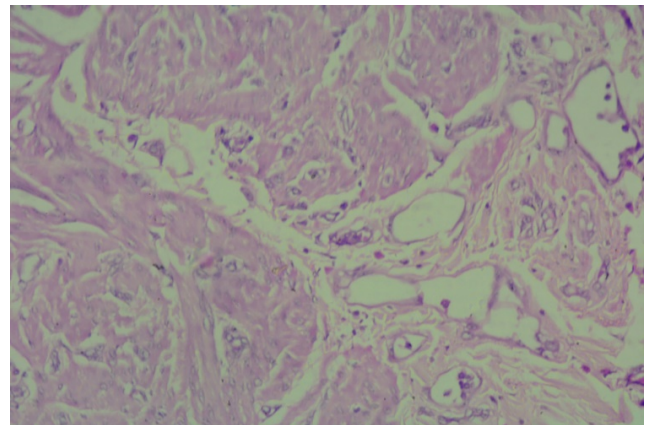
Tumor at periphery showed lymphoid aggregates [Figure 6].

The testis, spermatic cord and epididymis were unremarkable on microscopy.

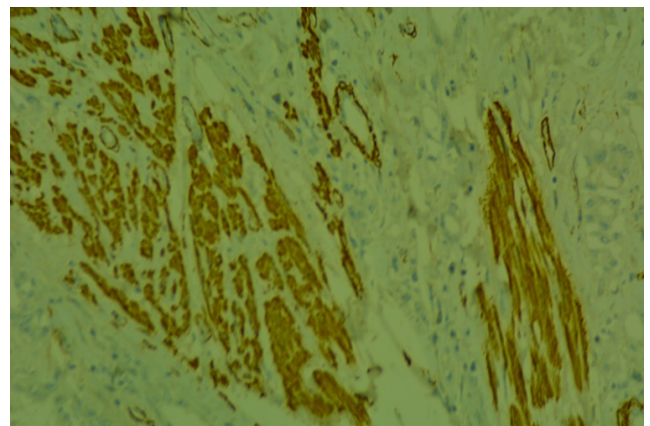
The diagnosis of Leiomyoadenomatoid tumour (LMAT) arising from tunica of testis was confirmed based on the presence of predominant smooth muscles in an adenomatoid tumor.



**Fig. 3:** Cystic spaces lined by vacuolated benign epithelium. (H&E 400 X)



**Fig. 4:** Adenomatoid tumor with prominent smooth muscle (H&E 100X)



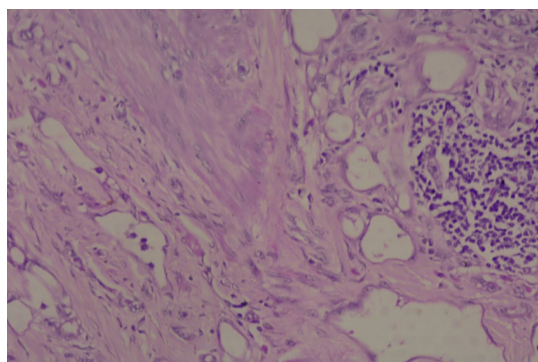
**Fig. 5:** Smooth muscle actin was diffusely positive in spindle cell bundles (SMA 100X).

**Table 1:** Details of Uterine LMAT reported till date

S. No.	Author	Age(yr.)	Size of the tumor (cm)
1	Amre et al. 2005 <sup>3</sup>	52	2.5
2	Hong et al. 2009 <sup>2</sup>	24	4
3	Erra et al. 2009 <sup>4</sup>	44	3
4	Mathew et al 2009 <sup>5</sup>	51	3
5	Amérigo et al. 2010 <sup>6</sup>	55	2.5
6	Pransgaard et al. 2013 <sup>7</sup>	24	3
7	Dobrosz et al. 2013 <sup>8</sup>	57	3.5
8	Ranjan et al 2015 <sup>9</sup>	40	2
9	Ranjan et al. 2015 <sup>9</sup>	36	2.5
10	Ranjan et al. 2015 <sup>9</sup>	43	1.2
11	Ersavas et al 2016 <sup>10</sup>	30	4.5
12	Sarma, et al 2016 <sup>11</sup>	45	2

**Table 2:** Details of LMAT in male genital tract.

S. No.	Author	Age(yr.)	Side and site of the tumor	Size of the tumor (cm)
1	Kausch et al. 2002 <sup>12</sup>	63	Right Epididymis	3
2	Canpolak et al. 2013 <sup>13</sup>	76	Right Epididymis	3
3	Cazorla et al, 2014 <sup>14</sup>	57	Right Epididymis	2.5
4	Present case	57	Left tunica testis	3.5

**Fig. 6:** Smooth muscle and lymphoid infiltrate (H&E 400X)

After two years post-surgery follow up, patient is asymptomatic and there is no evidence of recurrence.

### 3. Discussion

An adenomatoid tumor on microscopy comprises of two major elements, epithelial cells and fibrous stroma. The epithelial-like cells are arranged in a network of tubules, cords, channels and microcystic spaces. The lining cells have bright eosinophilic cytoplasm, small round-oval nuclei and do not show any pleomorphism or atypical mitoses. The cells sometimes show vacuolated cytoplasm and resemble signet ring cells. The fibrous stroma may be hyalinised and may contain smooth muscle. Stroma at periphery shows lymphocytic infiltrate.

The majority of adenomatoid tumors are readily diagnosed based on location and characteristic microscopic

features. Presence of smooth muscle with lymphocytic infiltrate and signet ring cells may lead to misdiagnosis. The differential diagnosis includes metastatic carcinoma, malignant mesothelioma, histocytoid haemangioma and large cell calcifying sertoli cell tumour with cord like pattern. Lack of pleomorphism, atypia, mitosis, absence of epithelial mucin, CEA negativity, low Ki-67 proliferation index and positive calretinin and HBME-1 mesothelial markers are findings in favor of adenomatoid tumor.

The spindle cell stroma, which is usually sparse and fibroblastic, may be more cellular and show myoid features, mimicking leiomyoma or adenomyoma. Some degree of smooth muscle cell hyperplasia can be seen in association with Adenomatoid tumor (AT) of the uterus and has been interpreted as a reactive phenomenon, whereas extrauterine forms frequently contain intermingled fibroblastic tissue. The term “Leiomyoadenomatoid tumor” was first described by Epstein in 1992 as a variant of adenomatoid tumor with a prominent smooth muscle component.<sup>1</sup>

The most commonly accepted origin of ATs is the surface mesothelium, mesothelial inclusions or displaced mesothelial tissue (which explains the occurrence of ATs at extragenital sites). Other possible origins of these tumors include the coelomic epithelium and pluripotent mesenchymal cells that have the potential to differentiate into submesothelial spindled cells and mesothelial cells.

The histogenesis of leiomyoadenomatoid tumors is also a subject to debate. Some authors support the hypothesis that this rare entity should be considered as a subtype of adenomatoid tumors, some think that it represents a collision neoplasia, and others think that it is the result of a

common adenomatoid tumor associated to a reactive smooth muscle hyperplasia.<sup>2</sup>

Twelve cases of LMAT uterus have been reported in the literature [Table 1].<sup>2–11</sup> After extensive literature search we could find only three cases of epididymal LMAT [Table 2].<sup>12–14</sup>

Cases with leiomyoadenomatoid tumor reported in male genital tract are very rare. Kausch<sup>12</sup> has reported first case of leiomyoadenomatoid tumor localized in epididymis in 2002 and later only two cases LMAT of epididymis were reported; one by Canpolat<sup>13</sup> and another by A. Cazorla.<sup>14</sup>

Adenomatoid tumors can be seen in all ages but are more commonly seen in third and fourth decades of life. In most of the cases they present as painless, firm, intrascrotal mass of less than 2 cm diameter. Out of three Leiomyoadenomatoid tumors of epididymis reported in literature, one was seen in sixth and other in seventh decade while one was seen in 5<sup>th</sup> decade of life. In our case, the patient was 58 year old and presented with painful left scrotal swelling.

All three cases of epididymal LMATS reported in literature affected right side of the testis with sizes ranging from 2 cm to 3.5 cm. One of the tumors showed large areas of necrosis. LMAT in present case was seen from left tunica testis. The tumor in our case was 3.5 cm in size and did not show any areas of haemorrhage or necrosis.

No recurrence or malignant transformation has ever been reported in adenomatoid tumors.<sup>10</sup>

Two years clinical follow up in our case was uneventful.

#### 4. Conclusion

LMAT of the female genital tract is comparatively common; however it is very rare in male genital tract. Only three cases of LMAT of epididymis are reported in the literature. To the best of our knowledge this is the first case of LMAT of testicular tunica reported in Indian and Western literature. This variant of adenomatoid tumor should be kept in mind to avoid misdiagnosis as a malignant tumor and unnecessary extensive surgery.

#### 5. Source of Funding

None.

#### 6. Conflict of Interest

None.

#### References

1. Epstein JI. Urologic disorders: Differential diagnosis in pathology. vol. 192; p. 173–4.
2. Hong R, Choi DY, Choi SJ, Lim SC. Case Report multicentric infarcted leiomyoadenomatoid tumor: A. *Int J Clin Exp Pathol.* 2009;2:99–103.
3. Amre R, Constantino J, Lu S, Charney D. Pathologic quiz case: a 52-year-old woman with a uterine mass. *Arch Pathol Lab Med.* 2005;129(3):77–8.
4. Erra S, Pastormerlo M, Gregori G, Costamagna D, Pavesi M. A case of leiomyoadenomatoid tumour of uterine serosa: speculations about differential diagnosis. *BMJ Case Rep.* 2009;2009. doi:10.1136/bcr.02.2009.1586.
5. Mathew M, Goel G. Leiomyoadenomatoid tumor of the uterus. *Turkish J Pathol.* 2010;26(2):168–9.
6. Amérigo J, Amérigo-Góngora M, Giménez-Pizarro A, Velasco FJ, Gallardo SP, González-Cámpora R. Leiomyo-adenomatoid tumor of the uterus: a distinct morphological entity? *Arch Gynecol Obstet.* 2010;282(4):451–4.
7. Prangsgaard T, Lykke R, Hansen ES. Leiomyo-Adenomatoid Tumor of the Uterus: Report of a Rare Entity. *J Gynecol Surg.* 2013;29(4):219–21.
8. Dobrosz Z, Paleń P, Własczuk P, Stojko R. An atypical leiomyoadenomatoid tumor of the uterus – a case report and literature review. *Polish Gynaecol.* 2013;84(8):730–2.
9. Ranjan R, Singh L, Nath D, Sable MN, Malhotra N, Bhatla N, et al. Uterine adenomatoid tumors: A study of five cases including three cases of the rare leiomyoadenomatoid variant. *J Obstet Gynecol.* 2015;65(4):255–8.
10. Ersavas S, Eiiyatkin N, Sayhan S, Zihni İ, Sargül Ç, Yagc A. 2015.
11. Sarma NH, Srinivasulu M, Suchitra MJ. Leiomyoadenomatoid tumor of the uterus: Report of a rare entity and review of the literature. *Indian J Pathol Microbiol.* 2014;57(3):450–2.
12. Kausch I, Galle J, Büttner H, Böhle A, Jocham D. Leiomyo-adenomatoid Tumor of the Epididymis. *J Urol.* 2002;168(2):636.
13. Canpolat T, Bolat F, Kocer NE, Turunc T. Leiomyoadenomatoid tumor of the epididymis. *J Clin Anal Med.* 2013;4(1):18–20.
14. Cazorla A, Algros MP, Bedgedjian I, Chabannes E, Camparo P, Valmary-Degano S. Epididymal leiomyoadenomatoid tumor: A case report and review of literature. *Curr Urol.* 2013;7(4):195–8.

#### Author biography

**Chitrawati B Gargade** Associate Professor

**Archana H Deshpande** Professor and Head

**Cite this article:** Gargade CB, Deshpande AH. Leiomyoadenomatoid tumour of testicular tunica – A rare entity. *Indian J Pathol Oncol* 2020;7(2):343-346.