



Case Report

Bilateral primary angiosarcoma of breast in young patient: A case report with review of literature

Rashmi Yadav^{1,*}, Ritu Mehta², Rajeev Kumar Yadav¹

¹Dept. of Pathology, Central Hospital SEC Rly, Bilaspur, Chhattisgarh, India

²Dept. of Pathology, INHS Asvin, Mumbai, Maharashtra, India



ARTICLE INFO

Article history:

Received 13-08-2019

Accepted 20-11-2019

Available online 25-05-2020

Keywords:

Angiosarcoma

Breast

Sarcoma

ABSTRACT

Angiosarcomas are rare tumors arising from endothelial lining of vascular channels. The first case of breast angiosarcoma was presented in 1907 by Borrmann and the first case of secondary angiosarcoma described in 1987 by Body. There are 2 main types. Haemangiosarcomas in blood vessels and lymphangiosarcomas in lymphatic vessel walls.

All angiosarcomas tend to be aggressive and are mostly multicentric. These tumors have very high local recurrence rate and metastasis because of their intrinsic biologic properties. They are often misdiagnosed leading to a poor prognosis and a high mortality rate. We present a case of a 21-year-old female presented with an ulcerated right breast lesion which was diagnosed as primary angiosarcoma of breast with metastasis to left breast after 4 years.

© 2020 Published by Innovative Publication. This is an open access article under the CC BY-NC-ND license (<https://creativecommons.org/licenses/by/4.0/>)

1. Introduction

Angiosarcomas are rare tumors arising from endothelial lining of vascular channels. The first case of breast angiosarcoma was presented in 1907 by Borrmann and the first case of secondary angiosarcoma described in 1987 by Body. There are 2 main types, haemangiosarcomas in blood vessels and lymphangiosarcomas in lymphatic vessel walls.

All angiosarcomas are aggressive and mostly multicentric. These tumors have very high local recurrence rate and metastasis and are often misdiagnosed. We present a case of a 21-year-old female presented with an ulcerated right breast lesion which was diagnosed as primary angiosarcoma of breast with metastasis to left breast after 4 years.

2. Case Report

A 21 year old female presented with bluish red discoloration of right breast for two months with compressible swelling in inferior quadrant of size 6x7 cm. This swelling had multiple ulcerations over skin surface with focal active bleeding.

Nipple areola complex was free of tumor.

USG breast revealed a hypoechoic lesion in inferior quadrant in 5 O'clock position suggestive of neoplastic etiology likely inflammatory carcinoma. FNAC attempted twice revealed hypo cellular smear with plenty of blood cells and few single atypical cells.

Simple mastectomy with Latissimus flap reconstruction was performed, and subsequent histopathology was reported as High grade angiosarcoma. The patient received three cycles of chemotherapy comprising of Gemcitabine and docetaxel. After which she was lost to follow up.

After four years patient presented with lump in opposite (Left breast) with overlying skin changes in the form of discoloration and ulceration. CT scan was suggestive of a new lesion in the Left breast, likely a metastasis from the Right breast Carcinoma. MRI showed T1 and T2 heterogenous mass having internal fatty component in upper quadrant middle third measuring 5.3x6.7x6.9 cm. The irregular mass with heterogenous pattern of enhancement shows restriction on diffusion weighted sequences. No evidence of any distant metastasis found.

* Corresponding author.

E-mail address: drrashmidv@gmail.com (R. Yadav).

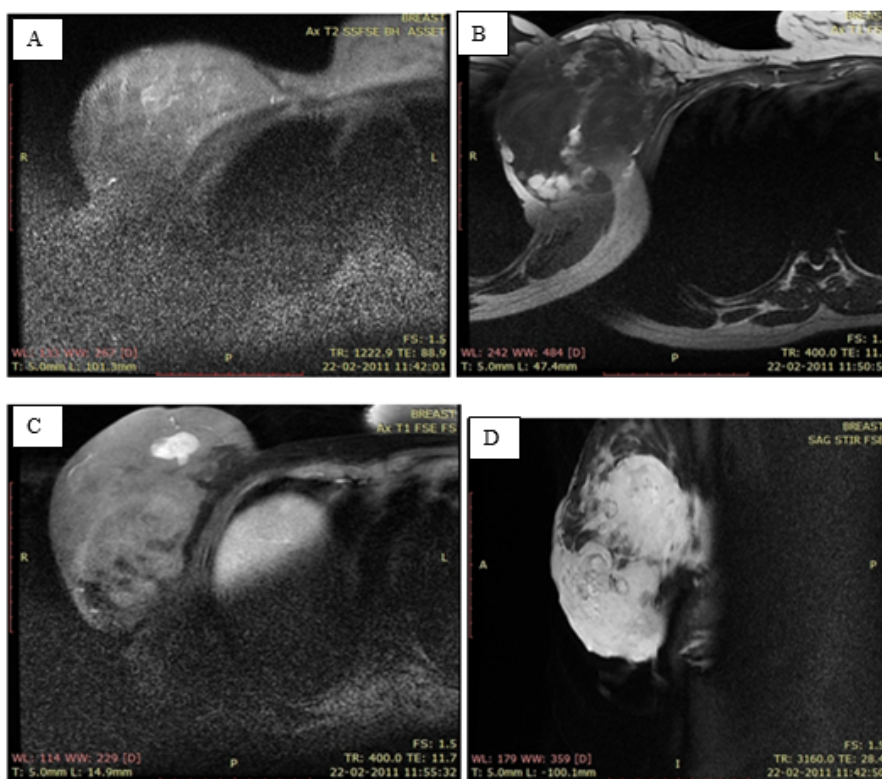


Fig. 1: a): High signal Intensity (SI) on T2WI; b): Low signal intensity (SI) on T1WI; c): Post contrast image, the mass exhibited rapidly intense enhancement; d): STIR (short TI recovery) to suppress signal from fat

A ultrasound guided core biopsy was performed, the histopathology report of which revealed an angiosarcoma grade III which was similar in morphology to the right breast lesion initially resected. Left simple mastectomy with level I lymph node dissection performed. On gross tumor was 8x7.5x5 cm irregular indurated variegated infiltrating mass with areas of hemorrhage. Nipple areola complex was involved. Histopathological findings revealed Infiltrating neoplasm composed of interanastomosing angiectatic channels lined by single layer of endothelial cells dissecting between breast parenchyma (Figure 2). These blood vessels are intermingled with solid areas made up of epithelioid cells with oval vesicular nuclei and prominent nucleoli. About 3-4 mitosis seen per high power field. Atypical mitosis also present which were consistent with Angiosarcoma grade III. Total of seven lymph node dissected out of which all were negative for tumor metastasis.

3. Discussion

Less than one percent of breast malignancies are sarcomas. Most common type of non phylloid sarcomas occurring in the breast is angiosarcoma, fibrosarcoma, liposarcoma, leiomyosarcoma and malignant fibrous histiocytoma.¹

Angiosarcomas can occur in various organs like skin, liver, heart, and deep tissue like deep subcutis, of lower extremities, followed by the arms, the trunk and the head & neck. Skeletal muscle, retroperitoneum, mesentery, and mediastinum are also involved,² but less than 10% of all angiosarcomas originate in breast and less than 0.05% of all breast tumors are angiosarcomas.^{3,4}

This tumor specifically occurs in young women.⁴ Very few studies done in India, majority of them depicts median age of patients of primary carcinoma of breast as 24.5 years.⁵ However few isolated case reports also publish breast angiosarcomas in post menopausal females. Only five cases have been reported in male breast. Angiosarcoma usually presents as a palpable mass, or with a bluish discoloration or bruising of the overlying skin. There are no known risk factors for developing primary angiosarcoma.

Prognosis is often dismal due high rates of recurrence and metastasis. Angiosarcoma of the breast metastasizes hematogenously, rather than lymphogenously. Metastases often occur in lungs, skin, subcutaneous tissue, bone, liver, spleen, adrenal gland, psoas muscles, brain and ovaries. Bilateral primary angiosarcoma can occur and is often associated with pregnancy. Carcinogens such as vinyl chloride, arsenic and thorium dioxide are also associated with angiosarcomas.

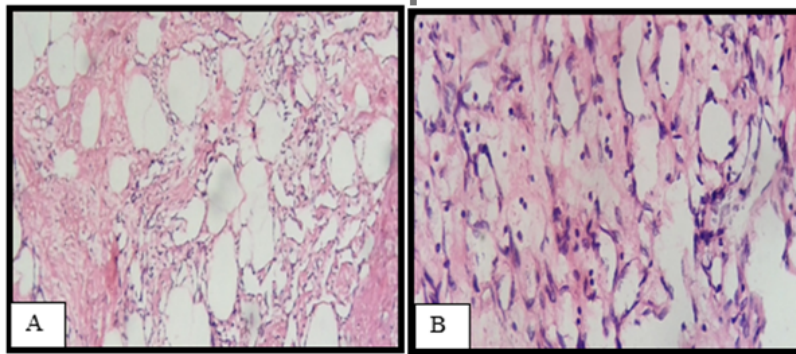


Fig. 2: a): Low power view showing anastomosing vessels; **b):** High power view

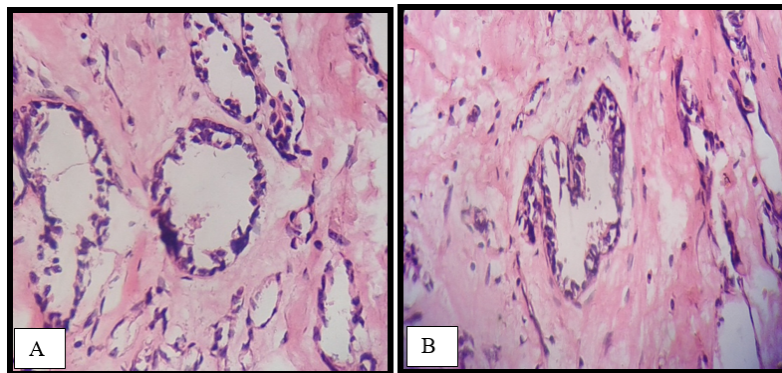


Fig. 3: a): Vessels filled with RBC's; **b):** Lumen of the vascular channel is dilated showing tufting at palaces

There are two broad types of angiosarcoma in breast, primary angiosarcoma and secondary angiosarcoma.

1. Primary angiosarcomas of the breast occur in young women usually presenting as palpable masses.
2. Secondary angiosarcomas frequently occur after BCS (Breast conservation therapy) with radiation therapy; the average latency period is 5–6 years.⁶

As compared with latency of other radiation-associated sarcomas, the breast radiation-associated angiosarcoma has relatively short latency.⁷

In considering the diagnosis of secondary angiosarcoma Cahan et al suggested the following criteria:-

1. The sarcoma must arise in previously irradiated area.
2. Sufficient latent period (in years) must exist between the time of irradiation and development of the sarcoma
3. Diagnosis must be confirmed histologically.

Comparison of primary and secondary angiosarcomas-

Secondary angiosarcoma shows high local recurrence rate while primary tends to metastasize. Median age of presentation of secondary angiosarcomas is 56.8 years while that of primary is 24.5 years. Secondary angiosarcomas show high levels of amplifications of MYC as well as FLT4 (VEGFR3).⁸

Histological grades of Angiosarcomas according to WHO-

Grade I – consist of interanastomosing vascular channels dissecting through the inter lobular stroma. Malignant blood vessels are lined by prominent and hyperchromatic nuclei.

Grade II- 75% of bulk of tumor is formed by well differentiated (grade I) pattern. In addition to that solid cellular foci are scattered throughout.

Grade III- Intercommunicating vascular channels are intermingled with solid endothelial and spindled area often showing areas of necrosis and high mitotic count.

Though previous studies showed some relation between histological grades and prognosis, larger series however confirmed there is no correlation between histologic grade and patient outcome.^{9,10}

Low-grade tumors should be differentiated from benign vascular proliferations, such as hemangiomas, atypical vascular lesions, and nonvascular stromal lesions, such as pseudoangiomatous stromal hyperplasia. Masson tumor (benign papillary endothelial hyperplasia) may be difficult to distinguish.

High grade angiosarcomas should be differentiated from other malignancies involving the breast like metaplastic and spindle cell carcinomas along with acantholytic variants of squamous cell carcinomas.

Most common differentials are Hemangiomas which in contrast to angiosarcomas are well circumscribed usually smaller than 2 cm, and less commonly involve the skin. They not invade or destroy lobules however they may have fibrous septa and calcifications. Atypical vascular lesions (AVLs) forms another differential, which can be differentiated from angiosarcoma on histopathology itself. As per Fineberg and Rosen's histologic criteria of assessment in their study, AVLs typically lacks stratification of endothelial cells, prominent nucleoli, mitoses, and hemorrhage in comparison to angiosarcomas. In AVL, there will not be destruction of a nxea or extension into the subcutaneous tissue however angiosarcomas will usually have this feature.

This tumor also needs to be differentiated from tumors like fibrosarcoma, stromal sarcoma, squamous cell carcinoma with sarcomatoid features, etc. This can be done by immunostaining for factor VIII antigen, CD 31, CD34, desmin, and vimentin.

Treatment of angiosarcoma is complete surgical excision with tumor free margins. Adjuvant chemotherapy includes doxorubicin for poorly differentiated angiosarcoma of the breast results in relapse-free patient as compared to patients not receiving adjuvant chemotherapy.¹¹ Gemcitabine also known to have activity in angiosarcoma however it is not well-established. A combination of gemcitabine and docetaxel might be superior as held across the pretreatment assignment histological stratification in a randomized phase II study.¹²

Tumor size is usually more than 4 cm. In a series at Mayo Clinic tumor size was more important as a prognostic factor than tumor grade.¹³ Radiotherapy is reserved after surgical excision for tumor larger than 5 cm, with margins positive, or if the skin or regional nodes are involved.

4. Conclusion

Primary angiosarcoma of breast is rare and aggressive tumor present in young age with significant morbidity and mortality. Well differentiated angiosarcoma may be difficult to differentiate from other vascular lesions. Primary angiosarcoma spreads hematogenously very rapidly. Involvement of other breast is not uncommon and adds significant morbidity.

5. Source of Funding

None.

6. Conflict of Interest

None.

References

1. McGowan TS, Cummings BJ, O'Sullivan B, Catton CN, Miller N, Panzarella T. An analysis of 78 breast sarcoma patients without distant metastases at presentation. *Int J Radiat Oncol Biol Phys.* 2000;46(2):383–90.
2. Meis-Kindblom JM, Kindblom LG. Angiosarcoma of soft tissue: a study of 80 cases. *Am J Surg Pathol.* 1998;22:683–97.
3. Bhosale SJ, Kshirsagar AY, Patil MV, Wader JV, Nangare N, Patil PP. Primary angiosarcoma of breast: A case report. *Int J Surg Case Rep.* 2013;4:362–4.
4. Wang XY, Jakowski J, Tawfik OW, Thomas PA, Fan F. Angiosarcoma of the breast: a clinicopathologic analysis of cases from the last 10 years. *Ann Diagnostic Pathol.* 2009;13:147–50.
5. Shet T, Malaviya A, Nadkarni M, Kakade A, Parmar V, Badwe R, et al. Primary angiosarcoma of the breast: Observations in Asian Indian women. *J Surg Oncol.* 2006;94(5):368–74.
6. Brenn T, Fletcher CDM. Postradiation vascular proliferations: an increasing problem. *Histopathol.* 2006;48(1):106–14.
7. Shah S, Rosa M. Radiation-Associated Angiosarcoma of the Breast: Clinical and Pathologic Features. *Archives of Pathology and Laboratory Medicine;* 2016. Available from: <https://dx.doi.org/10.5858/arpa.2014-0581-rs>. doi:10.5858/arpa.2014-0581-rs.
8. Guo T, Zhang L, Chang NE, Singer S, Maki RG, Antonescu CR. Consistent MYC and FLT4 gene amplification in radiation-induced angiosarcoma but not in other radiation-associated atypical vascular lesions. *Genes, Chromosomes Cancer.* 2011;50:25–33.
9. Fineberg S, Rosen PP. Cutaneous Angiosarcoma and Atypical Vascular Lesions of the Skin and Breast After Radiation Therapy for Breast Carcinoma. *Am J Clin Pathol.* 1994;102:757–63.
10. Nascimento AF, Raut CP, Fletcher CDM. Primary angiosarcoma of the breast. *Am J Surg Pathol.* 2008;32:1896–1904.
11. Antman KH, Corson J, Greenberger J, Wilson R. Multimodality therapy in the management of angiosarcoma of the breast. *Cancer.* 1982;50:2000–3.
12. Maki RG, Wathen JK, Patel SR, Priebe DA, Okuno SH, Samuels B, et al. Randomized Phase II Study of Gemcitabine and Docetaxel Compared With Gemcitabine Alone in Patients With Metastatic Soft Tissue Sarcomas: Results of Sarcoma Alliance for Research Through Collaboration Study 002. *J Clin Oncol.* 2007;25(19):2755–63.
13. Adem C, Reynolds C, Ingle JN, Nascimento AG. Primary breast sarcoma: clinicopathologic series from the Mayo Clinic and review of the literature. *Br J Cancer.* 2004;91(2):237–41.

Author biography

Rashmi Yadav Consultant Pathologist

Ritu Mehta Assistant Professor

Rajeev Kumar Yadav Consultant Pediatrician

Cite this article: Yadav R, Mehta R, Yadav RK. Bilateral primary angiosarcoma of breast in young patient: A case report with review of literature. *Indian J Pathol Oncol* 2020;7(2):323-326.