



## Original Research Article

## Thyroid lesions - cytological evaluation by bethesda system

Shete Smita S<sup>1</sup>, Kanchan Tamane<sup>1</sup>, Pandit G A<sup>1</sup>, Manali Patil<sup>1,\*</sup>, Prakash Kharat<sup>1</sup>, Manasee Bendre<sup>1</sup><sup>1</sup>Dept. of Pathology, Dr. V. M. Government Medical College, Solapur, Maharashtra, India

## ARTICLE INFO

## Article history:

Received 14-02-2020

Accepted 19-05-2020

Available online 19-11-2020

## Keywords:

Bethesda system

Fine needle aspiration cytology

Thyroid lesions

## ABSTRACT

**Introduction:** Fine needle aspiration cytology (FNAC) of thyroid is first line diagnostic test for evaluating a thyroid nodule.

FNA evaluation by The Bethesda System of Reporting Thyroid Cytopathology (TBSRTC) of thyroid nodules reduces load of unnecessary surgeries for benign lesions and guides for timely surgical intervention when there is significant risk of malignancy.

**Aims and Objectives:** To categorise Fine Needle Aspiration Cytology as per the Bethesda system.**Materials and Methods:** Prospective study conducted in Department of Pathology at tertiary health care center, Solapur including 165 patients from department of Surgery and E.N.T. during period of 2 years.

Cases of palpable swellings of thyroid for FNAC and surgical thyroid specimens for histopathology were included.

**Results:** Females 150 (90.90%) outnumbered males 15 (9.10%). 165 cases were distributed in following categories as per TBSRTC:- Category I (Non-diagnostic or unsatisfactory)- 4 cases (2.41%); Category II (Benign)-146 cases (88.5%); Category III (AUS/FLUS)-3 cases (1.82%); Category IV (FN/SFN)-7 cases (4.24%); Category V (SM)-2 cases (1.21%); Category VI (malignant)-3 cases (1.82%).**Conclusion:** The TBSRTC helps to classify thyroid lesions under specific categories thus providing an implied risk for malignancy and guidance towards surgical management.© This is an open access article distributed under the terms of the Creative Commons Attribution License (<https://creativecommons.org/licenses/by/4.0/>) which permits unrestricted use, distribution, and reproduction in any medium, provided the original author and source are credited.

## 1. Introduction

Thyroid disorders are very common cause of endocrinological disturbances.<sup>1</sup> In our country many people are at risk for developing iodine deficiency disorders because goitrogens like cauliflower, cabbage, mustard seeds, radish and turnip are an integral part of diet so it is imperative to evaluate a diagnostic method whereby such disorders can be easily diagnosed.<sup>2</sup>

Fine needle aspiration (FNA) is an established test for the evaluation of thyroid nodule.<sup>3</sup> FNA of thyroid is a rapid, minimally invasive and first line procedure in the evaluation of thyroid nodules.<sup>4-6</sup>

However, despite its widespread use FNA suffered from a reporting confusion due to multiplicity of category names, descriptive reports without categories and variable surgical pathology terminology.<sup>7</sup> The framework for The Bethesda System for Reporting Thyroid Cytopathology (TBSRTC) was formed by thyroid FNA of the science conference 2007.<sup>8,9</sup>

TBSRTC provides a 6-tiered diagnostic framework that uses defined criteria to promote uniformity in the reporting of thyroid aspirates. One of the major advantages of this scheme is that the individual diagnostic categories are associated with defined risks of malignancy, allowing for standardized management algorithms for each diagnosis.<sup>10</sup>

\* Corresponding author.

E-mail address: [manaliapatil555@gmail.com](mailto:manaliapatil555@gmail.com) (M. Patil).

## 2. Aim and Objectives

This study was undertaken to evaluate the usefulness of The Bethesda System for Reporting thyroid Cytopathology in Thyroid FNA.

## 3. Materials and Methods

Prospective study was conducted in Department of Pathology at tertiary health care center, Solapur for the period of 2 years which included 165 patients presenting with palpable thyroid swelling from Department of Surgery and E.N.T.

Under all aseptic precautions FNAC was done and smeared slides fixed and stained with H & E. Reporting of FNA was done by using TBSRTC. Surgical thyroid specimens received were processed routinely and prepared slides were stained with H & E. The permission from ethical committee has been taken.

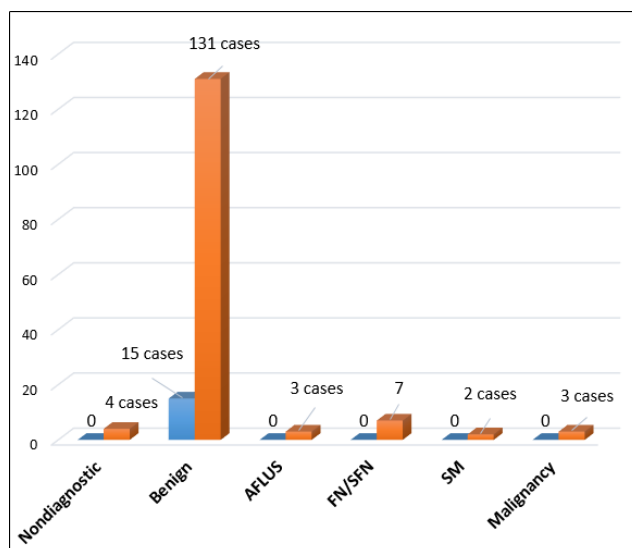
## 4. Observations and Results

Out of 165 cases, 146 benign cases of category II were advised clinical follow up out of which 51 cases were subjected to surgical lobectomy. All the three cases from category III were available for histopathological follow up. Out of 7 cases of category IV, 4 cases underwent surgical lobectomy. Two cases of category V were not available for follow up. All 3 cases of category VI were subjected to surgical management and available for histopathological follow up. (Table 1)

**Table 1:** Distribution of lesions in the Bethesda categories as per our study (n=160)

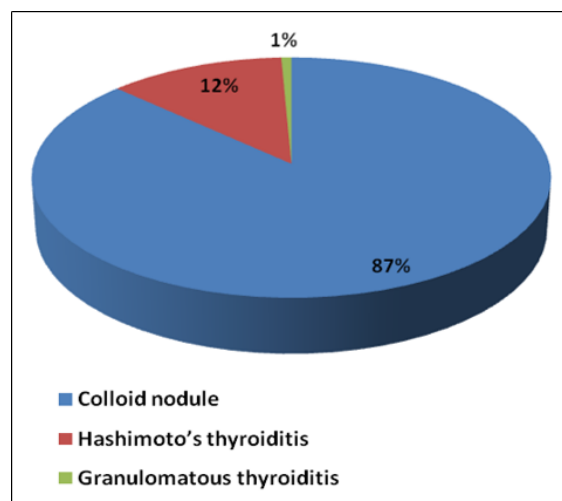
Category	No. of cases	Percentage (%)
I) Non diagnostic	4	2.41
II) Benign	146	88.5
III) AUS/FLUS	3	1.82
IV) SFN/FN	7	4.24
Follicular neoplasm (FN)	3	1.82
FN - Hurthle cell type	4	2.42
V) SM	2	1.21
Suspicious for papillary Carcinoma	2	1.21
VI) Malignant	3	1.82
Papillary thyroid carcinoma	2	1.21
Medullary thyroid carcinoma	1	0.60

Maximum lesions were found in female than males in the proportion of 10:1. Graph 1 indicates the sex wise incidence of thyroid lesions.



Graph 1: Sex wise incidence of thyroid lesions (n = 165)

In the present study, colloid nodule comprised of 127cases (87%) which was the predominant group in the benign category, followed by 18 cases (12.3%) of Hashimoto's thyroiditis and least being Granulomatous thyroiditis with 1 case (0.7%). (Graph 2)



Graph 2: Distribution of Benign lesions (N = 146)

## 5. Discussion

During the period of 2 years, a total number of 1768 FNACs were done, out of which 165 were belonging to thyroid gland. So the thyroid lesions in our study constituted 9.33% of all FNACs done during the study period.

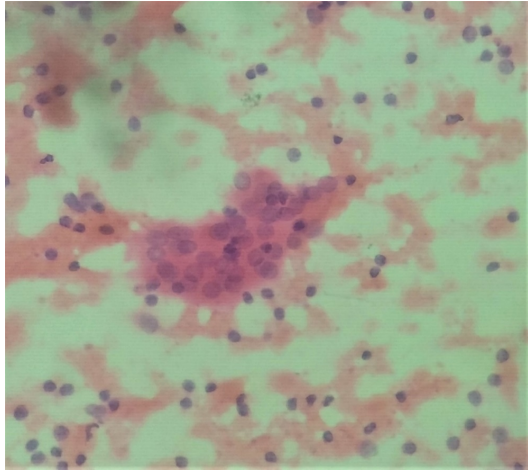
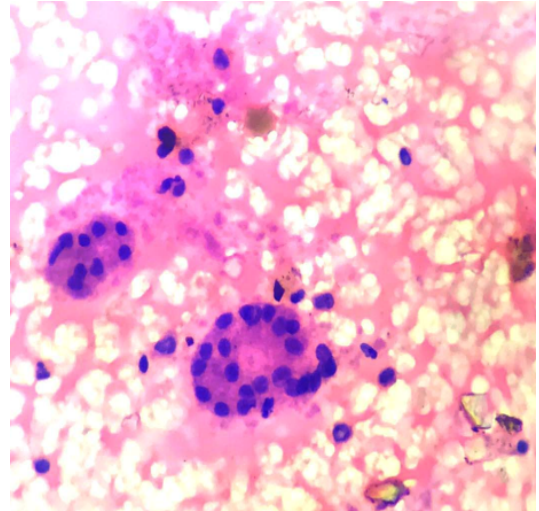
In the present study, cytodagnostic evaluation of thyroid lesions were done and classified according to The Bethesda System for Reporting Thyroid Cytopathology (TBSRTC).

**Table 2:** Age wise incidence of various categories according to Bethesda system (n=165)

Age (years)	Category						Total	Percentage (%)
	I	II	III	IV	V	VI		
0-10	-	3	-	-	-	-	3	1.82
11-20	-	7	-	-	1	-	8	4.85
21-30	-	33	-	-	-	1	34	20.61
31-40	4	45	1	1	1	1	53	32.12
41-50	-	30	2	1	-	-	33	20
51-60	-	14	-	1	-	1	16	9.7
61-70	-	7	-	2	-	-	9	5.45
>70	-	7	-	2	-	-	9	5.45
<b>Total and percentage</b>	4 (2.41)	146 (88.5%)	3 (1.82%)	7 (4.24%)	2 (1.21%)	3 (1.82%)	165	100

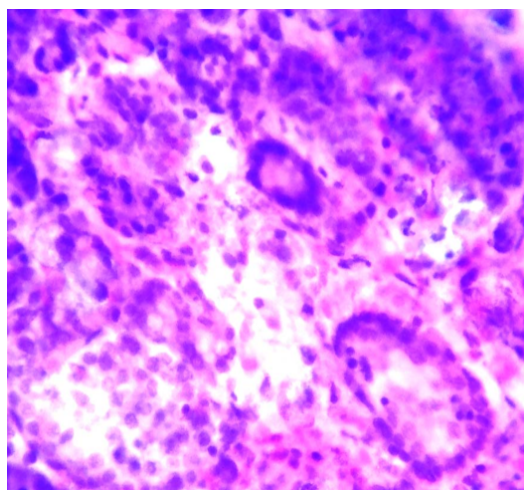
**Table 3:** Comparison of FNAC diagnosis based on Bethesda classification

Diagnostic category	Yassa L et al (2007)	Yang J et al (2007)	Nayar R and Ivanovic M et al (2009)	Jo V Y et al (2010)	Mufti and Molah (2012)	Mondal S K et al (2013)	Mehra P and Verma AK (2015)	Present study (2017)
Nondiagnostic	7	10.4	5	18.6	11.6	1.2	7.2	2.41
Benign	66	64.6	64	59	77.6	87.5	80	88.5
AUS/AFLUS	4	3.2	18	3.4	0.4	1	4.8	1.82
Follicular neoplasm/ SFN	9	11.6	6	9.7	4	4.2	2.2	4.24
Suspicious for malignancy	9	2.6	2	2.3	2.4	1.4	3.6	1.21
malignant	5	7.6	5	7	3.6	4.7	2.2	1.82

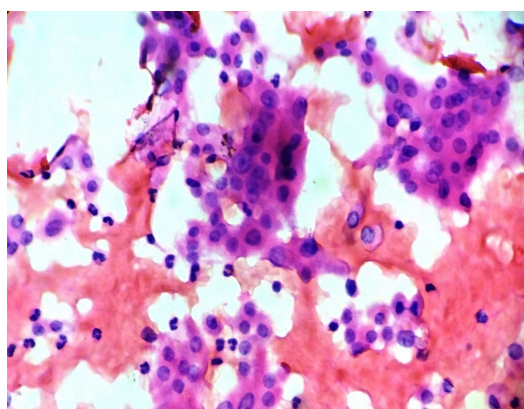
**Fig. 1:** Photomicrograph of category II Hashimoto's thyroiditis showing Hurthle cell change in many follicular cells on a background of lymphocytes. (H&E X 100)**Fig. 2:** Photomicrograph of category III - follicular lesion of undetermined significance showing sparsely cellular aspirate with predominance of micro-follicles and scant colloid. (H&E X 100)

Age distribution of the present study was comparable to Handa et al.<sup>11</sup> and Parikh U. R. et al.<sup>12</sup> The mean age in the present study was 39.72 years which was comparable with Handa et al.,<sup>11</sup> Gupta et al.,<sup>13</sup> Rangaswamy et al.,<sup>14</sup> Parikh U. R. et al.,<sup>12</sup> Vinay Kumar R et al.<sup>15</sup> and Ritica Chaudhary et al.<sup>16</sup>

Female to male ratio in the present study was 10:1 and was comparable with studies of Renuka I V et al.,<sup>17</sup> Sunita Bamanikar et al.<sup>18</sup> and Silvermann JF et al.<sup>19</sup> which had female to male ratio 9:1, 8.6:1 and 10.8:1 respectively.



**Fig. 3:** Photomicrograph of category IV – suspicious for follicular neoplasm showing cellular aspirate with micro- and macro-follicles. (H&E X 100)



**Fig. 4:** Photomicrograph of Category IV suspicious for follicular neoplasm- Hurthle cell type (H&E X 100)

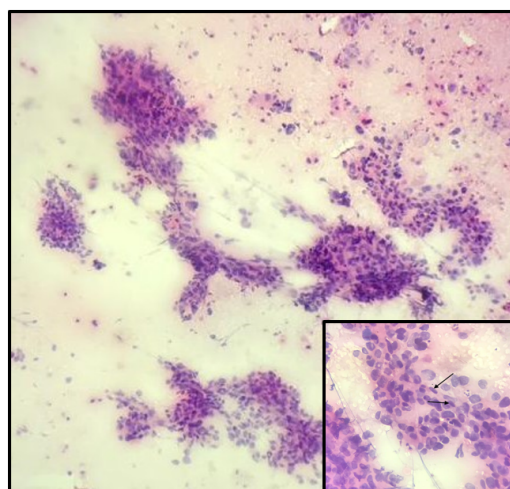
For a thyroid FNA specimen to be satisfactory for evaluation, at least 6 groups of benign follicular cells are required, each group composed of at least 10 cells. There are several exceptions like any specimen that contains abundant colloid is considered adequate, even if 6 groups of follicular cells are not identified.

The benign category had 146 cases (88.5%) and in this cases unnecessary surgery can be avoided.

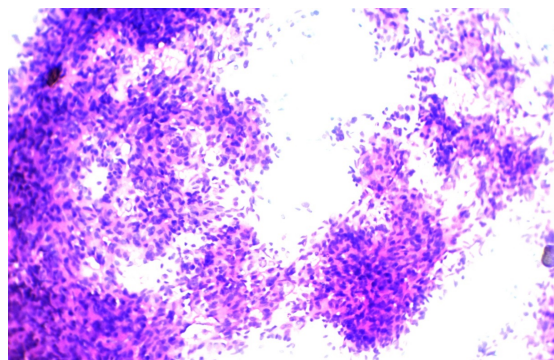
Some thyroid FNAs could not be clearly categorized benign or malignant and reported as atypia of undetermined significance (AUS). TBSRTC suggests that this category should not be used indigenously.

Follicular neoplasm (IV category) was subjected for hemithyroidectomy and risk for malignancy is about 15-30% of all cases.

Both cases of Suspicious of malignancy (category V) were given as suspicious of papillary carcinoma because of very few follicular cells showing presence of internuclear



**Fig. 5:** Photomicrograph of category V – suspicious for papillary neoplasm showing hyper cellular smears of follicular cells arranged in papillary pattern. (H&E X 40) Inset shows nuclear grooves as well as nuclear inclusions (H&E X 400)



**Fig. 6:** Photomicrograph of category VI – medullary thyroid carcinoma showing hyper cellular smear having round to oval cells with pleomorphic nuclei arranged in syncytial pattern (arrow). (H&E X 100)

cytoplasmic inclusion. (Figure 5)

In category VI, out of 3 cases, on histopathology 2 were reported as papillary carcinoma of thyroid in which follicular cells were arranged in papillary pattern with cell having nuclear features like grooves and inclusions. Remaining one case was categorized as medullary carcinoma of thyroid as it showed moderate cellularity polygonal to round cells having round nuclei and coarse chromatin. (Figure 6)

## 6. Conclusions

The primary objective of FNAC of the thyroid is to differentiate those patients who require surgery for a neoplastic disorder from those who have a functional or inflammatory abnormality and who can be followed

clinically or treated medically.

The introduction of TSBRTC has brought about standardisation in the reporting of thyroid FNAC.

The TSBRTC helps to classify thyroid lesions under specific categories thus providing an implied risk for malignancy and guidance towards surgical management which also allows easy and reliable sharing of data between different laboratories. The clinicians are also benefitted because of the management plan it suggests. TBSRTC bridges the gap between clinician & cytopathologist. TBSRTC is a universal terminology & its use should be encouraged.

## 7. Source of Funding

None.

## 8. Conflict of Interest

There is no conflict of interest regarding the publication of this article

## References

1. Qureshi R, Usmani MH, Singh UR, Kol PC, Valame S. FNAC in the diagnosis of thyroid nodules. *Indian J Basic Appl Med Res.* 2015;4(2):286-91.
2. Chandra AK, Mukhopadhyay, Lahari D, Tripathy S. Goitrogenic content of Indian cyanogenic plant foods & their in-vitro anti-thyroidal activity. *Indian J Med Res.* 2004;119(5):180-5.
3. Renshaw AA. Accuracy of Thyroid Fine-Needle Aspiration Using Receiver Operator Characteristic Curves. *Am J Clin Pathol.* 2001;116(4):477-82.
4. Mateša N, Tabain I, Dabelia N, Petric V, Kusia Z. Diagnostic Relevance of Fine Needle Aspiration Cytology for Follicular Lesions of the Thyroid: Retrospective Study. *Croat med J.* 2002;43(5):606-9.
5. Hegazy RA, Hegazy AA. FNAC and Cell-block Study of Thyroid Lesions. *Univ J Med Sci.* 2013;1(1):1-8.
6. Mufti ST, Molah R. The Bethesda System for Reporting Thyroid Cytopathology : A Five-Year Retrospective Review of One Center Experience. *Int J Health Sci Qassim Univ.* 2012;6(2):131-42.
7. Layfield LJ, Cibas ES, Baloch Z. Thyroid fine needle aspiration cytology: a review of the National Cancer Institute state of the science symposium. *Cytopathol.* 2010;21(2):75-85.
8. Hegedüs L. The Thyroid Nodule. *N Engl J Med.* 2004;351(17):1764-71.
9. Baloch ZW, Alexander EK, Gharib H, Raab SS. Overview of Diagnostic Terminology and Reporting. In: Ali SZ, Cibas ES, editors. *The Bethesda System for Reporting Thyroid Cytopathology.* vol. 2010. New York, NY: Springer;. p. 1-4.
10. Laan PAV, Marqusee E, Krane JF. Features associated with locoregional spread of papillary carcinoma correlate with diagnostic category in the Bethesda System for reporting thyroid cytopathology. *Cancer Cytopathol.* 2012;120(4):245-53.
11. Garg S, Mohan H, Nagarkar N, Handa U. Role of fine needle aspiration cytology in diagnosis and -management of thyroid lesions: A study on 434 patients. *J Cytol.* 2008;25(1):13-7.
12. Parikh UR, Goswami HM, Shah AM, Mehta NP, Gonsai RN. Fine needle aspiration cytology (FNAC) study of thyroid lesions-study of 240 cases. *GMJ.* 2012;67(2):25-8.
13. Gupta M, Gupta S, Gupta VB. Correlation of Fine Needle Aspiration Cytology with Histopathology in the Diagnosis of Solitary Thyroid Nodule. *J Thyroid Res.* 2010;2010:1-5.
14. Rangaswamy M, Narendra KL, Patel S, Gururajprasad C, Manjunath GV. Insight to neoplastic thyroid lesions by fine needle aspiration cytology. *J Cytol.* 2013;30(1):23-6.
15. Kumar V, Batra R, Parames N, Kariappa T. A Study of Fine Needle Aspiration Cytology of Thyroid Lesions With Histopathological Correlation. *IJCMAAS.* 2014;4(2):64-71.
16. Chaudhary R, Ahmed Z, Umaru N. A Correlative Study of FNAC Thyroid with Thyroid Hormone Profile. *J Evol Med Dent Sci.* 2014;3(6):1474-80.
17. Renuka IV, Bala GS, Aparna C, Kumari R, Sumalatha K. The Bethesda System for Reporting Thyroid Cytopathology: Interpretation and Guidelines in Surgical Treatment. *Indian J Otolaryngol Head Neck Surg.* 2012;64(4):305-11.
18. Bamanikar S, Bamanikar A, Jadhav S, Jadhav P, Kumar H, Soraisham P. Cyto-histology and clinical correlation of thyroid gland lesions: A 3 year study in a tertiary hospital. *Clin Cancer Investig J.* 2014;3(3):208-12.
19. Silverman JF, West RL, Larkin EW, Park HK, Finley JL, Swanson MS, et al. The role of fine-needle aspiration biopsy in the rapid diagnosis and management of thyroid neoplasm. *Cancer.* 1986;57(6):1164-70.

## Author biography

**Shete Smita S**, Associate Professor

**Kanchan Tamane**, Resident

**Pandit G A**, Professor and Head

**Manali Patil**, Resident

**Prakash Kharat**, Resident

**Manasee Bendre**, Resident

**Cite this article:** Smita S S, Tamane K, Pandit G A, Patil M, Kharat P, Bendre M. Thyroid lesions - cytological evaluation by bethesda system. *Indian J Pathol Oncol* 2020;7(4):527-531.