



Original Research Article

Black box within the beauty

Minnu Sibby¹, Bhavani Krishnamurthy^{1,*}, Kathirvelu Shanmugasamy¹, Sowmya Srinivasan¹

¹Dept. of Pathology, Mahatma Gandhi Medical College and Research Institute- Sri Balaji Vidyapeeth (Deemed-to-be University), Pillaiyarkuppam, Pondicherry, India



ARTICLE INFO

Article history:

Received 14-02-2020

Accepted 28-02-2020

Available online 19-08-2020

Keywords:

Histopathology

Nasal biopsies

ABSTRACT

Introduction: Occupying a prime location in face, nasal cavity is the main route of entry of air into the body. Nasal lesions can have varied presentations ranging from simple inflammatory to even malignant tumours. The aim of this study is to find the incidence of nasal lesions along with their histopathological patterns and correlation with age-gender distribution and site of the lesion.

Materials and Methods: The present study was done in the department of Pathology, MGMCRI, for a period of six months from January 2019 to June 2019 and included 58 cases of nasal biopsies. Tissue was processed and studied as per standard operating procedures.

Results: Out of the 58 cases studied, 55.17% were inflammatory of which 28.13% were fungal infections. There were 37.93% benign lesions and 6.7% malignancies. Majority of the lesions were seen in the age group of 20-39 years, with male preponderance. The most common location involved was nasal cavity with allergic inflammatory polyp being the most common lesion.

Conclusion: Although most of the nasal biopsies sent are inflammatory, secondary to infection or allergy, variety of benign and malignant lesions of nose are also common. Even though they can be suspected clinically confirmation can be done only by histopathological examination. Hence histopathology digs out the 'black box within the beauty' and remains the gold standard for the diagnosis of nasal lesions.

© 2020 Published by Innovative Publication. This is an open access article under the CC BY-NC license (<https://creativecommons.org/licenses/by-nc/4.0/>)

1. Introduction

Occupying a prime location in face, nasal cavity is main route of entry of air into the body.¹ It purifies the outside air and makes it suitable for breathing. Nasal cavity begins as the nostrils and is divided into two halves by the nasal septum. Paranasal sinuses are connected to these cavities via the ostia. It gets exposed to various pathogens and other chemical and mechanical factors of the outside environment.² Patients can present with symptoms varying from mild nasal discharge or nasal blockage to even serious massive epistaxis.³ Nasal lesions can have varied presentations ranging from simple inflammatory to even malignant tumours.⁴ Benign lesions are common whereas malignant tumours are rare and account for 0.2-

0.8% of total aerodigestive tract malignancies.⁵ It is important to recognize these lesions as they are different both in treatment modalities as well as in terms of economical and emotional burden given to the patient.⁶ The objectives of this study is to find the incidence of different nasal lesions in our institution and to find their histopathological patterns in context with age-gender distribution and site of the lesion. Advent of diagnostic nasal endoscopies has contributed significantly to the detection of nasal lesions. Endoscopic examination remains complementary to radiological investigation of the nasal lesions. In spite of technological advancements and a combined diagnostic strategy using nasal endoscopy and radiological examination, majority of the lesions were clinically suspected to be only benign. In addition to this, there is high chance of missing clinically insignificant

* Corresponding author.

E-mail address: minnusibby92@gmail.com (B. Krishnamurthy).

lesions through these methods. But a thorough and meticulous histopathological examination can dig out the true nature of these lesions including malignancy hidden within them. Also, various mimickers of nasal lesions are known of which fibrous dysplasia is an important one.⁷ Hence, histopathological examination of all nasal lesions remains the mainstay for definitive diagnosis.

2. Materials and Methods

This was a descriptive study conducted in the Department of Pathology, Mahatma Gandhi Medical College and Research Institute, Puducherry from January 2019 to June 2019 for a period of six months. It included 58 nasal biopsies which was received in the department during the study period. All nasal biopsies received were fixed with 10% neutral buffered formalin. Hematoxylin and eosin staining was done in all samples. Special stains like periodic acid Schiff and Gomori methanamine silver stains were done in necessary cases. Each of the cases were classified as inflammatory and neoplastic based on the histopathological findings as given in Table 1. Results obtained were tabulated and subjected to statistical analysis for correct inferences.

3. Results

Out of the 58 cases studied, majority of the lesions were seen in the age group of 20-39 years (Figure 1), with male preponderance (Figure 2). The most common location involved was nasal cavity with allergic inflammatory polyp being the most common lesion. 55.17% of the studied lesions were inflammatory of which 28.13% were fungal infections. There were 37.93% benign lesions and 6.7% malignancies.

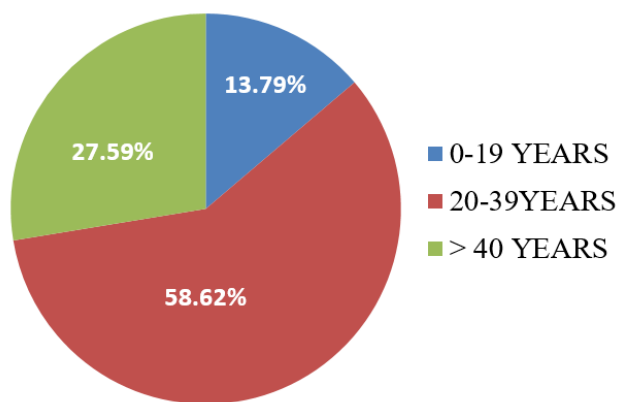


Fig. 1: Age distribution

4. Discussion

In the present study, majority of the patients were in the age group of 20-39 years which was consistent with the studies

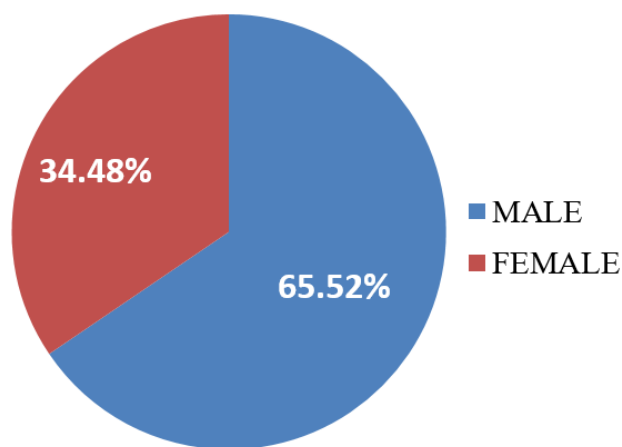


Fig. 2: Gender distribution

done by Parmar NJ et al, Vijaya V Mysoreka et al and T. Dinesh Singh et al as shown in Table 3.

Male predominance was observed in the present study similar to the findings in other studies as shown in Table 4. This may be due to the smoking habits and occupational exposure. Both these risk factors are known to cause chronic irritation of the lining of nasal mucosa which increases chances of developing lesions. Also they are known to cause squamous metaplasia which correlates with the increased incidence of malignant lesions among males in the study.

As consistent with the present study, Parmar NJ et al also showed that nasal cavity is the commonest site for nasal lesions as shown in Table 5. Also, all three cases involving the external nose turned out to be malignancies.

In the present study AIP was the commonest non-neoplastic lesion comprising 68.75% which was consistent with the observations in other studies as seen in Table 6. Surprisingly, even though most of the studies compared are done in Indian population, in this study we found that majority of the infective nasal lesions were fungal in origin. Also, these lesions were commonly seen in women. This points a light into the possibility of poor living conditions like overcrowding and low socio-economic status which predominates in the region involved by the study. Increased incidence of mucormycosis in older age group supports the possible immunocompromised states in the patients.

In this study, sinonasal papilloma was the most common benign lesion constituting 17.24% (Table 7). Among the papillomas reported, most of them belonged to the inverted type (9 cases) and only one case showed oncocytic papilloma. Approximately 5% of inverted papillomas are known to transform into sinonasal carcinomas. Malignant lesions of nose can be epithelial or mesenchymal in origin. Epithelial tumours are commoner and can arise from lining epithelium, accessory salivary glands, neuroendocrine tissue or from olfactory epithelium. Mesenchymal tumours originate from the surrounding supporting materials.⁷

Table 1: Varied spectrum of nasal lesions in histopathology

S.No.	HPE Diagnosis	Number of cases	Gender		0-19	Age 20-39	>40
			Male	Female			
I	Inflammatory lesions						
1	Allergic nasal polyp	22	15	7	2	14	6
2	Florid lymphoid hyperplasia	1	0	1	0	0	1
3	Aspergillosis	2	0	2	0	2	0
4	Mucormycosis	4	1	3	0	1	3
5	Rhinosporidiosis	3	0	3	0	3	0
II	Benign Lesions						
1	Inverted Papilloma	10	8	2	0	8	2
2	Mucocele	2	2	0	1	0	1
3	Lobular Capillary Hemanfioma	5	4	1	1	4	0
4	Neurofibroma	1	1	0	0	1	0
5	Juvenile nasopharyngeal angiofibroma	4	4	0	4	0	0
III	Malignant Lesions						
1	Malignant Small Round Cell Tumour	1	1	0	0	1	0
2	Undifferentiated Sinonasal Carcinoma	1	1	0	0	0	1
3	Basal Cell Carcinoma	1	0	1	0	0	1
4	Squamous Cell Carcinoma	1	1	0	0	0	1

Table 2

Site	No.of.cases	Percentage
External nose	3	5.17%
Nasal cavity	49	84.48%
Nasal septum	6	10.34%
Total	58	100%

Table 3: Comparison of age-wise distribution with other studies

Age in years	Present study	Parmar N J et al ⁴	Vijaya V Mysoreka et al ⁵	T. Dinesh Singh et al ⁸
0-19 years	13.79%	26%	32.4%	40%
20-39 years	58.62%	42%	35.86%	42.85%
> 40 years	27.59%	32%	31.72%	17.14%

Table 4: Comparison of gender distribution

	Male	Female	No.of cases
Present study	38	20	58
Parmar NJ et al ⁴	59	41	100
Vijaya V Mysoreka et al ⁵	85	60	145
T. Dinesh Singh et al ⁸	20	15	35

Table 5: Comparison of sites involved

Study	No.of cases	External nose	Nasal cavity	Nasal septum
Present study	58	3 (5.17%)	49(84.48%)	6(10.34%)
Parmar NJ et al ⁴	100	6(6%)	84 (84%)	2(2%)

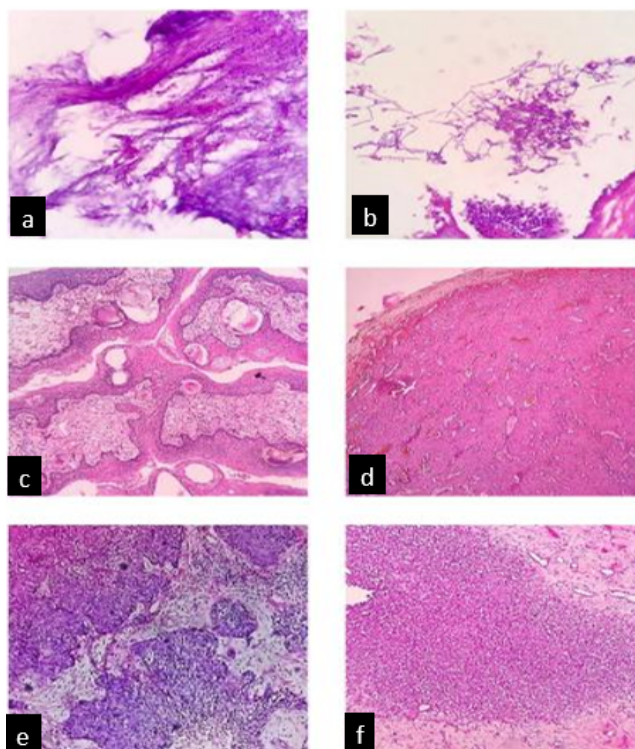


Fig. 3: Photomicrograph showing: **a):** Mucormycosis; **b):** aspergillosis; **c):** Rhinosporidiosis; **e):** Juvenile nasopharyngeal angiofibroma; **e):** Undifferentiated sinonasal carcinoma; **f):** Malignant small round cell tumour

Table 6: Comparison of types of inflammatory lesions with other studies

Study	Total no. of cases	Allergic nasal polyp	Mucormycosis	Aspergillosis	Rhinosporidiosis	Florid lymphoid hyperplasia
Present study	32	22(73.3%)	4(12.5%)	2(6.25%)	3(9.38%)	1(3.13%)
Parmar N J et al ⁴	80	74(92.5%)	3(3.75%)	-	-	1(1.25%)
Vijaya V Mysorekar et al ⁵	102	86 (84.31%)	2(1.96%)	-	-	-
T. Dinesh Singh et al ⁸	28	25 (89.29%)	-	-	-	-
Chopra H et al ⁹	84	70 (83.33%)	4(4.76%)	-	-	-

Table 7: Comparison of benign lesions with other studies

Study	Sinonasal papilloma	Mucocele	Lobular capillary hemangioma	Neurofibroma	Juvenile nasopharyngeal angiofibroma
Present study	10(17.24%)	2(3.45%)	5(8.62%)	1(1.72%)	4(6.7%)
Seema et al ¹⁰	5(17.86%)	-	14(50%)	-	5(17.86%)
Parmar NJ et al ⁴	3(25%)	-	3(25%)	-	3(25%)
Chopra H et al ⁹	4(36.36%)	-	3(27.27%)	-	3(25%)

Table 8: Comparison of malignant lesions with other studies

Study	No. of cases	Malignant small round cell tumour	Undifferentiated sinonasal carcinoma	BCC	SCC
Present study	4	1(25%)	1(25%)	1(25%)	1(25%)
Parmar NJ et al ⁴	7	-	-	3(42.85%)	2(28.57%)
Parajuli & Tuladhar's study ¹²	10	-	-	-	2(20%)

In the present study variety of malignant lesions were detected. Squamous cell carcinomas of the nasal cavity is common as shown by other studies (Table 8). There is increased incidence of these malignancies among male population. This can be related to smoking habits causing metaplasia and thereby malignant transformation of the lining mucosa. Also, there are increased chances of recurrence in smokers. Increased risk for malignancy is seen on exposure to occupational risk factors like wood and leather dust, arsenic, formaldehyde, welding fumes, nickel and chromium.¹¹ However, in this study equal incidence of malignancies like malignant small round cell tumour, undifferentiated sinonasal carcinoma, basal cell carcinoma and squamous cell carcinoma was seen. This might be because of patients failing to present to the current setting.

5. Conclusion

Majority of the nasal lesions are inflammatory in nature. However spectrum of benign and malignant lesions of nose are also reported. Since nasal cavity has a complex anatomy, it is difficult to find the true nature of a lesion in clinical and radiological evaluation. Most of the patients present only in advanced diseases too which further worsens the treatment strategies and clinical outcomes of these patients. As such in the study we found that the incidence of malignancy is low. One of the causes could be a lack of clinical suspicion of malignancy which resulted in failing to present the patient for histopathological evaluation. In spite of clinical and radiological suspicion as only an inflammatory condition, histopathological examination could bring out the true nature of the lesions which emphasizes the importance of subjecting patients for a nasal biopsy. Hence histopathology digs out the “black box within the beauty” and remains the gold standard for the diagnosis of all nasal lesions.

6. Source of Funding

None.

7. Conflict of Interest

None.

References

- Oronez NG, Rosai J. Respiratory tract. In: Rosai and Ackerman's surgical pathology. Mosby; 2004. p. 308–24.
- Jaison J, Tekwani DT. Histopathological lesions of nasal cavity, paranasal sinuses and nasopharynx. *Ann Appl Bio-sci.* 2015;2(2):40–6.
- Singh SG, Qureshi S, Jain L, Jadia S, Sharma S. Presentation of Lesions of Nose and Paranasal Sinuses at a Tertiary Care Center in Central India. *Indian J Otolaryngol Head Neck Surg.* 2018;70(2):284–9.
- Parmar NJ, Jethwani DP, Dhruva GA. Histopathological study of nasal lesions: 2 years study. *Int J Res Med Sci.* 2018;6(4):1217–23.
- Mysorekar VV, Dandekar C, Rao S, Begum N, Vishwakarma S, Khan A. Role of histopathology in the diagnosis of nasal polypoidal masses. *Ind J Applies Res.* 2015;5(2):485–7.
- Nepal A, Chettri ST, Joshi RR, Karki S. Benign Sinonasal Masses: A Clinicopathological and Radiological Profile. *Kathmandu Univ Med J.* 2014;11(1):4–8.
- Eggesbø HB. Imaging of sinonasal tumours. *Cancer Imaging.* 2012;12:136–52.
- Singh DT, Meshram K, Shreen S, Begum N, Vishwakarma S, Khan A. Role of histopathology in the diagnosis of nasal polypoidal masses. *Ind J Applies Res.* 2015;5(2):485–92.
- Chopra H, Dua K, Chopra N, Mittal V. Histopathology of Nasal Masses. *Clin Rhinol Int J.* 2010;3(2):81–5.
- Bijjaraji S, Kulkarni VG, Singh J. Histomorphological study of polypoidal lesions of nose and paranasal sinuses. *Ind J Basic App Med Res.* 2015;4(3):435–9.
- d'Errico A, Pasian S, Baratti A, Zanelli R, Alfonzo S, Gilardi L. A case-control study on occupational risk factors for sino-nasal cancer. *Occup Environ Med.* 2009;66(7):448–55.
- Parajuli S, Tuladhar A. Histomorphological spectrum of masses of the nasal cavity, paranasal sinuses and nasopharynx. *J Pathol Nepal.* 2013;3(5):351–5.

Author biography

Minnu Sibby Postgraduate Student

Bhavani Krishnamurthy Associate Professor

Kathirvelu Shanmugasamy Professor

Sowmya Srinivasan Professor & HOD

Cite this article: Sibby M, Krishnamurthy B, Shanmugasamy K, Srinivasan S. Black box within the beauty. *Indian J Pathol Oncol* 2020;7(3):399–403.