



Original Research Article

Schistocytosis in megaloblastic anemia masquerading peripheral blood picture as maha (microangiopathic hemolytic anemia) and decrease mean corpuscular volume

Sandhya Biswal¹, Ranjana Giri^{1,*}, Urmila Senapati¹

¹Dept. of Pathology, Kalinga Institute of Medical Sciences, Bhubaneswar, Odisha, India



ARTICLE INFO

Article history:

Received 15-01-2020

Accepted 11-04-2020

Available online 19-08-2020

Keywords:

MAHA

Decrease MCV

Schistocytes

Hemolysis

Megaloblastic anemia

ABSTRACT

Introduction: Severe megaloblastic anemia presenting with hemolytic anemia, thrombocytopenia and schistocytosis resemble microangiopathic hemolytic anemia. Presence of schistocytes falsely decreases the Mean corpuscular volume.

Aim: To estimate the degree of schistocytosis in megaloblastic anemia with hemolytic blood picture and its correlation with the lowering of MCV.

Materials and Methods: 60 cases of megaloblastic anemia. 30 patients of megaloblastic anemia with hemolysis (cases) and 30 patients without hemolysis (clinical control) were taken. Complete blood count, Peripheral smear examination, schistocyte count, serum bilirubin, LDH, Homocysteine was done.

Result: Mean age of clinical control group was 22 where as that of cases was 14.1 years. Mean serum homocysteine level was increased in both clinical control group and cases. In our study of 30 megaloblastic anemia patients with hemolysis (case), 29 had >1% of schistocytes in their peripheral blood picture. There is a positive correlation between percentage of schistocytes and homocysteine and a negative correlation between MCV and homocysteine. There is a statistically significant negative correlation existing between percentage of schistocytes and MCV.

Conclusion: Presence of schistocytes in peripheral blood should not be always considered as MAHA, and lowering of MCV should not be confused as microcytic hypochromic anemia. Presence of macroovalocytes and hypersegmented neutrophils can be a clue for diagnosis of megaloblastic anemia with hemolysis in such type of cases.

© 2020 Published by Innovative Publication. This is an open access article under the CC BY-NC license (<https://creativecommons.org/licenses/by-nc/4.0/>)

1. Introduction

Megaloblastic anemia is diagnosed by anemia with marked macro-ovalocytosis, hypersegmented neutrophils, progressive increase in mean corpuscular volume >125 fl and significant vitamin B12 (<200 pg/ml) and/or folate (<2 ng/ml) deficiency. Sometimes hematological consequences of vitamin B12 deficiency is very severe. Around 10% of the Megaloblastic anemia patients had life threatening conditions like symptomatic pancytopenia, hemolytic anemia, and pseudothrombotic microangiopathy.¹ In severe megaloblastic anemia, 2.5% patients presenting with

hemolytic anemia, schistocytosis and thrombocytopenia resemble microangiopathic hemolytic anemia (MAHA).¹ Till now exact mechanisms have not been demonstrated in clinical setting. In vitro study revealed that homocysteine increased the risk of hemolysis in vitamin B12 deficiency patients. But microangiopathy or fragmentation hemolysis requires intravascular hemolysis of RBC from mechanical trauma or sheer stress. So the presence of schistocytes in severe megaloblastic anemia reflects the severity of dyserythropoiesis and should not be taken as evidence of microangiopathic hemolysis. Additionally, the presence of schistocytes paradoxically lowers the MCV and gives a false impression of microcytic hypochromic anemia.

* Corresponding author.

E-mail address: drranjana.pth@gmail.com (R. Giri).

Though schistocytes are noted in peripheral blood smear of patients with pseudo-thrombotic microangiopathy in megaloblastic anemia, its association is not proven till date and correlation between schistocytosis with MCV and level of homocysteine is unknown.

Hence, the aim of our study is to estimate the degree of schistocytosis in megaloblastic anemia with hemolytic blood picture and its correlation with the lowering of mean corpuscular volume. We have also correlated with serum homocysteine level of these patients and identify the role of homocysteine in hemolysis commonly observed in these diseases.

2. Materials and Methods

A prospective study was conducted for 2 years, from September 2016 to August 2018 with approval from research and ethics committee. 60 patients were included and the study subjects were divided into two groups.

Group 1 (clinical controls) - patients with Megaloblastic anemia without hemolytic blood picture

Group 2 (cases) - Megaloblastic anemia with features of hemolysis and peripheral blood picture showing schistocytes.

Any condition causing lowering of MCV and other causes of hemolytic anemia and true microangiopathic hemolytic anemia cases were excluded from the study.

Informed written consent was obtained from each patient. Complete Blood Count, Peripheral Blood Smear examination, manual reticulocyte count was done. Percentage of schistocyte count was done according to ICSH guidelines. Only helmet cells, keratocytes, triangle schistocytes, microcrescents and microspherocytes are included in the group of schistocytes. The number of schistocytes per 1000 red blood cells (RBC) was counted in oil immersion lens. To eliminate observer bias in identifying schistocytes, it was analyzed by separate hematologists. The average schistocytes percentage by two observers was calculated and used for analysis.

Biochemical parameters like serum vitamin B12, folic acid, and serum homocysteine level was calculated by semiautomatic ECLIA method. Serum LDH, bilirubin level was estimated by conventional method. Serum Iron profile and HPLC done

2.1. Statistical analysis

All the categorical characteristics were presented as frequency and percentage and all the continuous parameters were presented as mean \pm SD. To compare the categorical parameters among the different groups, either Chi square test or a Fischer exact test has been used. For multiple comparison tests, Bonferroni adjustment was done. Non-normally distributed continuous parameters were compared using Kruskal Wallis analysis of variance. Multiple

comparison test for such parameters (TLC, TPC), a pair wise Wilcoxon rank sum test was used. P- Value of <0.005 was considered statistically significant. All the analysis has been done using standard statistical software, Stata 13.1.

3. Results

60 patients were included in the study, out of which 30 were patients with megaloblastic anemia without hemolysis (clinical control) and 30 patients were megaloblastic anemia with features of hemolysis (Cases). Mean age of clinical control group was 22 where as that of cases was 14.1 years. Mean hemoglobin concentration in cases and clinical controls were 5.62 and 6.16 gm/dl respectively. MCV was 101.29 fl with SD of 7.17 in clinical controls as compared to the cases where mean MCV was 80.24 fl with SD of 10.88. So, the MCV was decreased in cases where as raised in clinical control group. Reticulocyte count in clinical control group was 1.06 with SD of 0.47. In case group, it was increased with a mean of 3.83% and SD of 1.5. TLC was within normal limit in both the groups. TPC was decreased in both cases and clinical control group. Among the biochemical parameters, vitamin B12 was decreased in both clinical control and cases. Serum LDH increased in both the groups. Mean serum bilirubin did not show any deviation from normal range, though some cases show increased level. Mean serum homocysteine level was increased in both clinical control group and cases (Table 1).

Schistocyte count was increased in both the groups, but it was on higher side (Mean+SD=1 \pm 0.66) in the case group as compared to clinical control group (Mean+SD=7.08 \pm 0.66) (Table 2).

On correlating between serum homocysteine, % schistocytes and MCV, there was Positive correlation between level of homocysteine and % of schistocytes (0.23), Negative correlation between level of Homocysteine and MCV (-0.19).

Statistically significant negative correlation between % schistocytes and MCV (-0.62) (Table 3, Figure 1).

4. Discussion

In severe megaloblastic anemia, patient presenting with hemolytic anemia, schistocytosis and thrombocytopenia resemble microangiopathic hemolytic anemia which is known as pseudo-thrombotic microangiopathy. A hallmark of these disorders is the fragmentation of erythrocytes by the microvascular thrombi, resulting in non-immune MAHA.²

Pathogenesis of pseudothrombotic microangiopathy in megaloblastic anemia is poorly understood, but may involve homocysteine induced endothelial injury and dysfunction. Hyperhomocystinemia triggers the activation of coagulation cascade and alter endothelial adhesive properties. In addition, macrocytic erythrocytes

Table 1: Distribution of different clinicopathological parameters within different groups

Parameters	Clinical control(N = 30) (Mean ± SD)	Cases(N = 30) (Mean ± SD)
Age	21.8 ± 16.01*	14.1 ± 2.86*
Hemoglobin	6.1 ± 2.04*	5.6 ± 1.40*
Reticulocyte Count	1.06 ± 0.47	3.83 ± 1.52
LDH	236.13 ± 110.10	342.40 ± 127.81
Total Bilirubin	1.15 ± 0.36	1.13 ± 0.57
Vitamin B12	92.49 ± 79.67	84.46 ± 40.54
Folic Acid	5.04 ± 5.70	4.50 ± 4.11
Homocysteine	31.15 ± 19.10	37.28 ± 15.06

Table 2: Distribution of schistocyte in cases and clinical control group

Study group	Mean± SD	95% confidence interval	P value
Clinical control(N=20)	1 ± 0.66	0.68 – 1.31	<0.001
Cases(N = 30)	7.08 ± 0.66	5.89 – 8.27	

Table 3: Correlation between Schistocyte percentage, Homocysteine and MCV

	Homocysteine	Percentage schistocyte	MCV
Homocysteine	1.00		
Percentage schistocyte	0.23	1.00	
MCV	-0.19	-0.62*	1.00

Series 1= Homocysteine, Series 2= MCV, Series 3= Percentage of schistocytes

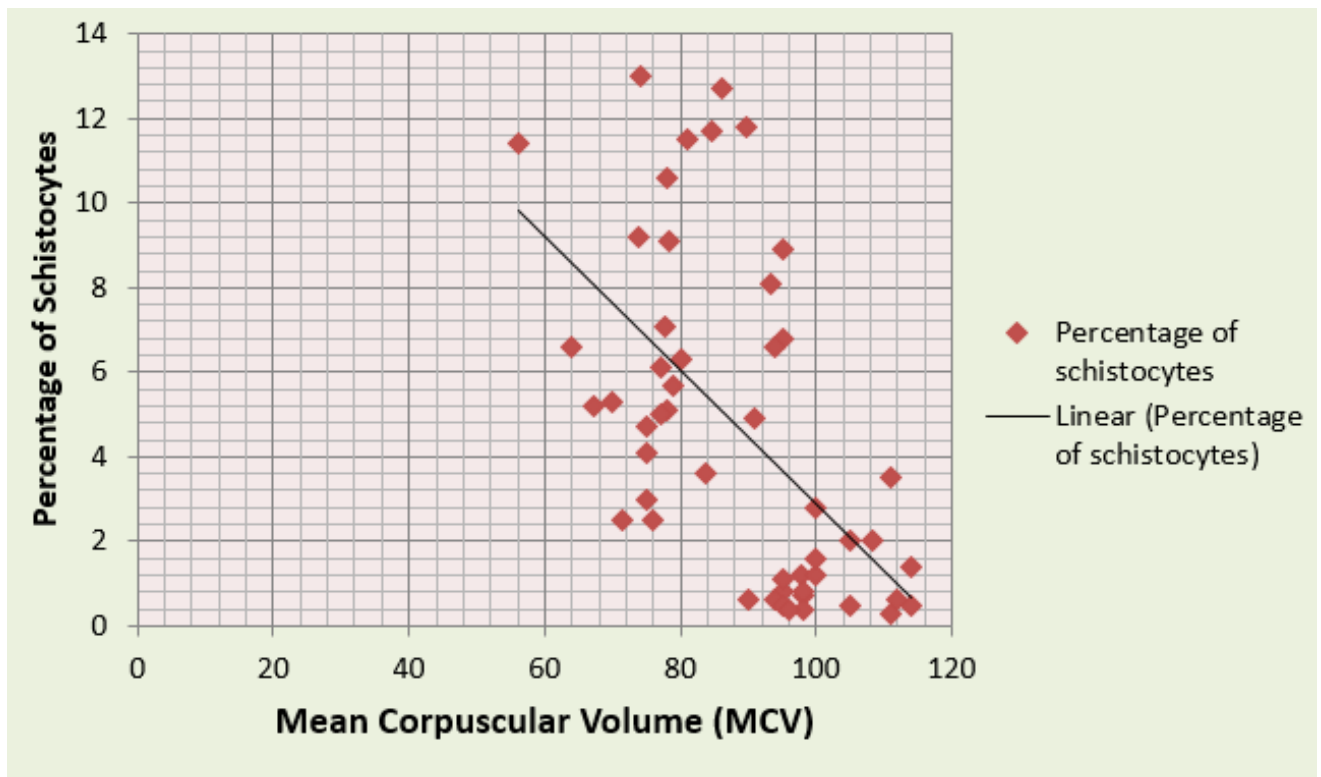


Fig. 1: Correlation between MCV and % of schistocytes

resulting from vitamin B12 deficiency have reduced deformability, which predispose to entrapment in the microcirculation. Furthermore, ineffective erythropoiesis secondary to vitamin B12 deficiency leads to intramedullary hemolysis, indirect hyperbilirubinemia, elevated LDH and microangiopathic features in peripheral blood smear.

Hyperhomocysteinemia leads to endothelial damage causing fragmentation of RBCs. It has also been demonstrated that the free radical oxygen species released during homocysteine oxidation is a well-known promoter of molecular peroxidation and toxic to RBCs causing fragmentation and schistocyte formation.

Homocysteine acts as a hemolytic toxin because of its pro-oxidant properties. It affects the down-regulation of cellular glutathione peroxidase-1 activity, facilitating the accumulation of reactive oxygen species, which may subsequently instigate the oxidative vulnerability of sulfhydryl groups of hemoglobin and thus leads to precipitation of hemoglobin within the RBCs. These events together consequently result in fragmentation of erythrocytes and manifest as microangiopathy. Thrombocytopenia occurs often as a part of megaloblastic abnormality in severe vitamin B12 deficiency and not due to immune mechanism.³⁻⁵ Although vitamin B12 deficiency presents with high MCV, normal to decreased MCV could be explained by presence of macrocytes as well as schistocytes.

In our study, we have included 60 cases of megaloblastic anemia with or without hemolysis. Mean age of clinical control group was 22 where as that of cases was 14.1 years. Mean serum homocysteine level was increased in both clinical control group and cases. This proves that cases of megaloblastic anemia with or without hemolysis, there was hyperhomocysteinemia. But patients of megaloblastic anemia with hemolysis, homocysteine level was on higher side. This finding corroborates to Acharya et al.⁵ Ventura et al in their in vitro study confirmed a well-known link between serum homocysteine and vitamin B12 level. The same data also suggests a possible effect of homocysteine accumulation in hemolysis in patients of megaloblastic anemia.⁴

Presence of schistocytes in the peripheral blood is abnormal and indicates the possibility of TMA especially in the absence of additional severe morphological RBC abnormalities. According to ICSH Schistocyte Working Group schistocyte percentage above 1% in a peripheral blood smear in adults is a cytomorphological indication favoring diagnosis of TMA. However, Very few data are available regarding presence of schistocytes in peripheral blood resembling pseudothrombotic microangiopathy in megaloblastic anemia in our study of 30 megaloblastic anemia patients with hemolysis (case), 29 had >1% of schistocytes in their peripheral blood picture. This signifies that the schistocytosis has a definite diagnostic value in

all cases with hemolysis and its presence should not essentially indicate diagnosis of true TMA. Andres et al in their study, demonstrated that out of 201 cases of megaloblastic anemia, 2.5% present with pseudothrombotic microangiopathy with schistocytes.¹ Acharya et al in their study of 3 cases in 2008 demonstrated that patients with coexisting megaloblastic anemia and MTHFR mutation have high risk of microangiopathy and hemolysis.⁵ They also have demonstrated severe hyperhomocysteinemia caused by vitamin B12 deficiency and MTHFR gene mutation and hemolysis completely resolved after vitamin B12 therapy.

Our study demonstrates a positive correlation between percentage of schistocytes and homocysteine. There is a negative correlation between MCV and homocysteine. So, it indicates that hyperhomocysteinemia causes increase in number of schistocytes and decrease in MCV. There is a statistically significant negative correlation existing between percentage of schistocytes and MCV. So, increased number of schistocytes decreases the MCV. Till now no data is available regarding degree of schistocytes with decreasing MCV in megaloblastic anemia with hemolysis.

In our follow up cases, we have seen that there is resolution of hemolysis with normalization of serum homocysteine level & decrease schistocyte count. So, we concluded that, hyperhomocysteinemia could be the cause of hemolysis mimicking pseudo microangiopathic blood picture in megaloblastic anemia.

Limitation of our study was that MTHFR gene mutation study was not done. Though hematological and biochemical parameters are improved after taking vitamin B12 therapy, but it could not return to normal level because of oral vitamin B12 therapy instead of parenteral route. Also follow up of all the cases could not be done properly.

5. Conclusion

From our study we have concluded that hyperhomocysteinemia occurs in megaloblastic anemia. When schistocytes are seen in megaloblastic anemia with hemolysis, it masquerades the peripheral blood picture as micro-angiopathic hemolytic anemia. Presence of schistocytes in megaloblastic anemia with hemolysis can decrease the MCV and mimics as microcytic hypochromic anemia.

Megaloblastic anemia with hemolysis (pseudothrombotic microangiopathy) more often misdiagnosed as thrombotic microangiopathy (TMA) and microangiopathic hemolytic anemia due to presence of schistocytosis with thrombocytopenia. Value of MCV can be spuriously low in these cases due to schistocytosis

Management of TMA is aggressive and requires plasmapheresis. However, cases of megaloblastic anemia with hemolysis can simply be treated with Vitamin B12 supplements. So, awareness of this condition in the

hematology community and reaching the precise diagnosis is critical.

6. Source of Funding

None.

7. Conflict of Interest

None.

References

1. Andres E, Affenberger S, Zimmer J, Vinzio S, Grosu D, Pistol G, et al. Current hematological findings in cobalamin deficiency. A study of 201 consecutive patients with documented cobalamin deficiency. *Clin Lab Haematol.* 2006;28(1):50–6.
2. Kottke K. Diagnostic approach to microangiopathic haemolytic disorders. *Int J Lab Hem.* 2017;39:69–75.
3. Antony AC. Megaloblastic Anemias. In: Goldman L, Schafer A, editors. *Goldman-Cecil Medicine.* Philadelphia: Elsevier Saunders; 2016. p. 514–45.
4. Ventura P, Panini R, Tremosini S, Salvioli G. A role for homocysteine increase in haemolysis of megaloblastic anaemias due to vitamin B12 and folate deficiency: results from an in vitro experience. *Biochem Biophys Acta.* 2004;1739(1):33–42.
5. Acharya U, Gau JT, Horvath W, Ventura P, Hsueh CT, Carlsen W. Haemolysis and hyperhomocysteinemia caused by cobalamin deficiency. Three case reports and review of literature. *J Hematol Oncol.* 2008;1:26.

Author biography

Sandhya Biswal PG Student

Ranjana Giri Associate Professor

Urmila Senapati Professor

Cite this article: Biswal S, Giri R, Senapati U. Schistocytosis in megaloblastic anemia masquerading peripheral blood picture as maha (microangiopathic hemolytic anemia) and decrease mean corpuscular volume. *Indian J Pathol Oncol* 2020;7(3):357-361.