



## Case Report

# Management of Coats' disease with Razumab™ (World's first biosimilar ranibizumab) and laser photocoagulation: A case report

Bhagwati Prasad Sharma<sup>1</sup>, Shashikant Sharma<sup>2,\*</sup>

<sup>1</sup>Sharma Netralaya, Bhilai, Chhattisgarh, India

<sup>2</sup>Dept. of Medical Affairs, Intas Pharmaceuticals Limited, Ahmedabad, Gujarat, India



### ARTICLE INFO

#### Article history:

Received 06-10-2020

Accepted 26-11-2020

Available online 01-04-2021

#### Keywords:

Biosimilar

Coats' disease

Laser photocoagulation

Ranibizumab

### ABSTRACT

We report a case of a 19-year-old Indian male with stage 2 Coats' disease who was managed with monthly intravitreal biosimilar ranibizumab injections (n=3) along with laser photocoagulation in the right eye. Post-treatment, significant reductions were seen in the exudation, angioma-like lesions, central macular thickness and edema in the retina. At the last follow-up at 9 months after intravitreal biosimilar ranibizumab initiation, distant vision improved from best corrected visual acuity (BCVA) of 5/60 at baseline to 6/18, and near vision from 'not able to read' to N/12 in the right eye.

© This is an open access article distributed under the terms of the Creative Commons Attribution License (<https://creativecommons.org/licenses/by/4.0/>) which permits unrestricted use, distribution, and reproduction in any medium, provided the original author and source are credited.

## 1. Introduction

Coats' disease, a rare idiopathic unilateral ophthalmic condition, is associated with development of retinal vasculature (telangiectasia) causing exudative retinopathy (intra- and sub-retinal exudation), which may result in retinal detachment leading to vision loss.<sup>1</sup> The therapeutic armamentarium of Coats' disease include laser photocoagulation, cryotherapy, surgery and triamcinolone.<sup>2</sup> Anti-vascular endothelial growth factor (VEGF) agents, including ranibizumab, have also demonstrated beneficial effects.<sup>3</sup> Razumab™, the world's first biosimilar ranibizumab, has demonstrated efficacy and safety in several macular disorders.<sup>4,5</sup> Limited data exists on Coats' disease from Indian subcontinent. We report a case of an Indian patient with Coats' disease managed using biosimilar ranibizumab.

## 2. Case Report

A 19-year-old man presented with diminution of vision in both eyes since 6 months. There was no past history of any

significant ocular disease.

On examination, the best corrected visual acuity (BCVA) in the right eye was 5/60 with counting of fingers close to the face (CFCF) in the left eye. Examination of the fundus demonstrated a large area of sub-retinal exudation and multiple angioma-like lesions in the center of exudation in the entire fundus in both eyes (Figure 1). The fundus fluorescein angiography (FFA) demonstrated leaking aneurysm-like vascular anomalies (Figure 2) and optical coherence tomography (OCT) showed collection of intraretinal and subretinal fluid in both eyes (Figure 3). The central macular thickness (CMT) was 691μ and 317μ in right and left eye, respectively. The diagnosis was made as stage 2 Coats' disease.

Monthly intravitreal biosimilar ranibizumab was administered for 3 months in the right eye followed by 3 sittings of laser photocoagulation. In the left eye, 3 sittings of laser photocoagulation were given whereas biosimilar ranibizumab was not administered on patient's unwillingness due to the poor visual prognosis.

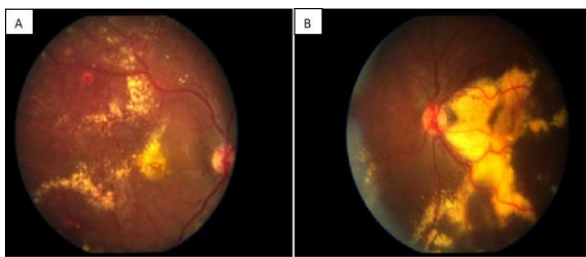
After the first intravitreal biosimilar ranibizumab injection, his BCVA improved to 6/24, and edema was reduced to some extent; no significant improvement seen

\* Corresponding author.

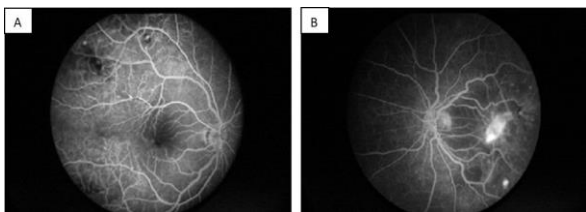
E-mail address: [shashikant\\_sharma@intaspharma.com](mailto:shashikant_sharma@intaspharma.com) (S. Sharma).

after the second injection. After 3 months, significant improvement was demonstrated in vision with BCVA of 6/18, and a significant reduction in the exudation, edema in retina and angioma-like lesions (Figure 4) was reported in the right eye. Also, a reduction in the CMT from  $691\mu$  to  $339\mu$  was observed and the OCT demonstrated uneventful recovery in the right eye (Figure 5). In the left eye, the vision remained same whereas CMT increased from  $317\mu$  to  $672\mu$ .

The patient's last follow-up done in October 2018 demonstrated improved distant vision of 6/18 from the baseline (January 2018) vision of 5/60 and improved baseline near vision from not able to read to N/12 vision in the right eye. There were no improvements in the distant or near visions in the left eye.



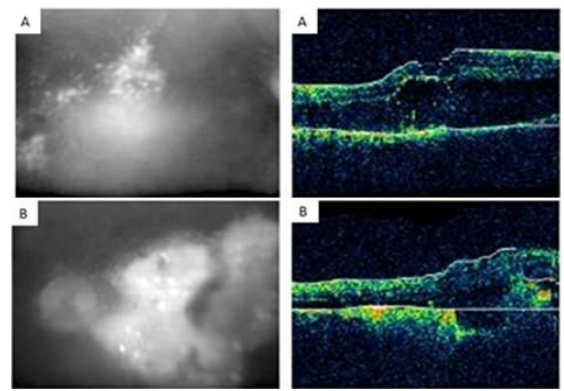
**Fig. 1:** Fundoscopy images showing sub-retinal exudation and multiple angioma-like lesions together with exudates and telangiectasis as well as dilation of retinal vessels (A) right eye (B) left eye



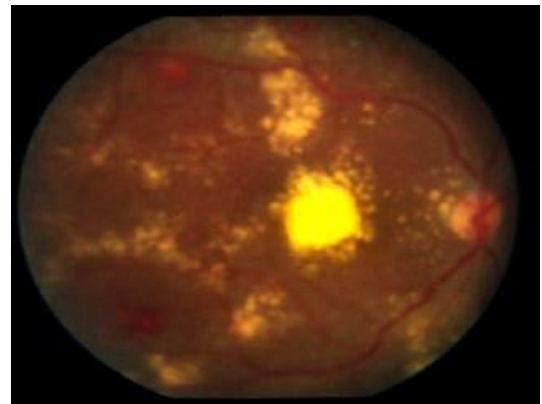
**Fig. 2:** FFA showing several leaking aneurysms (A) right eye (B) left eye

### 3. Discussion

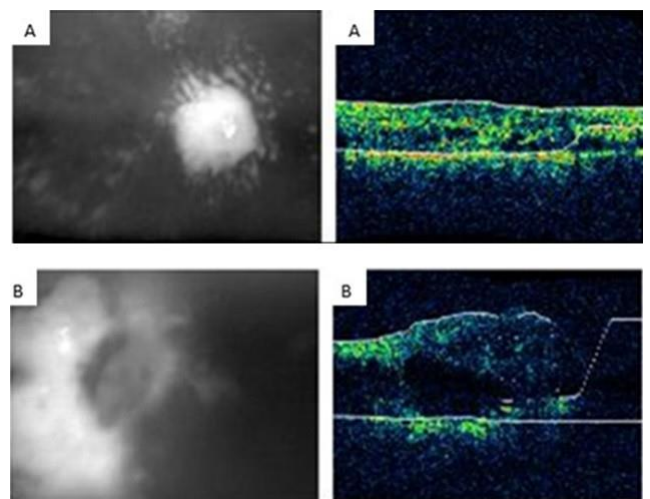
Anti-VEGF agents have modernized the treatment of several retinal diseases in adults including diabetic retinopathy and are also used in children.<sup>6,7</sup> Bevacizumab, an anti-VEGF, has been studied extensively in managing Coats' disease but its use is associated with a risk of vitreoretinal fibrosis and tractional retinal detachments, hence, should be used with caution.<sup>8</sup> Ranibizumab, an anti-VEGF, has been approved for the treatment of several macular disorders including wet age-related macular degeneration (AMD), retinal vein occlusion (RVO), diabetic macular edema (DME), and myopic choroidal neovascularization (CNV).<sup>9,10</sup> Ranibizumab has also been evaluated for



**Fig. 3:** OCT imaging showing intraretinal and subretinal fluid accumulation (A) right eye (B) left eye



**Fig. 4:** Fundoscopic imaging at 3 months post-treatment with intravitreal biosimilar ranibizumab showing reduction in exudation in right eye



**Fig. 5:** OCT imaging at 3 months post-treatment demonstrating (A) recovery in the right eye (B) worsening in the left eye due to presence of fluid

the treatment of Coats' disease in children in previous reports.<sup>3,11,12</sup> We report the successful management of Coats' disease with adjuvant intravitreal biosimilar ranibizumab injection along with laser photocoagulation. The use of anti-VEGF agents may enhance the activity of laser therapy by decreasing the vascular permeability of the capillary endothelial cells.<sup>13</sup>

The treatment goal in the Coats' disease is focused at managing the telangiectatic vessels to control and resolve intra and sub-retinal exudates and eventually vision salvation.<sup>2</sup> The patient, in the present case-scenario, demonstrated vision recovery in the right eye where both intravitreal biosimilar ranibizumab and laser therapy were employed compared to no improvement in the left eye, which was managed using laser therapy only. Furthermore, biosimilar ranibizumab treatment showed reduction in intraretinal and subretinal exudation, multiple angioma-like lesions, telangiectasis as well as in the dilation of retinal vessels in our patient. There were no injection-related ocular or systemic adverse events during treatment and follow-up. Thus, the adjuvant administration of intravitreal biosimilar ranibizumab was appropriate in the present case-scenario.

Intravitreal ranibizumab combined with other ablative therapies was effective in visual acuity improvement from logMAR BCVA of  $1.4 \pm 0.7$  to  $1.1 \pm 0.5$  ( $P < 0.001$ ) in patients ( $n=17$ ) with Coats' disease. Also regression of telangiectasia and resolution of the exudate were observed. There were no severe ocular or systemic side-effects reported.<sup>12</sup> Intravitreal ranibizumab plus conventional amblyopia treatment resulted in transient restoration of the hemato-retinal barrier and suppression of neovascularization amongst patients with Coats' disease. This was propounded on the basis of resolution of iris neovascularization within 2 weeks of treatment with anatomical success.<sup>8</sup> Giannakopoulos and colleagues reported the long-term results of Coats' disease after treatment with ranibizumab and demonstrated a visual acuity of 20/20 with no exudates or edema at 20 months of follow-up; the patient was stable at 6 years of follow-up.<sup>13</sup>

Biosimilar ranibizumab with laser photocoagulation significantly reduced the exudation, angioma-like lesions, CMT and edema in retina, and improved visual acuity in a patient with Coats' disease. The current case provides insights for biosimilar ranibizumab based options for Coats' disease, which needs to be further studied.

#### 4. Acknowledgments

We thank Dr. Tanishq Sharma (Shree Krishna Hospital, Karamsad, Gujarat, India) for conceptualizing the project, facilitating the study documentation and providing independent medical review. We also thank Mr. Shreekant Sharma ISMPP CMPP™ for his support in developing the concept/medical writing, additional editorial support and follow-up with the journal/publisher, and Dr. Venugopal

Madhusudhana ISMPP CMPP™ (Intas Pharmaceuticals Limited) for additional editorial assistance.

#### 5. Source of Funding

The case report development was supported by Intas Pharmaceuticals Ltd.

#### 6. Conflict of Interest

Dr. Shashikant Sharma is an employee of Intas Pharmaceuticals Ltd, Ahmedabad, India.

#### References

- Shields JA, Shields CL, Honavar SG, Demirci H. Clinical variations and complications of Coats disease in 150 cases: the 2000 Sanford Gifford Memorial Lecture. *Am J Ophthalmol*. 2001;131(5):561–71.
- Shields C, Sen M, Honavar SG, Shields JA. Coats disease: An overview of classification, management and outcomes. *Indian J Ophthalmol*. 2019;67(6):763–71.
- Zhang L, Ke Y, Wang W, Shi X, Hei K, Li X. The efficacy of conbercept or ranibizumab intravitreal injection combined with laser therapy for Coats' disease. *Graefes Arch Clin Exp Ophthalmol*. 2018;256(7):1339–46.
- Sharma S, Khan MA, Chaturvedi A. RE-ENACT 2 Study Investigators Group. A Multicenter, Retrospective Study (RE-ENACT 2) on the use of Razumab™ (World's First Biosimilar Ranibizumab) in Wet AMD, DME, RVO and Myopic CNV. *J Clin Exp Ophthalmol*. 2019;10(826).
- Sharma S, Khan MA, Chaturvedi A. RE-ENACT Study Investigators Group. Real-Life Clinical Effectiveness of Razumab® (the World's First Biosimilar of Ranibizumab) in Retinal Vein Occlusion: A Subgroup Analysis of the Pooled Retrospective RE-ENACT Study. *Ophthalmologica*. 2019;241(1):24–31.
- Maurya RM. Current scenario and distribution of NABL Accredited laboratories in India. *J Pharmacol Clin Res*. 2017;3(5):1–8.
- Gupta SK, Yadav I, Deshmukh S, Maurya RP, Singh VP. Predictors of visual response to intravitreal Bvacuzumab for treatment of diabetic macular edema. *Ind J Clin Ophthalmol*. 2015;1(1):35–40.
- Ghorbanian S, Jaulim A, Chatziralli IP. Diagnosis and Treatment of Coats' Disease: A Review of the Literature. *Ophthalmologica*. 2012;227(4):175–82.
- Sharma S, Khan M, Chaturvedi A. RE-ENACT 2 Study Investigators Group. A Multicenter, Retrospective Study (RE-ENACT 2) on the Use of Razumab™ (World's First Biosimilar Ranibizumab) in Wet Age-Related Macular Degeneration. *Ophthalmol Ther*. 2020;9(1):103–14.
- Maurya RP. Dabetic macular edema: An overview. *Indian J Clin Exp Ophthalmol*. 2019;5(1):1–2.
- Gaillard MC, Mataftsi A, Balmer A, Houghton S, Munier FL. Ranibizumab in the management of advanced coats disease stages 3B and 4. *Retina*. 2014;34(11):2275–81.
- Yang Q, Wei W, Shi X, Yang L. Successful use of intravitreal ranibizumab injection and combined treatment in the management of Coats' disease. *Acta Ophthalmol*. 2016;94(4):401–6.
- Giannakopoulos M, Drimtzias E, VPanteli, Vasilakis P, Gartaganis SP. Intravitreal ranibizumab as an adjunctive treatment for coats disease (6-year follow-up). *Retin Cases Brief Rep*. 2017;11(4):339–43.

#### Author biography

**Bhagwati Prasad Sharma**, Medical Director

**Shashikant Sharma**, Medical Lead (Ophthalmology)

**Cite this article:** Sharma BP, Sharma S. Management of Coats' disease with Razumab<sup>TM</sup> (World's first biosimilar ranibizumab) and laser photocoagulation: A case report. *Indian J Clin Exp Ophthalmol* 2021;7(1):246-249.