



Case Report

G15043A mutation in a case of autosomal recessive optic atrophy. Causative or incidental?

Vijay Sardana¹, Pallav Jain^{1,*}

¹Dept. of Neurology, Government Medical College, Kota, Rajasthan, India



ARTICLE INFO

Article history:

Received 27-06-2020

Accepted 24-07-2020

Available online 31-03-2021

Keywords:

Autosomal recessive optic atrophy

Hereditary optic atrophy

G15043A mutation

ABSTRACT

Autosomal recessive inheritance pattern in a case of hereditary optic atrophy is uncommon. Patients with recessive optic atrophy without involvement of any other system are rare. There is no causative gene or genetic mutation associated with it. Here we report a case of a 16-year-old girl which was diagnosed to be a case of AROA. Genetic analysis done in this patient revealed G15043A mutation. Identification of similar cases of the AROA can increase our understanding of the disorder and formulate treatment options.

© This is an open access article distributed under the terms of the Creative Commons Attribution License (<https://creativecommons.org/licenses/by/4.0/>) which permits unrestricted use, distribution, and reproduction in any medium, provided the original author and source are credited.

1. Introduction

Patients of optic atrophy generally presents to clinician with complaints decreased visual acuity, abnormalities in colour vision and also visual field defects. Optic disc pallor is generally seen on fundoscopic examination of the patient. Axons of retinal ganglion cells forms the optic nerve and their degeneration results in optic atrophy. Optic atrophy can be hereditary or acquired. Acquired causes can be secondary to nutrition or toxins.¹ Hereditary causes include patients with autosomal dominant or autosomal recessive pattern of inheritance or the more common Leber's hereditary optic neuropathy which has mitochondrial inheritance. Hereditary causes can present either in the form of isolated optic atrophy or can have involvement of various others systems along with features of optic atrophy.²

Syndromic optic atrophy patients generally presents with various neurologic and systemic symptoms along with symptoms of optic atrophy whereas in patients of nonsyndromic optic atrophies, only optic nerve degeneration is seen. Genes which encodes mitochondria-related proteins are generally defective in nonsyndromic optic atrophies. LHON and autosomal dominant OPA1-

linked OPA are the common forms of nonsyndromic optic atrophy having maternal and autosomal dominant inheritance respectively. Patients with optic atrophy having autosomal recessive inheritance are uncommon and majority of cases have evidence of other system involvement.³ Patients who have autosomal recessive optic atrophy without involvement of any other system are extremely rare. Congenital presentation or presentation before 3 years of age, an autosomal recessive pattern of inheritance and severe involvement associated with nystagmus or severe dyschromotopsia can help us in differentiating them from other syndromic recessive optic atrophy.⁴ Here we illustrate a case which has family history as well as clinical features suggestive of nonsyndromic autosomal recessive optic atrophy.

2. Case History

A 16-year old female patient presented in neurology OPD with complaint of bilateral decrease in visual acuity since childhood. Symptoms were first noticed when the child was three years old. The vision loss was gradual progressive, painless and bilateral symmetrical. Patient had no history of birth asphyxia, perinatal insult and had normal intellectual development There was no abnormalities in hearing and

* Corresponding author.

E-mail address: jainpallav89@gmail.com (P. Jain).

speech. The child did not have history of trauma during development. Family history was negative for decrease vision, any other systemic or neurologic disease. Apart from visual loss, general and detailed neurological examination was normal. Direct and indirect response pupillary response was normal. Visual acuity was 6/36 in right eye and 6/60 in left eye with no improvement on pin hole. On ophthalmological examination -bilateral pale optic disk with cupping was seen.(Figure 1).

Electrocardiogram was normal. His serum sodium=132 meq/l, Serum pottasium= 4.1meq/l, Serum calcium= 9.8 mg/dl, Serum magnesium= 2.1 meq/l. Fasting blood sugar=82mg/dl, Serum Creatinine= 0.9 mg/dl, Blood Urea= 32mg/dl, all were normal. Vitamin B12- 812mg/dl. Magnetic resonance imaging(Figure 2) of the patient showed no significant anomaly. Nerve conduction studies and pure tone audiometry study done were normal. After careful history, examination and investigations the patient was diagnosed as a case of autosomal recessive optic atrophy. Genetic testing was done for the patient which revealed a G15043A mutation. Testing was negative for LHON and autosomal dominant optic atrophy.

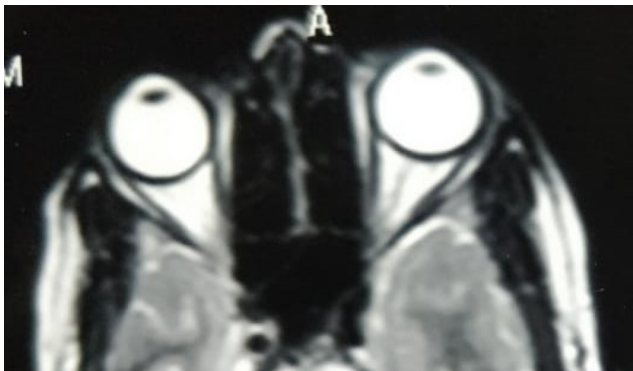


Fig. 1:

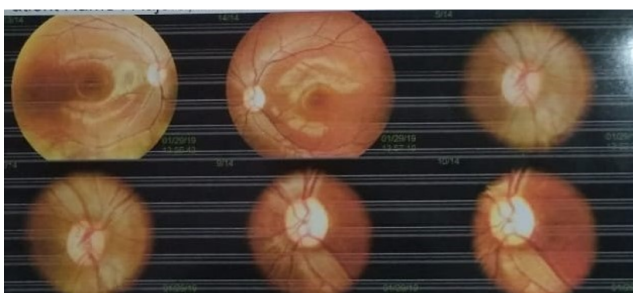

Fig. 2:

3. Discussion

No cause has still been conclusively found for this rare form of hereditary optic atrophy. Barbet F et al. have studied

that patients with recessive optic atrophy have disease causing gene mapped to chromosome 8q21-q22.⁴ Though cases of autosomal recessive optic atrophy has also been associated with mutation in TMEM126A in one of the study,⁵ but Meyer et al. found sensorineural hearing defects and sensori-motor axonal polyneuropathy in patients who have mutations in TMEM126A gene, making the possibility of nonsyndromic recessive optic atrophy as the less likely cause.⁶ One more case of 2 year old child was reported with optic atrophy with autosomal recessive pattern of inheritance and no mutation was reported in the case.⁷ No mutation has been shown to be linked with autosomal recessive optic atrophy.

Our patient was clinically diagnosed to be a case of autosomal recessive optic atrophy, had revealed G15043A mutation during genetic testing. Whether this mutation is incidental or linked to the disorder is debatable. Though there is no diagnostic methods and management strategies for this disease, more reporting of similar cases can help us to know this disease better.

4. Conclusion

Here we have illustrated a case of autosomal recessive optic atrophy diagnosed in a 16-year old female patient with bilateral painless visual loss with optic atrophy with G15043A mutation. As mutation for this disorder is still elusive, our case can add to possible genetic mutations linked with this disorder. Identification of similar cases can help us know the underlying pathophysiology of this disease and causative genetic mutation and may help us in formulating management options for this rare disease.

5. Source of Funding

None.

6. Conflict of Interest

The authors declare that there is no conflict of interest.

References

1. Carelli V. Optic nerve degeneration and mitochondrial dysfunction: genetic and acquired optic neuropathies. *Neurochem Inte.* 2002;40(6):573–84.
2. Morgia CL, Carbonelli M, Barboni P, Sadun AA, Carelli V. Medical Management of Hereditary Optic Neuropathies. *Front Neurol.* 2014;5:141. doi:10.3389/fneur.2014.00141.
3. Désir J, Coppieters F, Regemorter NV, Baere ED, Abramowicz A, Cordonnier M. TMEM126A mutation in a Moroccan family with autosomal recessive optic atrophy. *Mol Vis.* 2012;18:1849–57.
4. Barbet F, Gerber S, Hakiki S, Perrault I, Hanein S, Ducroq D, et al. A first locus for isolated autosomal recessive optic atrophy (ROA1) maps to chromosome 8q. *Eur J Hum Genet.* 2003;11(12):966–71. doi:10.1038/sj.ejhg.5201070.
5. Hanein S, Perrault I, Roche O, Gerber S, Khandom N, Rio M. TMEM126A, encoding a mitochondrial protein, is mutated in autosomal recessive nonsyndromic optic atrophy. *Am J Hum Genet.* 2009;84:493–501.

6. Meyer E, Michaelides M, Teelj, Robson AG, Rahman F, Pasha S, et al. Nonsense mutation in TMEM 126 A causing autosomal recessive optic atrophy and auditory neuropathy. *Mol Vis.* 2010;16:650–64.
7. Arain FM, Chand P, Choudary TA. A rare case of simple hereditary recessive optic atrophy. *Pak J Neurol Sci.* 2015;10(2):34–5.

Pallav Jain, Senior Resident

Cite this article: Sardana V, Jain P. G15043A mutation in a case of autosomal recessive optic atrophy. Causative or incidental?. *Indian J Clin Exp Ophthalmol* 2021;7(1):168-170.

Author biography

Vijay Sardana, Principal, Senior Professor