



Case Report

IOL decentration post Nd-YAG laser capsulotomy

Ruminder Kaur^{1,*}

¹Dept. of Vitreo Retino, Sankara Eye Hospital, Ludhiana, Punjab, India



ARTICLE INFO

Article history:

Received 17-09-2020

Accepted 26-09-2020

Available online 31-03-2021

Keywords:

Yag Cap

IOL

Decentration

ABSTRACT

One of the most common cause of decrease of vision in a pseudophakic patient is the formation of posterior capsular opacification (PCO) which is affected by several factors like the design of the implanted intraocular lens (IOL) and material of the IOL. PCO incidence has been reported to be 20.7% at 2 years & 28.5% at 5 years. Decrease of vision because of PCO necessitates a posterior capsulotomy with neodymium yttrium aluminum garnet (Nd-YAG) laser to create a small opening in the developed opacification. It is a commonly performed relatively safe procedure associated with rare complications like increased intraocular pressure, iritis, IOL Pitting, macular edema, retinal haemorrhage, retinal detachment and endophthalmitis. Herein documenting a case of IOL decentration occurring as an acute complication post Yag Cap leading to decrease of the visual acuity of the patient which has been rarely documented in any of the many articles on Yag complications.

© This is an open access article distributed under the terms of the Creative Commons Attribution License (<https://creativecommons.org/licenses/by/4.0/>) which permits unrestricted use, distribution, and reproduction in any medium, provided the original author and source are credited.

1. Introduction

One of the most common cause of decrease of vision in a pseudophakic patient is the formation of Posterior Capsular opacification (PCO) which is affected by several factors like the design of the implanted intraocular lens (IOL) and material of the IOL.¹⁻³ PCO incidence has been reported to be 20.7% at 2 years & 28.5% at 5 years.⁴ Decrease of vision because of PCO necessitates a posterior capsulotomy with neodymium yttrium aluminum garnet (Nd-YAG) laser to create a small opening in the developed opacification. It is a commonly performed relatively safe procedure associated with rare complications like increased intraocular pressure, iritis, IOL pitting, macular edema, retinal haemorrhage, retinal detachment and endophthalmitis. Here in documenting a case of IOL decentration occurring as an acute complication post YAG-laser capsulotomy. YAG Capsulotomy leading to decrease of the visual acuity of the patient due to IOL decentration has been rarely documented in literature as a complications.

IOL decentration is calculated as the distance between the IOL centre and the reference axis (the reference axis being the pupillary axis or the visual axis).⁵⁻⁷ Decentration of 0.2–0.3 mm is common and clinically unnoticed for any design of IOL, larger extent decentration has a negative impact on the optical performance of the IOL and subsequently, the patients' vision and satisfaction.⁸

2. Case Report

A 66-year old pseudophakic patient presented in OPD with complaint of decrease of vision in her right eye for two months. Her BCVA right eye was 6/12 and left eye 6/6, anterior segment was normal with presence of a foldable IOL with posterior capsular opacification in right eye. Fundus was completely normal both eyes. She was explained the need for YAG-laser capsulotomy which she underwent same day. Eye drops were prescribed and she was asked to review after one week. She presented one week later with complaint of complete loss of vision in her same eye for last two days. Knowing the complications of YAG-laser with a probability of retinal detachment (RD) in mind

* Corresponding author.

E-mail address: rimmy_2015@yahoo.com (R. Kaur).

she was examined but to a surprise her IOL had undergone decentration, optic had moved out of centre and haptic had come in the central position causing her vision to decrease to CF counting finger at 2meter.

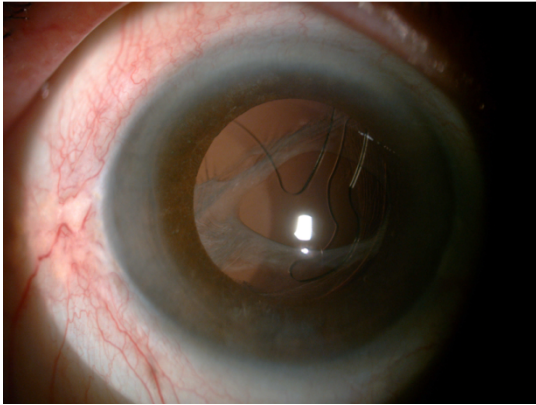


Fig. 1: Showing decentred IOL post Yag Capsulotomy

3. Discussion

YAG-laser capsulotomy is a common procedure done routinely by all ophthalmologists in their practices. Well known complications like IOL pitting, macular oedema and RD all are aware of. In this patient a rare complication i.e IOL decentration happened five days after the procedure (highlighting that capsulotomy was done using minimal energy, was small in size, and the ophthalmologist has been doing Capsulotomies for the last many years). Reporting this since IOL decentration has not been mentioned in most of the reports of Yag Cap complications available in literature and most of the ophthalmologists might not be aware of such a surprise post YAG-laser capsulotomy. Even in a paper by Derek O'Boyle which is a large literature review of 19 studies of Yag related complications none of the 19 studies have IOL decentration as an occurrence.⁹

4. Conclusion

YAG-laser capsulotomy is an out-patient procedure done by all ophthalmologists for posterior capsular opacification. It is known to be associated with complications like macular edema, IOL pitting and retinal detachment. IOL decentration is a rare complication post YAG-laser

capsulotomy and should be kept in mind specially in eyes with foldable IOL's.

5. Source of Funding

None

6. Conflict of Interest

The authors declare that there is no conflict of interest.

References

1. Apple MW. School Knowledge for the Masses: World Models and National Primary Curricular Categories in the Twentieth Century. John W. Meyer, David H. Kamens, Aaron Benavot, Yua-Kyung Cha, Suk-Ying Wong. *Comp Educ Rev.* 1993;37(3):322-4. doi:10.1086/447193.
2. Vasavada AR. The work and influence of the Raghudeep Eye Clinic, Ahmedabad, India. *Expert Rev Ophthalmol.* 2013;8(6):523-5. doi:10.1586/17469899.2013.847791.
3. Pandey SK, Apple DJ, Werner L, Maloof AJ, Milverton EJ. Posterior Capsule Opacification: A Review of the Aetiopathogenesis, Experimental and Clinical Studies and Factors for Prevention. *Indian J Ophthalmol.* 2004;52(2):99.
4. Nakazawa M, Ohtsuki K. Apparent Accommodation in Pseudophakic Eyes after Implantation of Posterior Chamber Intraocular Lenses. *Am J Ophthalmol.* 1983;96(4):435-8. doi:10.1016/s0002-9394(14)77905-x.
5. de Castro A, Rosales P, Marcos S. Tilt and decentration of intraocular lenses in vivo from Purkinje and Scheimpflug imaging. *J Cataract Refractive Surg.* 2007;33(3):418-29. doi:10.1016/j.jcrs.2006.10.054.
6. Nishi Y, Hirschschall N, Crnej A, Gangwani V, Tabernero J, Artal P, et al. Reproducibility of intraocular lens decentration and tilt measurement using a clinical Purkinje meter. *J Cataract Refractive Surg.* 2010;36(9):1529-35. doi:10.1016/j.jcrs.2010.03.043.
7. Sato T, Shibata S, Yoshida M, Hayashi K. Short-term Dynamics after Single- and Three-piece Acrylic Intraocular Lens Implantation: A Swept-source Anterior Segment Optical Coherence Tomography Study. *Sci Rep.* 2018;8(1):1023. doi:10.1038/s41598-018-28609-1.
8. Ale J. Intraocular lens tilt and decentration: A concern for contemporary IOL designs. *Nepal J Ophthalmol.* 2011;3:68-77.
9. O'Boyle D, Vives CP, Samavedam S, Ender F, deHaan J, Shaikh J, et al. PMD1 - POST-ND:YAG Laser complications in cataract patients treated for posterior capsular opacification: a systematic literature review. In: Value in Health. vol. 21. Elsevier BV; 2018. p. S243. doi:10.1016/j.jval.2018.09.1450.

Author biography

Ruminder Kaur, Vitreoretina Consultant

Cite this article: Kaur R. IOL decentration post Nd-YAG laser capsulotomy. *Indian J Clin Exp Ophthalmol* 2021;7(1):157-158.