

Content available at: <https://www.ipinnovative.com/open-access-journals>

Indian Journal of Clinical and Experimental Ophthalmology

Journal homepage: [www.ijceo.org](http://www.ijceo.org)

## Short Communication

## A rare case of oguchi disease exhibiting the classic Mizuo-Nakamura phenomenon

Nischala Balakrishna<sup>1,\*</sup>, Alhaj F Tasneem<sup>1</sup>, Vittal I Nayak<sup>1</sup>, Nagalakshmi Narayanaswamy<sup>1</sup>, Sara Nastain<sup>1</sup><sup>1</sup>Dept. of Ophthalmology, Vydehi Institute of Medical Sciences and Research Centre, Bangalore, Karnataka, India

## ARTICLE INFO

## Article history:

Received 04-04-2020

Accepted 22-04-2020

Available online 22-12-2020

## Keywords:

Congenital stationary night blindness

Mizuo-Nakamura phenomenon

Oguchi disease

Rod electroretinogram

## ABSTRACT

**Introduction:** Oguchi disease also called congenital stationary night blindness is an autosomal recessive genetic condition first identified in Japan with a few cases reported in other countries like Europe, America, India and Pakistan. We report one such case exhibiting the Mizuo-Nakamura phenomenon with a reduced amplitude on the b-wave of the rod electroretinogram advocating this diagnosis.

**Case Report:** A 40-year-old man presented with complaints of non-progressive decrease in vision as the day progressed for 6 months with normal vision during the day in both eyes. There was no history of trauma or any other ocular or systemic disease. His parents had a second-degree consanguineous marriage and his father experienced similar symptoms. Visual acuity for distance was 6/6 and N6 for near in both eyes. His anterior segment and posterior segments were normal. When the patient was put to dark adaptation for 3 hours, there was a change in his fundus background colour from grey to red (Mizuo-Nakamura phenomenon). The b-wave amplitude was decreased on the rod electroretinogram. The cone electroretinogram on the other hand was normal. All this was confirmed by his genetic study which favoured this diagnosis.

**Conclusion:** This disease presents with features similar to retinitis pigmentosa in terms of mutations in the SAG gene. This highlights the importance of the Mizuo-Nakamura phenomenon in formulating a confirmatory diagnosis and treatment protocol.

© This is an open access article distributed under the terms of the Creative Commons Attribution License (<https://creativecommons.org/licenses/by/4.0/>) which permits unrestricted use, distribution, and reproduction in any medium, provided the original author and source are credited.

## 1. Introduction

Oguchi's disease is a rare autosomal recessive disorder. It is also known as congenital stationary night blindness and was initially described in the year 1907 by a Japanese clinician by name Chuta Oguchi.<sup>1</sup> Although mostly found in Japan, few cases have also been reported in India, Pakistan and the Far West. The patient presents with diminished vision during the night with fairly normal vision during the day. This decrease in vision is non-progressive and is similar in symptomatic presentation to conditions like Retinitis Pigmentosa, Stargardts disease, Juvenile retinoschisis and Progressive cone dystrophy. Although these conditions have unique fundus findings and electroretinogram readings

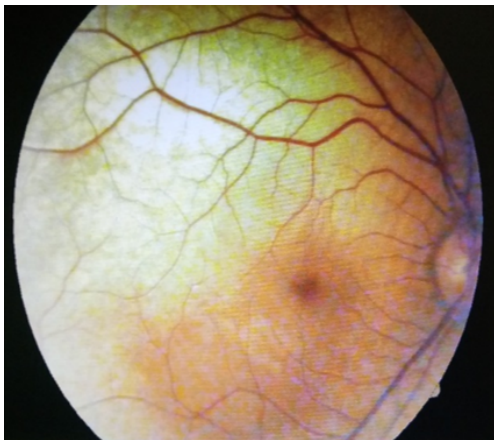
which are confirmatory of their diagnosis, Oguchi's disease has a normal fundus picture with a decrease in the amplitude of the b-wave on the rod electroretinogram with a normal cone electroretinogram.<sup>2</sup> The patient experiences a characteristic phenomenon, named after its founders, Mizuo and Nakamura. This unique morphological and functional abnormality of the retina is a typical golden yellow or sometimes a silver-grey discolouration of the retina and posterior segment of light which disappears after dark adaptation only to reappear again in the presence of light.<sup>3</sup> These features along with genetic testing is confirmatory as the mutations in the SAG gene involved in Oguchi's disease may also be involved in few cases of familial retinitis pigmentosa.

\* Corresponding author.

E-mail address: [nischalabalakrishna@gmail.com](mailto:nischalabalakrishna@gmail.com) (N. Balakrishna).

## 2. Case Report

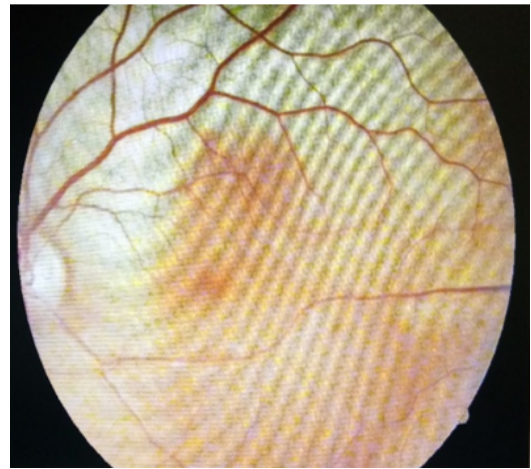A 40-year-old man presented with complaints of non-progressive decrease in vision as the day progressed for 6 months with normal vision during the day in both eyes. There was no history of trauma or any other ocular or systemic disease. His parents as a second-degree consanguineous marriage and his father experienced similar symptoms. Visual acuity for distance was 6/6 and N6 for near in both eyes. His anterior segment and posterior segment were normal with no evidence of bony spicules or atrophy. Visual field examination, using the Humphrey's visual field analyser and colour vision was normal bilaterally. The fundus showed a golden to grey discolouration in light (Figures 1 and 2). When subjected to dark adaptation for 3 hours, the fundus colour changed to red (Mizuo-Nakamura phenomenon) (Figures 3 and 4). The rod electroretinogram showed reduced amplitude in the b-wave (Figure 5) while the cone electroretinogram was normal suggestive of retinal dysfunction rather than degeneration (Figure 6). Examination of the man's mother and his two brothers were unremarkable. The father could not be evaluated as he had passed away in a road traffic accident two years ago.



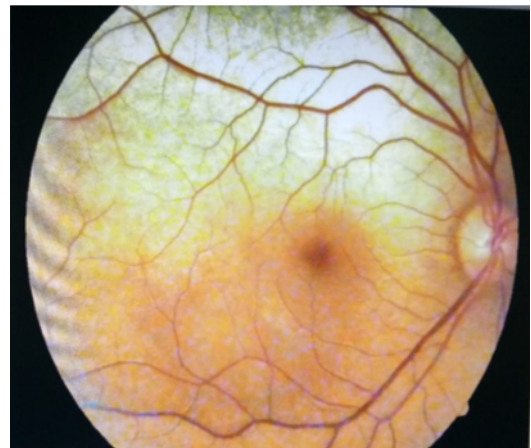
**Fig. 1:** Fundus picture of the right eye showing retina in light with grey discolouration

## 3. Discussion

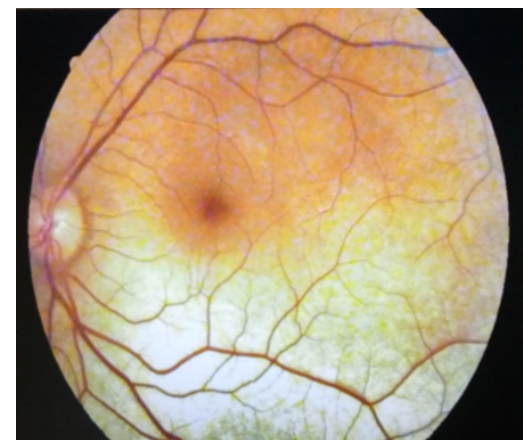
Oguchi's disease is mainly caused by a mutation. This gene codes for arrestin which is located on chromosome 2q37 described as Oguchi type 1.<sup>4,5</sup> On the other hand, mutations in GRK 1 gene coding for rhodopsin kinase is present on chromosome 13q34 called Oguchi type 2. Mutations in the SAG gene can also cause Retinitis Pigmentosa. Therefore, genetic testing must also be correlated clinically in order to establish a definitive diagnosis. The electroretinogram has a negative a-wave followed by a positive b-wave indicating bipolar cell activity. A decrease in amplitude of the b-wave



**Fig. 2:** Fundus picture of the left eye showing retina in light with grey discolouration



**Fig. 3:** Fundus picture of the right eye after three hours in the dark showing a red background



**Fig. 4:** Fundus picture of the left eye after three hours in the dark showing a normal red background

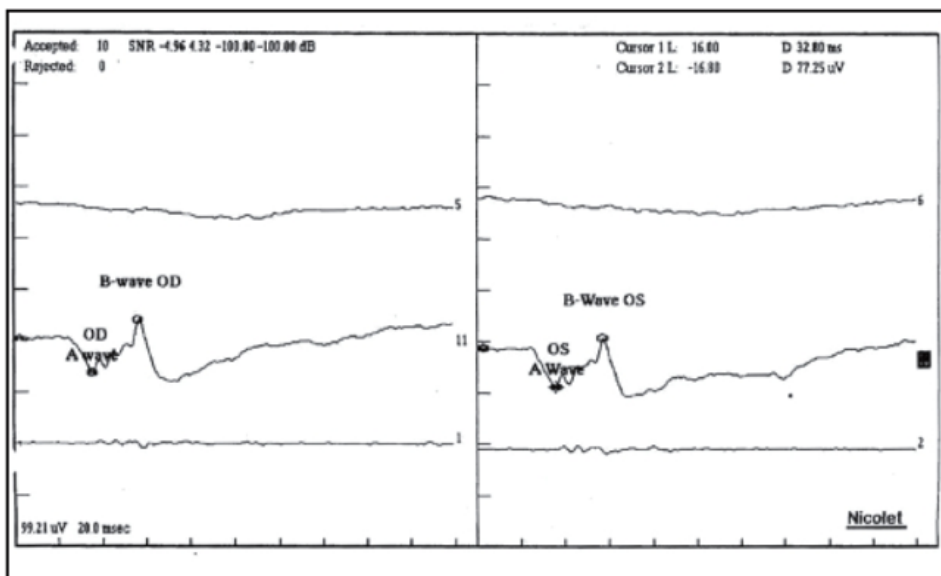


Fig. 5: Rod Electretinogram showing a decrease on the “b” wave with a normal “a” wave

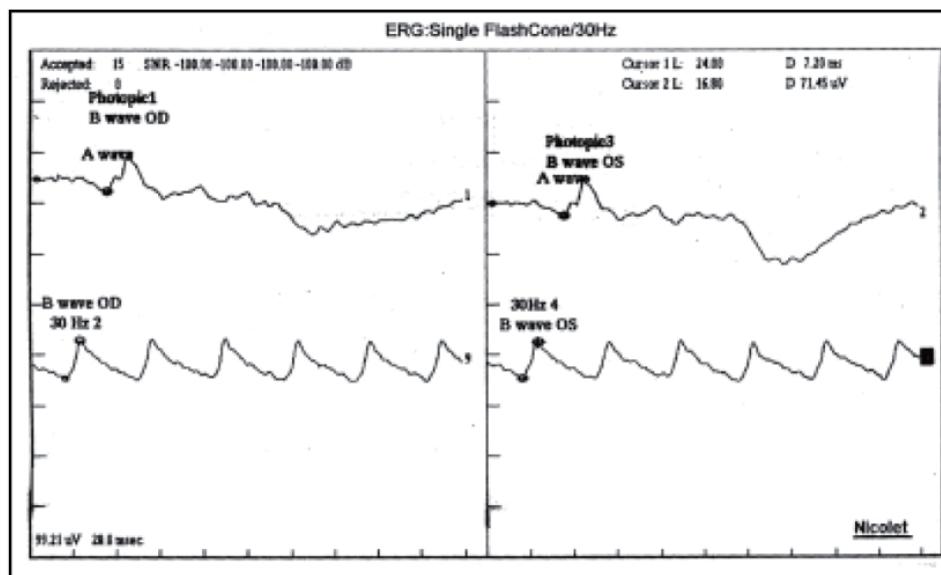


Fig. 6: The cone electretinogram has normal amplitudes in both “a” and “b” waves

in the rod electretinogram is seen in Oguchi’s disease whereas there is a decrease in b-wave amplitude on the cone electretinogram in Progressive cone dystrophy.

**4. Conclusion**

It is of primary concern to thoroughly evaluate the patient before establishing a definitive diagnosis and thereby planning a management protocol. A genetic study although confirmatory must be correlated clinically in a case of Oguchi’s disease where it is important to evaluate the fundus in both light as well as in dark.

**5. Source of Funding**

None.

**6. Conflict of Interest**

None.

**References**

1. Kalpana S, Muthayya M, Doctor PP. Oguchi disease. *J Postgrad Med.* 2006;52(2):143–4.

2. Palczewski K, Ripoli G, Detwiler PB. The influence of arrestin (48K protein) and rhodopsin kinase on visual transduction. *Neuron*. 1992;8(1):117–26. doi:10.1016/0896-6273(92)90113-r.
3. Yamamoto S, Hayashi M, Takeuchi S, Shirao Y, Kita K, Kawasaki K. Normal S cone electroretinogram b-wave in Oguchi's disease. *Br J Ophthalmol*. 1997;81(12):1043–5. doi:10.1136/bjo.81.12.1043.
4. Maw M, Kumaramanickavel G, Kar B, John S, Bridges R, Denton M. Two Indian siblings with Oguchi disease are homozygous for an arrestin mutation encoding premature termination. *Hum Mutation*. 1998;11(S1):S317–9. doi:10.1002/humu.1380110199.
5. Maw MA, John S, Jablonka S, Muller B, Kumaramanickavel G, Oehlmann R, et al. Oguchi disease: suggestion of linkage to markers on chromosome 2q. *J Med Genet*. 1995;32(5):396–8. doi:10.1136/jmg.32.5.396.

**Alhaj F Tasneem**, Professor

**Vittal I Nayak**, Professor

**Nagalakshmi Narayanaswamy**, Junior Resident

**Sara Nastain**, Junior Resident

**Cite this article:** Balakrishna N, Tasneem AF, Nayak VI, Narayanaswamy N, Nastain S. A rare case of oguchi disease exhibiting the classic Mizuo-Nakamura phenomenon. *Indian J Clin Exp Ophthalmol* 2020;6(4):660-663.

## Author biography

**Nischala Balakrishna**, Junior Resident