



Original Research Article

Teleophthalmology and its impact- An eye disease pattern analysis in central India's hot spot during COVID-19 pandemic

Teena Agrawal^{1,*}, Mahesh Agarwal²¹VR School of Excellence in Eye, Indore, Madhya Pradesh, India²Dept. of Cataract & Refractive Surgery, Shri Ganesh Netralay, Indore, Madhya Pradesh, India

ARTICLE INFO

Article history:

Received 20-05-2020

Accepted 21-05-2020

Available online 22-12-2020

Keywords:

Covid 19

Tele ophthalmology

Tele-OSD

Tele consultation

Telemedicine

ABSTRACT

Background: COVID-19 pandemic has put all of us in astonishment and concern about its management and survival of human being since there is a great risk of human to human transmission. Teleophthalmology can play a great role to overcome this situation. Earlier teleophthalmology was mainly limited to diagnostic outreach camps for diabetic eye disease mainly without treatment benefit to the patient. Now with advancement in media technology and availability of good quality smart phones, it is possible to extend scope of teleophthalmology for the treatment of superficial ailments of an eye. Our aim of the study was to analyse the eye disease pattern and impact of teleophthalmology on its management in one of the hot centre of India, i.e. Indore, during pandemic period.

Materials and Methods: This study is a retrospective, interventional data analysis of patients seen in one month of Lockdown in India, from 26th March to 25th April 2020. All the patients were given teleconsultation with the help of voice calls and still pictures; video call was used wherever it was feasible. In our study, we have divided patients in two groups, first is Tele OSD (Tele Ocular Surface Disorders) where diagnosis on 2D image or video was possible and second group were OED (Other Eye Disease) where in-person consultation was required before making diagnosis or offering treatment.

Results: We have done analysis of total 119 patients records who made a call for eye problems between 26th March 2020 to 25th April 2020. Out of 119 patients, 107 patients (89.91%) were in Tele OSD and 12 patients (10.08%) were in OED group. Telemedicine was prescribed in 103 patients (103/107, of tele OSD group- 96.26%), of which 102 patients (95.32%) showed marked improvement or are cured on follow-up. Among the Tele OSD group who received the treatment (103 patients), 79 patients (76.99%) were of conjunctivitis, varying from infectious to allergic origin who responded very well to treatment offered.

Conclusion: COVID-19 pandemic has changed the understanding of medical science. Previously telemedicine (more precisely teleophthalmology) used to be a tool for outreach patient diagnosis mainly in rural or suburb area, but now with the advancement of digital media and easy availability of smart phones, it can also be used in the management of common eye diseases, even in urban population.

© This is an open access article distributed under the terms of the Creative Commons Attribution License (<https://creativecommons.org/licenses/by/4.0/>) which permits unrestricted use, distribution, and reproduction in any medium, provided the original author and source are credited.

1. Introduction

The first case of Corona Virus was reported to WHO by China on 31 December 2019. Although the earlier research paper published in China, suggest that it has already started in the middle of the December 2019.^{1,2} They reported human-to-human transmission and case doubling

time of 7.4 days with estimated R₀ (R naught or R zero- Basic reproduction rate) to be 2.2 which suggest that every infected person has the potential to infect 2.2 healthy individuals. They also gave emphasis on identifying most effective control measures to control the community transmission. Sanche S et al.,³ suggested even very high R₀ of 5.7 in Wuhan that has resulted in very fast spread of the disease. The World Health Organization (WHO) has also advised to keep at least 1meter (3feet) distance between

* Corresponding author.

E-mail address: g_teena@hotmail.com (T. Agrawal).

you and others to reduce community transmission apart from hand and respiratory hygiene.⁴ Another article by Mandal S et al.,⁵ emphasized on home quarantine of an affected individual or traveler from affected area to reduce the disease burden.

The COVID-19 pandemic has put all of us in back foot and left us to rethink and redesign the world for future. With the advancement in technology, medical science, and increasing expectations of patient, we are more and more concentrated in, in-patient interaction and management. On 24th March 2020, when Indian Government has declared lockdown for 21 days, there were lots of concerns and confusion to the people regarding life management, financial management and most importantly how to stay safe and protected during this pandemic.⁶ We were getting many calls from our old and new patients regarding eye problems. Considering all these factors, we thought, it is prudent to go for the measures which maintain social distancing as well as help the needy patients. Telemedicine is one of the best tools in this context. Though teleophthalmology is not a new concept but it is being used for diagnosis purpose till now. Now with the new guidelines laid down by MOHFW,⁷ Government of India, it can be extended for treatment also.^{7,8} Therefore we decided to study the impact of Teleophthalmology in the diagnosis as well as management of Eye diseases in COVID-19 pandemic in one of the hot spot of India, i.e. Indore, MP.

2. Material and Methods

This is a retrospective, interventional data analysis of all the patients who consulted us for Tele-consultation through electronic media. This study was done as per guidelines given by MOHFW on 25th March 2020.⁷ All patients were diagnosed and given treatment, if required and possible to treat, through telemedicine. The diagnosis was made depending upon their chief complaints and clinical signs visible on teleconsultation. We have divided the patients in two groups

2.1. Tele-OSD group

It means the tele-ocular surface disease which can be seen on 2D image provided by the patient, during consultation, either through still picture or video. It is different from Ocular surface disease (conventional term used for conjunctiva, cornea, limbus and eye lid surface) in having been included Lacrimal sac disease and sub-conjunctival tissue disease which manifests, signs on ocular surfaces.

2.2. OED group

Other Eye Disease, where diagnosis is not possible without slit lamp examination or any other intervention.

All patients were explained to report immediately in case of any adverse reaction or worsening/no improvement. Relevant clinical history was taken including drug allergy before prescription. All patients were asked specially about cough, cold, fever, exposure to Corona patient or travel history to affected area. Further follow-up at 1 week was done to evaluate the effectiveness of treatment. The treatment was considered “Successful” when patient showed symptomatic relief or improved signs on follow-up teleconsultation.

3. Results

Table 1 summarizes demography, there were 75 Male (63.02%) and 44 Female (26.98%) enrolled in specified time. The age ranged from 5months to 80yrs with mean age 33.72yrs and median age was 31yrs.

Table 2 in our study, 107 patients (89.77%) were in tele-OSD and 12 patients (10.08%) were in OED group. We prescribed treatment to 103 patients (86.55%) in tele OSD group and 2 patients in OED (1.68%), of which 102 in tele OSD and 2 patients in OED group were considered as successful treatment. 1 case of bilateral conjunctivitis in tele-OSD group developed blurring of vision during treatment and was called for further in-patient consultation.

The 2 patients (1.64%) of OED group have been diagnosed as Asthenopia and given lubricant eye drops along with advice to reduce screen time (use of mobile and TV) thereby treated successfully.

No treatment was possible in 4 patients (3.36%) in tele-OSD and 10 patients (8.40%) in OED group as they required intervention for diagnosis and treatment.

Table 3 summarizes the distribution of tele-OSD, with maximum number 39 (32.77%) of Infectious conjunctivitis (SAC) as a single disease followed by Seasonal allergic conjunctivitis, 38 cases (31.93%). If we calculate the total number of patients of Conjunctivitis, including Infectious, angular and allergic, from 1-5 in Table 3, the number rises to 79 (66.38%) which can easily be treated with the help of teleophthalmology.

Table 4 summarizes the distribution of OSD, with total count of 12 patients. Only 2 patients of Asthenopia (Provisional diagnosis based on age, young, and history given by patient and declaration of normal vision for distance and near, although we have included the patient in this group as dilated refraction was needed for making final diagnosis of asthenopia) received treatment and benefitted.

Table 1: Demography of study subject

Age	Age range	5 Months to 80 yrs
	Mean age	
	Median age	31
Sex	Male	75
	Female	44

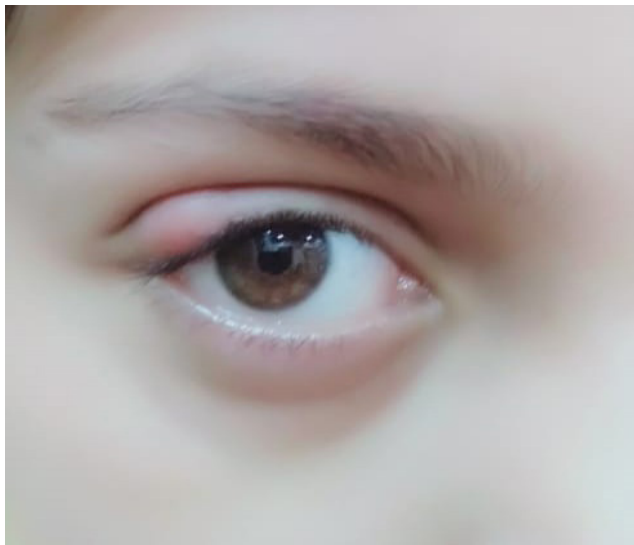

Fig. 1: Chalazion with Inflammation

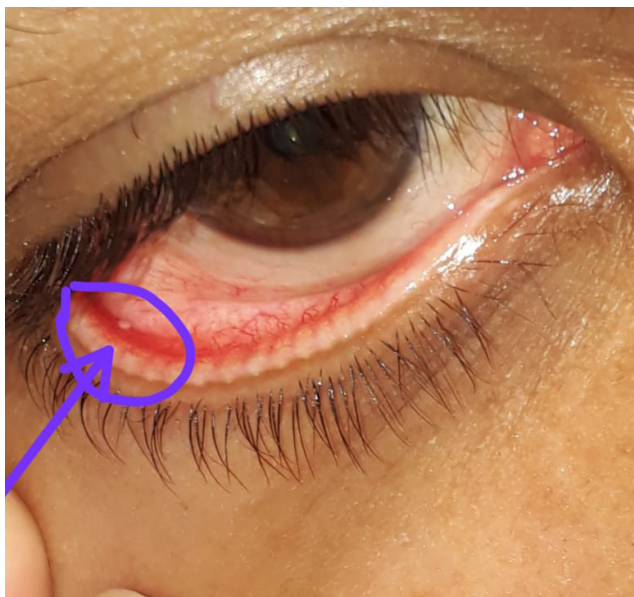

Fig. 2: Concretion

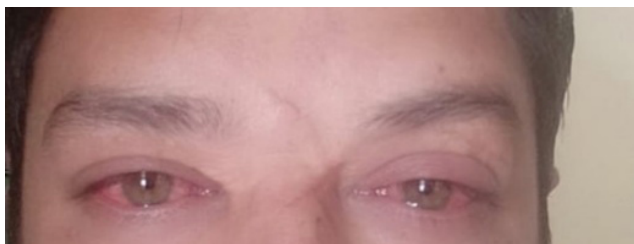


Fig. 3: Conjunctivitis

Table 2: Distribution according to treatment

Diagnosis	Treatment with result		Total
	Successful	Intervention required	
Tele OSD	102	5	107
OED	2	10	12
Total	104	15	119

Table 3: Tele OSD summary

Diagnosis	Number of patients/119	Prevalence in % (total 119 patients)
INF. Conjunctivitis U/L #	19	15.96
INF. Conjunctivitis B/L# *	9	7.56
Conjunctivitis angular #	11	9.24
Seasonal allergic conjunctivitis #	38	31.93
Vernal keratoconjunctivitis #	2	1.62
HZO	3	2.52
Dry eye **	6	5.04
Subconju hhge	5	4.2
Episcleritis	1	0.84
NLD block	2	1.62
Chalazion	5	4.2
Blepharitis	1	0.84
Suture granuloma	1	0.84
Concretions	1	0.84
Corneal ulcer	1	0.84
CHR Dacryocystitis	1	0.84
Squint	1	0.84
Total	107/119	89.77

* One patient developed blurring of vision- suspect of Adenoviral conjunctivitis. Needed In-patient consultation for SLE

Diagnosis was made on typical signs and symptoms. Infective conjunctivitis- Redness, watering with/without discharge, Allergic Conjunctivitis- Itching as predominant symptoms, VKC- typical muddy conjunctiva with intense itching and watering.

** Dry Eye- Burning sensation, foreign body sensation with itching.

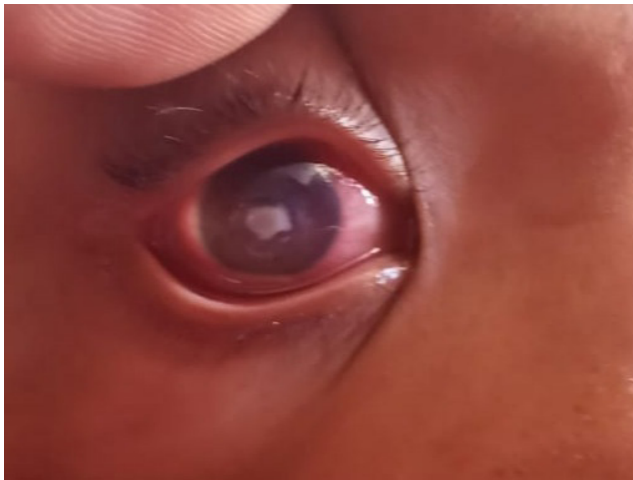4. Discussion

In 1 month duration, we have registered total 119 patients whose demographic data is already discussed. In our study we found 39 cases (32.77%) of infective conjunctivitis (clinically appearing) and we have given them broad spectrum antibiotics (Moxifloxacin 0.3% / Gatifloxacin 0.3% eye drop) and Carboxymethylcellulose eye drop 0.5% eye drops 4 times a day each and antibiotic eye ointment wherever required. We have given weak steroids (loteprednol 0.5%) as supportive treatment where we

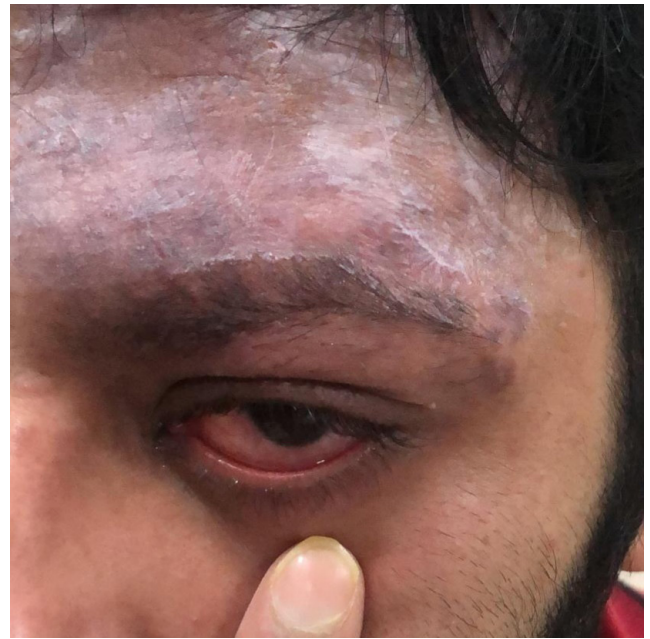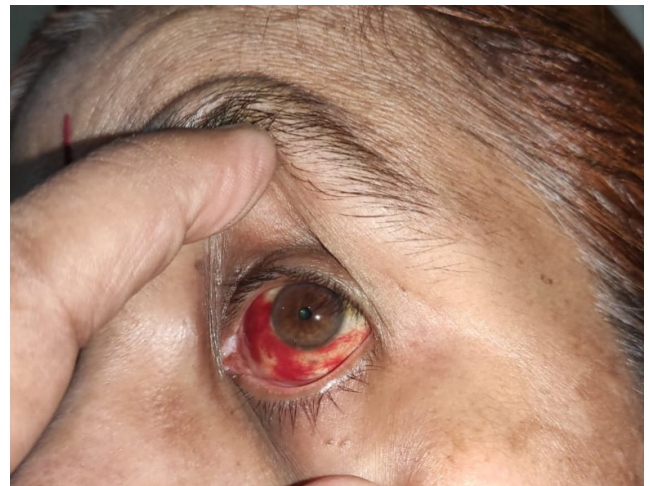Table 4: Other eye disease(OED)

Diagnosis	Number of patients/119	Prevalence in % (total 119 patients)
Refractive error/presbyopia	1	0.84
Cataract	2	1.68
Pseudophakia with PCO	1	0.84
Optic neuropathy	1	0.84
Glaucoma	2	1.68
Floater	2	1.68
ARM	1	0.84
Asthenopia*	2	1.68
Total	12	10.07

* 2 Patients were using electronic gadgets excessively. Condition improved after counseling.

**Fig. 4:** Hypopyon corneal ulcer

suspected viral or allergic origin. Holland APA et al.⁹ also find that combination of antibiotics with steroids for short term (< 2 weeks) in viral conjunctivitis could be effective and well tolerated.⁸ Azari AA et al. has shown in their meta-analysis that among infectious conjunctivitis, nonherpetic viral conjunctivitis is the most common cause followed by bacterial conjunctivitis.¹⁰ We have avoided steroids in conjunctivitis with muco-purulent discharge. There is a well elaborated article by Shetty R et al.,¹¹ about understanding and management approach of conjunctivitis by an ophthalmologist, following CODE protocol in in-patient consultation. They also emphasized to make balance between minimizing potential risk of transmission and timely management of Conjunctivitis patient. They also pointed out in CODE protocol that all patients of conjunctivitis don't need slit lamp evaluation and epidemic conjunctivitis patient can be disposed off after torch light examination.

**Fig. 5:** HZO conjunctivitis**Fig. 6:** Subconjunctival haemorrhage

AAO (American Academy of Ophthalmology) has put forth important references in relation to conjunctivitis where SARS-CoV-2 RNA was isolated from ocular secretions of COVID-19 positive patients which further warn the possibility of disease transmission.¹² WHO (World Health Organization) has also notified occupational hazards to health worker due to pathogen exposure, long working hours, psychological distress etc.¹³ In this regard we think that teleophthalmology has played a significant role in transmission of COVID-19.

In our study we found significant number of Angular conjunctivitis, which is due to *Morax-Axenfield diplobacill*.¹⁴ We have successfully treated them with

moxifloxacin 0.5% with loteprednol 0.5% combination. There was a very interesting article by Schwrtz B et al.,¹⁵ which points out make-up cosmetics sharing as the cause of angular conjunctivitis outbreak in a boarding school, though we have not noted any remarks regarding this in our study.

Allergic conjunctivitis, including seasonal allergic conjunctivitis and vernal keratoconjunctivitis contributes approximately 40% cases worldwide but they are largely unreported as per Azari AA et al.,¹⁰ In our study we found 40 cases (33.61%) of allergic conjunctivitis which was successfully treated with Olopatadine (0.1%), loteprednol 0.5% eye drop along with lubricating drops in variable combinations. None of the patient reported any adverse reaction or worsening of disease. Although long term use of loteprednol (0.5%) was discouraged and patient was advised to continue with olopatadine (0.1%) for maintenance therapy, if needed.

We have also noted diseases other than conjunctivitis in tele-OSD category (Table 3) and were given symptomatic treatment. There was one case of corneal ulcer from remote area, came to us through local general practitioner, was also given primary treatment and referred to nearby eye specialist for further management on emergency basis. The other condition where teleophthalmology was not effective in treating were, concretions, squint, and chronic dacryocystitis, all needs intervention.

In OED group, we have treated only 2 patients (1.64%) of Asthenopia of middle age group with lubricating eye drops and advice on reduced use of electronic gadgets. The diagnosis was made on typical signs and symptoms of asthenopia, like eye fatigue more in evening, more after use of mobile and TV.

There are two modes of transmission of COVID-19 from suspect or infected to healthcare personal and vice versa. First is direct transmission from body fluid like tears of infected or carrier of COVID-19 to healthy individual and second is through indirect transmission by not following social distancing and healthy hand and respiratory hygiene.

Another important mode of transmission is indirect transmission where social distancing and proper hand and respiratory hygiene is not maintained.

5. Conclusion

Cosidering all these factors we advocate use of Teleophthalmology not only for diagnosis but also for management, keeping in mind its guidelines. Teleophthalmology gives promising scope and result in most of the cases of tele-OSD for diagnosis as well as management. It is of great help to the society to reduce disease burden, especially in the pandemic era.

6. Limitations

The retrospective study has its own limitations, though we tried to reduce it. Also this is a study done in a particular

period of lockdown, its efficiency and impact need to be further evaluated in normal days.

7. Source of Funding

None.

8. Conflict of Interest

The author(s) declare(s) that there is no conflict of interest regarding the publication of this article.

References

1. Li Q, Guan X, Wu P. Early Transmission Dynamics in Wuhan, China, of Novel Coronavirus-Infected Pneumonia. *N Engl J Med.* 2020;382(13):1199–1207.
2. Maurya RP. COVID-19 and Ophthalmologists. *Indian J Clin Exp Ophthalmol.* 2020;6(3):312–4. doi:10.18231/ij.ijceo.2020.068.
3. Sanche S, Lin YT, Xu C, Romero-Severson E, Hengartner N, Ke R. High contagiousness and rapid spread of severe acute respiratory syndrome coronavirus 2. *Emerg Infect Dis.* 2020;26(7). doi:10.3201/eid2607.200282.
4. Available from: <https://www.who.int/news-room/q-a-detail/q-a-coronaviruses>.
5. Mandal S, Bhatnagar T, Arinaminpathy N, Agarwal A, Chowdhury A, Murhekar M, et al. Prudent public health intervention strategies to control the coronavirus disease 2019 transmission in India: A mathematical model-based approach. *Indian J Med Res.* 2020;151(2):190–9.
6. Maurya RP. Ocular oncology practice during SARC-CoV-19 related lockdown. *Ind J Clin Exp Ophth.* 2020;6(2):155–8.
7. Available from: <https://www.mohfw.gov.in/pdf/Telemedicine.pdf>.
8. Khanna RC. Ocular surface disorders. *Community Eye Health.* 2017;30(99):1–2.
9. Holland EJ, Fingeret M, Mah FS. Use of Topical Steroids in Conjunctivitis: A Review of the Evidence. *Cornea.* 2019;38(8):1062–7. doi:10.1097/ICO.0000000000001982..
10. Azari AA, Barney NP. Conjunctivitis: a systematic review of diagnosis and treatment. *JAMA.* 2013;311(1):1721–9. doi:10.1001/jama.2013.280318.
11. Shetty R, D'Souza S, Lalgudi VG. What ophthalmologists should know about conjunctivitis in the COVID-19 pandemic? *Indian J Ophthalmol.* 2020;68(5):683–7. doi:10.4103/ijjo.ijjo_869_20.
12. Available from: <https://www.aao.org/headline/alert-important-coronavirus-context>.
13. Available from: <https://www.who.int/emergencies/diseases/novel-coronavirus-2019/technical-guidance/health-workers>.
14. Wood M. Conjunctivitis: diagnosis and management. *Community Eye Health.* 1999;12(30):19–20.
15. Schwartz B, Harrison LH, Motter JS, Motter RN, Hightower AW, Broome CV. Investigation of an Outbreak of Moraxella Conjunctivitis at a Navajo Boarding School. *Am J Ophthalmol.* 1989;107(4):341–7.

Author biography

Teena Agrawal, Associate Professor

Mahesh Agarwal, Director & Consultant

Cite this article: Agrawal T, Agarwal M. Teleophthalmology and its impact- An eye disease pattern analysis in central India's hot spot during COVID-19 pandemic. *Indian J Clin Exp Ophthalmol* 2020;6(4):522-526.