



Original Research Article

Etiology of vitreous haemorrhage in a tertiary eye care centre of north India

Jitender Phogat¹, Monika Dahiya^{1,*}, Manisha Nada¹, S V Singh¹, Latika Pandey¹, Arjun¹¹Dept. of Ophthalmology, RIO, PGIMS, Rohtak, Haryana, India

ARTICLE INFO

Article history:

Received 11-04-2020

Accepted 09-05-2020

Available online 22-12-2020

Keywords:

Diabetic retinopathy

Ocular trauma

Vasculitis

Vitreous haemorrhage

ABSTRACT

Aim: To study the etiology of vitreous haemorrhage in a tertiary eye care hospital of North India.**Materials and Methods:** A hospital based cross-sectional study was done in RIO, PGIMS Rohtak over a period of over 2 years which included 200 patients presenting with vitreous haemorrhage. All patients were evaluated in detail to establish the etiology of vitreous haemorrhage. The data was analyzed using microsoft excel and SPSS 17.0 software.**Result:** A total of 200 patient presenting with vitreous haemorrhage involving one or both eyes were evaluated. The mean age of patients was found to be 47.40±19.6 years with a range of 6 months to 85 years. Only 24% cases had bilateral involvement. Male were found to be affected more commonly than females with M:F ratio of 2:1. In more than 85% cases, proliferative diabetic retinopathy, retinal vasculitis, branch retinal vein occlusion, central retinal vein occlusion, retinal tear, rhegmatogenous retinal detachment and ocular trauma was the underlying etiology.**Conclusion:** Proliferative diabetic retinopathy, branch retinal vein occlusion, posterior vitreous detachment with retinal tear are most common causes of vitreous haemorrhage in elderly patients while in young adults, retinal vasculitis is most common cause. While in children, trauma is found to be the most common etiology of vitreous haemorrhage.© This is an open access article distributed under the terms of the Creative Commons Attribution License (<https://creativecommons.org/licenses/by/4.0/>) which permits unrestricted use, distribution, and reproduction in any medium, provided the original author and source are credited.

1. Introduction

Vitreous humour is a transparent colourless gel constituting about 80% (4ml) of ocular volume. Vitreous haemorrhage is the extravasation of blood into the vitreous body which is outlined by internal limiting membrane of retina posteriorly and laterally by non-pigmented epithelium of ciliary body and anteriorly by posterior lens capsule. Vitreous haemorrhage is a common cause of sudden painless loss of vision which usually present with sudden appearance of floaters, smoke signals, perception of red or black shadows and cobwebs. If flashes of light precede these symptoms, then posterior vitreous detachment, retinal detachment or retinal break should be considered.¹ Vision loss in cases of vitreous haemorrhage depends on the density

of haemorrhage and even 10 microliters of blood can reduce vision to hand movement.²

Pathophysiological mechanisms of vitreous haemorrhage:

1. The main mechanism of vitreous haemorrhage is due to retinal vascular disorders which cause retinal ischaemia leading to release of angiogenic factors such as endothelial growth factor which stimulate formation of new blood vessels to grow from the disc and the retina.³ These newly formed blood vessels are very fragile, which bleeds easily due to mild vitreous traction. The retinal disorders which cause neovascularisation secondary to retinal ischemia are proliferative diabetic retinopathy, ischaemic retinal vein occlusion, Eales' disease, sickle cell retinopathy and familial exudative vitreo-retinopathy (FEVR).

* Corresponding author.

E-mail address: drmonika2410@gmail.com (M. Dahiya).

2. Rupture of retinal arteriole macroaneurysm due to systemic hypertension, haemorrhage from a retinal angioma and congenital peripapillary arterial loops can cause vitreous haemorrhage.
3. During posterior vitreous detachment (PVD), normal retinal vessel can rupture due to traction exerted on it. PVD can be spontaneous or secondary to blunt ocular trauma. The same mechanism is also responsible for vitreous haemorrhage secondary to retinal tears, retinoschisis, Terson's syndrome and Valsalva retinopathy.
4. Vitreous haemorrhage can also occur by the breakthrough of sub retinal haemorrhage which dissects through the retina without any associated retinal detachment. Most common cause of subretinal haemorrhage is wet ARMD⁴ while choroidal malignant melanoma and idiopathic polypoidal choroidal vasculopathy (PCV) are rarely encountered.⁵
5. The vitreous haemorrhage can resolve spontaneously or persist with time in due course.⁶ Spontaneous resolution of vitreous haemorrhage is a slow process and occur in those conditions which do not have any tendency for recurrent bleeding.⁷ Complications of long standing vitreous haemorrhage are haemosiderosis bulbi, retinal damage, glial and fibrovascular proliferation, ochre membrane formation and glaucoma. Glaucoma is a common complication of non-resolving long standing vitreous haemorrhage which can be ghost cell, haemolytic or hemosiderotic glaucoma.

2. Materials and Methods

A hospital based cross-sectional study was conducted in vitreous haemorrhage patients in Regional institute of ophthalmology, PGIMS Rohtak. They were enrolled in our study after taking an informed consent. After taking a detailed history, ocular examination was done in systemic way in every patient and best corrected visual acuity (BCVA), relative afferent pupillary defect (RAPD), NVI (Neovascularisation of Iris) and NVA (Neovascularisation of Angle) were noted. Intraocular pressure was measured with Goldman's Applanation Tonometer (GAT) to rule out secondary glaucoma. Detailed fundus examination of both eyes was done. USG B scan was done for posterior segment evaluation in hazy media to look for retinal tears, tumor or retinal detachment. FFA was done in clear media to look for leaky vessels and underlying etiology. Laboratory investigations done in every patient were: Blood pressure, Blood sugar including HbA1c, Lipid profile, Montoux test, Hb, Bleeding time(BT), Clotting time(CT), ESR, ECG, Chest X-Ray, Echocardiography.

All data was collected and analyzed using microsoft excel and SPSS 17.0 software.

3. Results

Out of 200 patients of vitreous haemorrhage, 66% were male and 34% were female with a M:F ratio of 2:1. The mean age of patients was 47.4±19.6 years with a range of 6 months to 85 years. The disease was bilateral in 24% of patients.

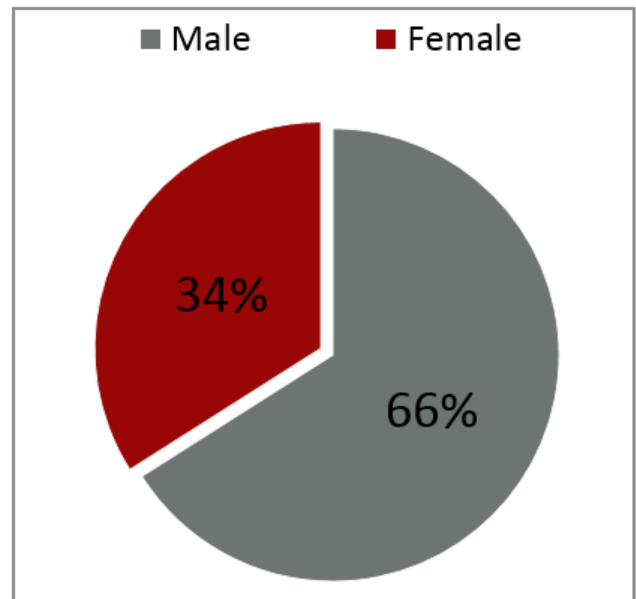


Fig. 1: Showing male preponderance and M:F Ratio of 2:1

Most common presenting complaint of VH in our study was sudden loss of vision in 47% cases, slowly progressive loss of vision in 29% and floaters in 24% cases. Systemic complaints were observed in 7% cases out of which 6% had headache and 1% of patients had fever.

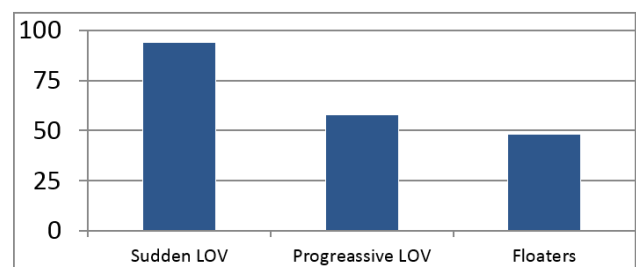


Fig. 2: Presenting symptom of vitreous haemorrhage

In our study, 82% patients had associated systemic illness and the most common systemic illness associated was found to be diabetes (38%), hypertension (18%) and hyperlipidemia (16%). 10% patients had both diabetes and hypertension while 18% patients had no associated systemic disease. History of smoking was present in 40% of patients.

In our study, most common cause of VH in >50 year old patients was PDR while in young age group, most common

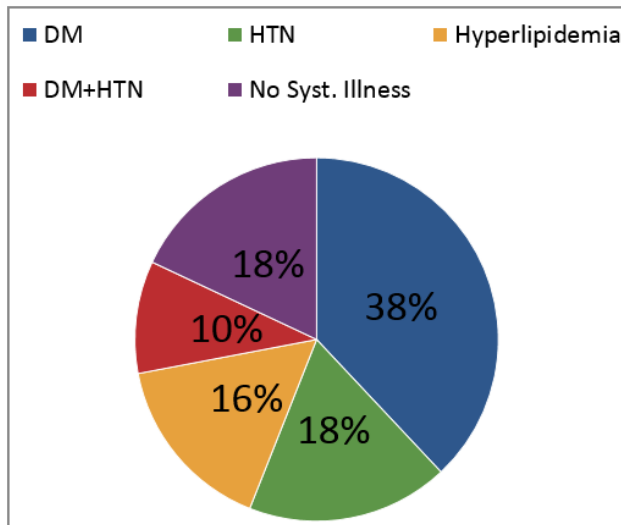


Fig. 3: Association of VH with various systemic disease

cause was retinal vasculitis followed by ocular trauma. Visual acuity of patients at the time of presentation varied from mild decrease in vision to complete loss of vision. Majority patients (56%) were clinically blind at the time of presentation, 26% had marked visual impairment while only 18% patients had mild decrease or near normal visual acuity at the time of presentation.

4. Discussion

This study was conducted with the objective of determining the etiology of vitreous haemorrhage in a tertiary eye care centre of North India. In our study, 66% were males and 34% were females with a M:F ratio of 2:1. Similar findings were reported by Lean JG et al⁸ in their study where males constituted 55% of cases of vitreous haemorrhage. In a population-based prevalence study of eye diseases in 40 years or older in South India, slightly higher prevalence of any vitreo-retinal disorder including vitreous haemorrhage was reported in males.⁹ A high male predominance of vitreous haemorrhage in our study is attributed to high prevalence of Eales' disease in males and increased risk of ocular trauma due to more outdoor activities.

We found PDR to be the most common cause of VH followed by retinal vasculitis (Eales' disease). Retinal vasculitis was the most important etiology in younger age group of 20-40 yrs in contrast to western studies. Das T et al.,¹⁰ reported similar findings of male predominance (97.6%) and younger age group in Indian subcontinent in patients of Eales' disease. Higher prevalence of retinal vasculitis or Eales' disease is contributed to higher prevalence of tuberculosis and more positivity of Montoux test in India than western countries. Nagpal PN et al.¹¹ and Thompson JT¹² had also found that Eales' disease most commonly affects healthy young male adults (97.6%).

Incidence of vitreous haemorrhage increases significantly with age because diabetic retinopathy, vascular occlusion, vitreous degeneration, retinal detachment, hypertension and age related macular degeneration are more common in older population. In our study, 72% patient were above the age of 50 years and most of younger patients were having vitreous haemorrhage secondary to retinal vasculitis (Eales' disease) and ocular trauma.

The majority of patients (76%) of vitreous haemorrhage have unilateral ocular involvement. In a study conducted by Spirn MJ et al. in children with vitreous haemorrhage, unilateral involvement was seen in 90.5% of patients and trauma as a common cause of vitreous haemorrhage in children. In our study, trauma including both closed and open globe injury cause vitreous haemorrhage in 12% of patients in which closed globe (8%) injury was more common than open globe injury (4%).

Proliferative diabetic retinopathy, retinal vasculitis, ocular injury, branch retinal vein occlusion, posterior vitreous detachment and retinal detachment were most common causes of vitreous haemorrhage in our study, while in a study by Butner and McPherson et al.,¹³ four most common cause of spontaneous vitreous haemorrhage were diabetic retinopathy (34.1%), retinal break without retinal detachment (22.4%), rhegmatogenous retinal detachment (14.9%) and retinal vein occlusion(13%). Dana MR et al¹⁴ in their study found proliferative diabetic retinopathy (35.2%), ocular trauma (12%), retinal vein occlusion (7.4%) and retinal tear without a detachment(7%) as most common cause of vitreous haemorrhage. Winslow RL and Taylor BC¹⁵ found proliferative diabetic retinopathy (54%), retinal tear (12.1%), posterior vitreous detachment (12%) and vein occlusion(10.4%) as the important cause of vitreous haemorrhage. Diabetes and hypertension are most commonly associated systemic association with vitreous haemorrhage while deranged lipid profile exaggerate retinal ischaemia in diabetic retinopathy. These factors are also risk factors for retinal vein occlusion and rupture of retinal macroaneurysm.

In our study, out of less common causes of vitreous haemorrhage, 4 patients (2%) had vitreous haemorrhage secondary to tractional retinal detachment, in which two eyes had complication of Eales' disease and two eyes had proliferative diabetic retinopathy while 5 patients (2.5%) had vitreous haemorrhage secondary to choroidal new vessels in ARMD. Other less common causes of vitreous haemorrhage were found to be leukaemia, posterior uveitis, Terson's syndrome, serpiginous choroiditis and complication of laser in diabetic retinopathy.

5. Conclusion

Vitreous haemorrhage is a common cause of sudden painless loss of vision. Unilateral involvement is more common than bilateral. The most common etiology of

Table 1: Etiology of vitreous haemorrhage

S. No.	Diagnosis	Total no of patients	% of patients
1.	Proliferative diabetic retinopathy	76	38%
2	Retinal vasculitis (Eales' disease)	32	16%
3	Branch retinal vein occlusion	14	7%
4	Closed globe injury	16	8%
5	Posterior vitreous detachment	14	7%
6	Rhegmatogenous retinal detachment	8	4%
7	Open globe injury	8	4%
8	Central retinal vein occlusion	7	3.5%
9	Age related macular degeneration	5	2.5%
10	Tractional retinal detachment	4	2%
11	Complication of laser (PRP) in diabetic retinopathy	3	1.5%
12	Leukemia and blood dyscrasia	3	1.5%
13	Serpiginous choroiditis	2	1%
14	Terson's syndrome	2	1%
15	Posterior uveitis	2	1%
16	Macroaneurysm of retinal vessel	2	1%
17	Idiopathic	2	1%

vitreous haemorrhage is retinal vasculitis (Eales' disease) and ocular trauma in younger age group while proliferative diabetic retinopathy, retinal vein occlusion and posterior vitreous detachment with retinal tear in older population. The commonest age of presentation is 20-30 years with male preponderance. Diabetes and hypertension were found to be most commonly associated systemic illness with vitreous haemorrhage.

6. Source of Funding

None.

7. Conflict of Interest

The authors declare that there is no conflict of interest.

References

- Vitreous haemorrhage in emergency medicine. Available from: <http://emedicine.medscape.com/article/799242>.
- Spraul CW, Grossniklaus HE. Vitreous hemorrhage. *Surv Ophthalmol.* 1997;42(1):38–9. doi:10.1016/s0039-6257(97)84041-6.
- Jampol LM, Ebronn DA, Goldbaum MH. Peripheral proliferative retinopathies: An update on angiogenesis, etiologies and management. *Surv Ophthalmol.* 1991;38:519–40.
- Baba F, Jarret WH, Harbin TH, Fine SL, Michels RG, Schachaf AP. Massive haemorrhages complicating age related macular degeneration: Clinicopathological correlation and role of anticoagulants. *Ophthalmol.* 1986;93:1581–92.
- Yannouzzi LA, Ciardella, Spaide RF, Rabt RF, Freund KB, Orlack DA. The expanding clinical spectrum of idiopathic polypoidal choroidal vasculopathy. *Arch Ophthalmol.* 1997;115:473–85.
- Forrester JV. The Pathology of Vitreous Hemorrhage. *Arch Ophthalmol.* 1979;97(12):2368–8. doi:10.1001/archophth.1979.01020020584018.
- Ziemianski MC, McMeel JW, Franks EP. Natural History of Vitreous Hemorrhage in Diabetic Retinopathy. *Ophthalmol.* 1980;87(4):306–12. doi:10.1016/s0161-6420(80)35232-9.
- Morse PH, Aminlari A. Spontaneous vitreous haemorrhage and its complications. *Arch Ophthalmol.* 1974;92:297–8.
- Lincoff H, Wolkstein M. Acute Vitreous Haemorrhage: A clinical report. *Br J Ophthalmol.* 1986;60:454–8.
- Saxena S, Jalali S, Verma L. Management of vitreous haemorrhage. *Indian J Ophthalmol.* 2003;51(2):189–96.
- Lean I, Gregor Z. The acute vitreous haemorrhage. *Br J Ophthalmol.* 1982;64:469–71.
- Nirmalan PK. Prevalence of Vitreoretinal Disorders in a Rural Population of Southern India. *Arch Ophthalmol.* 2004;122(4):581. doi:10.1001/archophth.122.4.581.
- Thompson JT, Stoessel KM. An Analysis of the Effect of Intravitreal Blood on Visual Acuity. *Am J Ophthalmol.* 1987;104(4):353–7. doi:10.1016/0002-9394(87)90224-8.
- Zhang X, Saaddine JB, Chou CF, Cotch MF, Chang YJ, Geiss LS. Prevalence of diabetic retinopathy in United States. *IAMA.* 2005;304(6):649–56.
- Spring MI, Lynn MJ, Hubard GV. Vitreous haemorrhage in children. *Ophthalmol.* 2006;113:848–52.

Author biography

Jitender Phogat, Associate Professor

Monika Dahiya, Senior Resident

Manisha Nada, Professor

S V Singh, Senior Professor & HOD

Latika Pandey, Resident

Arjun, Resident

Cite this article: Phogat J, Dahiya M, Nada M, Singh SV, Pandey L, Arjun. Etiology of vitreous haemorrhage in a tertiary eye care centre of north India. *Indian J Clin Exp Ophthalmol* 2020;6(4):568-571.