



Original Research Article

Visual outcome and intraocular pressure control after cataract surgery in patients with lens induced glaucoma: A longitudinal study at a tertiary care centre

Mohite Uday Sheshrao¹, Gandhi Niyati Pankaj^{1,*}

¹Dept. of Ophthalmology, Government Medical College and Hospital, Latur, Maharashtra, India



ARTICLE INFO

Article history:

Received 27-03-2020

Accepted 30-03-2020

Available online 30-09-2020

Keywords:

Intraocular pressure

Implantation

Lens induced glaucoma

Visual acuity

ABSTRACT

Context: Lens induced glaucoma due to hypermature cataract is an important cause of secondary glaucoma. Lens induced glaucoma is a common cause of ocular morbidity.

Aims: To determine the visual outcome and study the intraocular pressure control post cataract extraction in patients with lens induced glaucoma.

Materials and Methods: This prospective study was done in patients who underwent cataract surgery with lens induced glaucoma visiting the Tertiary Care Centre in Latur, Maharashtra. Fifty cases of lens induced glaucoma satisfying the inclusion criteria were selected & followed up from the time of admission & surgery till 4 weeks post-operatively and factors influencing the final visual outcome were analysed.

Statistical Analysis used: Chi-Square test was used for comparison & p-value < 0.05 was considered statistically significant.

Results: All the cases included in the study had raised intraocular pressure on admission and 48% patients had intraocular pressure between 30-40 mmHg. It was found that good visual acuity can be achieved in LIG presenting within 2 weeks and IOP less than 35mmHg. Forty four percent had a best corrected visual acuity of 6/6-6/12 post operatively. Cases (100%) having abnormal intraocular pressure on admission had normal intraocular pressure after cataract extraction. Positive correlation between duration of symptoms and pre op IOP to the final best corrected visual acuity was found.

Conclusions: Awareness, early diagnosis and efficient medical management can control IOP and inflammation, with meticulous surgery and IOL implantation.

Key Messages: Lens induced glaucoma due to hyper mature cataract is an important cause of secondary glaucoma in the developing world. The uptake of eye care services by the rural community has also been suboptimal in countries like India where lens induced glaucoma is a common cause of ocular morbidity.

© 2020 Published by Innovative Publication. This is an open access article under the CC BY-NC license (<https://creativecommons.org/licenses/by-nc/4.0/>)

1. Introduction

Cataract and glaucoma are the leading causes of blindness throughout the world. The foremost cause of blindness in India being cataract, accounts for 62.4%.¹

Glaucoma is a chronic, progressive optic neuropathy caused by a group of ocular conditions, which may lead to damage of the optic nerve with loss of visual function and is known to be the most common risk factor known.² Lens Induced Glaucoma (LIG), one of the commonest causes of secondary glaucoma due to

senile cortical cataracts, it becomes mandatory to recognize and manage it at the earliest to prevent blindness.³ Cataract is annually increasing at an estimated rate of 3.8million in the country,⁴ the occurrence of lens induced glaucoma in India is rapidly increasing.^{5,6} Timely intervention is important in achieving good results as the pre-operative and post-operative morbidity is more common in eyes with lens induced glaucoma when compared with a simple uncomplicated cataract eventually affecting the visual outcome and prognosis. Phacoemulsification, small incision cataract surgery (SICS) with PCIOL or extracapsular cataract extraction (ECCE) with PCIOL with or without iridectomy/ trabeculectomy are different

* Corresponding author.

E-mail address: niyug.92@gmail.com (G. N. Pankaj).

modes of treatment used depending on the mechanism by which glaucoma occurs. This study emphasizes the importance of patient education, early diagnosis, timely management of all the cases of cataract before they become hyper mature and land up into lens induced glaucoma. Of all the types, phacomorphic and phacolytic glaucoma are very challenging and often present with poor visual outcome. Public health education and awareness regarding early identification is important. Health workers should encourage patients with cataract to seek early treatment for better prognosis.⁴ In order to evaluate this information, the present study was attempted to assess the visual outcome and intraocular pressure (IOP) control after cataract surgery in lens induced glaucoma in patients attending the tertiary care hospital.

2. Materials and Methods

This is a prospective study done on patients with lens induced glaucoma visiting the tertiary care centre in Latur district of Maharashtra. The study was conducted for duration of one year (Jan 2018 to Jan 2019). Fifty cases of lens induced glaucoma satisfying the inclusion criteria presented to the OPD during the study period and were included in the present study. All the patients with lens induced glaucoma irrespective of the age and sex were included. Various types of lens induced glaucomas, including; Phacomorphic glaucoma, phacolytic glaucoma, Phacotoxic uveitis/lens particle glaucoma, Phacoanaphylactic uveitis with secondary glaucoma and Glaucoma secondary to ectopia lentis were included. Any glaucoma other than lens induced glaucoma, like; cataract with pseudoexfoliation syndrome and complicated cataracts, pre-existing corneal dystrophies and corneal opacities with cataract were excluded from the study.

All the patients included in the study were clinically diagnosed and admitted. Socio-demographic details were noted. Detailed history pertaining to the causation of glaucoma in the affected eye was ascertained. Duration and progress of diminution of vision, onset of pain, redness, watering and photophobia in the affected eye and associated symptoms such as headache, nausea and vomiting were taken into consideration. Any history of ocular trauma or previous surgery in the eye was enquired; physical examination of all these patients included a thorough examination of their general and systemic conditions. All the patients underwent a pre-anaesthetic evaluation. Examination of the globe and adnexa were conducted to assist diagnosis and examine the features that affect final visual outcome.

Following local interventions/ investigations were conducted on the subjects,

1. Visual acuity – In the affected eye vision was recorded and retinal function test was done by assessing the

perception of light and projection of rays. Snellen's chart was used for the other eye.

2. Refraction using auto refractometry.
3. Slit lamp bio-microscope examination.
4. Direct ophthalmoscopy of the other eye.
5. Indirect ophthalmoscopy of the other eye.
6. Applanation tonometer/ Schiotz tonometer - Intraocular Pressure
7. Scan as the posterior segment visibility is lost in hypermature cataract.
8. A- Scan biometer.
9. Sac Syringing.

Systemic tests include

1. CBC, FBS and PPBS tests,
2. LFT, KFT,
3. HIV and HBsAg tests,
4. ECG, Blood pressure recording by Sphygmomanometer.

Prior to surgery, intra ocular pressure was recorded in all patients and if the IOP was raised Inj. Mannitol 20%, 100 ml IV was given at the rate of 50 drops/min over a period of 30 min along with oral Tab. Acetazolamide 500mg stat 250 mg QID maintenance was administered.

Pre-operatively pupils were dilated using combination of Tropicacyl (0.08%) and Phenylephrine (5%) eyedrops, instilled every 15min until the pupils dilated. 1 drop of Flurbiprofen (0.03%) eyedrops were instilled 3 times preoperatively to prevent intraoperative miosis and post operative cystoid macular oedema.

After obtaining written informed consent about the ocular morbidity, intra operative difficulties, complications and explanation of relatively guarded post-operative prognosis, the patients of lens induced glaucoma were subjected to small incision cataract surgery with/ without trabeculectomy. Posterior chamber intraocular lens implantation was conducted under local anaesthesia. Suitable modifications in the surgical steps were made.

Postoperative management started with eye pad removal the next day. Detailed slit lamp evaluation was done to check for post-operative complications if any. Vision with pin hole was tested on the first day. All the patients were given topical antibiotic with steroid drops 6 times daily for a period of 6 weeks on tapering dose. Patients were followed up after 7 and 40 days post operatively and at each visit a detailed slit lamp examination, tonometry and BCVA were recorded.

The above data was compiled using standardized proforma. Data was analyzed statistically using the chi-square test and a p- value less than 0.05 was considered as statistically significant.

3. Results

There were a total of 50 cases that underwent lens induced glaucoma during the study period. Majority of the cases were in the age group of 66-75 years (44%). The youngest case in the study group was 45 years old while the oldest was 80 year old. Thirty six cases (72%) were females. The age and gender distribution is shown in Table 1.

Left eye was affected in 26 cases (52%).

After development of symptoms, 25 cases (50%) presented within the 1st week, 12 cases (24%) within the 2nd week and rest 13 cases (26%) presented within the 3rd week shown in Figure 1. Most of the patients presented with vision of perception of light and accurate positive projection of rays (54%) followed by faulty projection of rays (26%) Table 2. The results were statistically significant. ($p=0.0024$)

Different types of LIG showed statistically significant results (p -value= 0.001) and 47 cases (94%) were diagnosed as phacomorphic glaucoma, 3 cases (6%) of phacolytic glaucoma. While examining condition of the other eye it was found that 25 cases (50%) presented with pseudophakia, 21 cases (42%) presented with IMSC, 4 cases (8%) were with normal limit (WNL) but the results were statically insignificant.

There was a statistically significant/ highly significant difference seen for the frequencies between the vision in other Eye ($p<0.01, 0.05$) with higher frequencies of better than 6/60 as compared to 6/60 and worse.

3.1. Pre-operative findings

Table 4 depicts 9 cases (18%) presented with intraocular pressure less than 30 mmHg, 24 cases (48%) with intraocular pressure between 30- 40 mmHg, 17 cases with intraocular pressure more than 40 mm Hg (34%). The highest pressure recorded during the study was 50.60 mm Hg. But the differences were not statistically significant. (p -value= 0.666) Considering the nature of cataract surgery, all the 50 patients underwent a manual small incision cataract surgery along with posterior chamber intraocular lens implantation in 94% of cases while 2 cases had a sulcus fixated intraocular pressure due to posterior capsular rent and 1 case was kept aphakic. The results were highly significant ($p<0.00001$).

3.2. Post-operative findings

Visual acuity was recorded on day 1, day 7 and day 40 postoperatively. The best corrected visual acuity recorded on day 40 represented maximum cases improved to a vision of 6/6-6/12 (44%) and only 4 cases had a poor acuity with No Projection of light and Perception of light + Projection of rays. There was a statistically significant difference seen for the frequencies between the duration of symptoms and final best corrected visual acuity ($p= 0.049$) indicating relation

between duration of symptoms and final visual outcome.

Clinically significant association was found between pre-operative intraocular pressure and final best corrected visual acuity but statistically there was no significant difference seen for the frequencies between the intra-ocular pressure and best corrected visual acuity ($p>0.05$) with chi square value = 8.577, $p= 0.073$.

Also, the cases (100%) with raised pre-operative intraocular pressure (>21 mmHg), had a normal intraocular pressure (<21 mmHg) after post cataract extraction, post-operatively with chi square value=96.040, $p= 0.0000(<0.001)$. This is described in the line diagram in Figure 2.

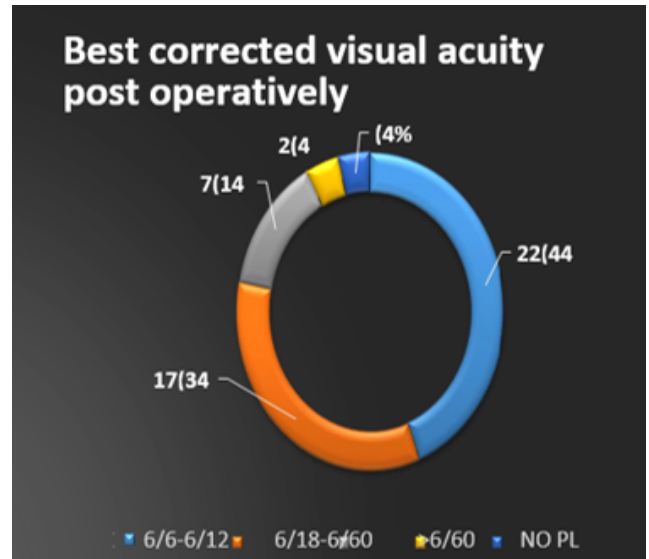


Fig. 1: Best corrected visual acuity post-operatively

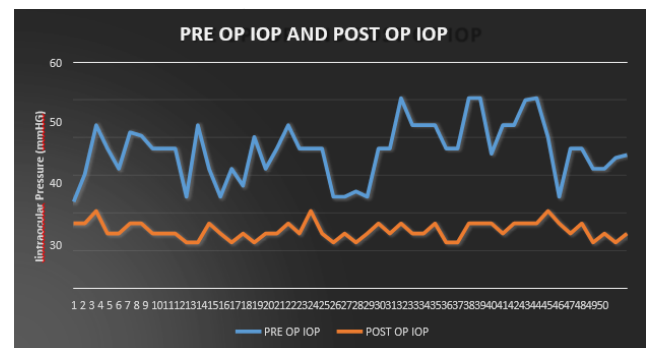


Fig. 2: Pre- operative and post-operative intraocular pressure

4. Discussion

Lens induced glaucomas are very common in India.⁷ This study encountered with two types of glaucomas, i.e;

Table 1: Age and gender distribution of Lens induced glaucoma

Age in years and gender distribution	45-55 (years)	56-65 (years)	66-75 (years)	>75 (years)	Total
Females	2	14	15	5	36
Males	4	3	7	0	14
Total number of patients	6	17	22	5	50
Percentage (%)	12%	34%	44%	10%	100%

Table 2: Type of vision at the time of presentation

Vision	Number of cases	Percentage
PL+PR+	27	54%
PL+ PR FAULTY	13	26%
NO PL	03	6%
Finger counting	03	6%
Hand movements	03	6%
6/60	01	2%
Total	50	100%

PL= Perception of light, PR= Projection of rays

Table 3: Comparison of duration of symptoms and final best corrected visual acuity

Duration of symptoms and final BCVA	6/6-6/12	6/18-6/60	>6/60	Total
<1 week	16 (64%)	6 (24%)	3 (12%)	25 (50%)
1-2 weeks	4 (33%)	5 (42%)	3 (25%)	12 (24%)
>2 weeks	2 (15%)	6 (46%)	5 (39%)	13 (26%)
Total	22 (44%)	17 (34%)	11 (22%)	50 (100%)

Chi square value = 9.297, p= 0.049, BCVA= Best corrected visual acuity

Table 4: Comparison of pre-operative intraocular pressure and best corrected visual acuity

Intraocular pressure	6/6-6/12	6/18-6/60	>6/60	Total
22-30 mmHg	6(67%)	0	3 (33%)	9 (18%)
30-40 mmHg	12 (50%)	8 (33%)	4 (17%)	24 (48%)
>40 mmHg	4 (23%)	9 (54%)	4 (23%)	17 (34%)
Total	22 (44%)	17 (34%)	11 (22%)	50 (100%)

mmHg = millimetres of Mercury

phacomorphic and phacolytic glaucomas. They are different clinically. But both the entities are lens induced and when the intraocular pressure rises, both the types compromise the function of the optic nerve. They share a common prognosis and cataract surgery is curative in these cases.

Majority cases were in the age group of 66-75 years (44%). The findings were in line with several other studies. Study conducted by Raghunandan Kothari et al. showed majority of cases in the age group of 56-81 yrs, another study by N Prajna, R. Ramkrishnan et al. represented as mean age of 62 years +/- 10 years for phacomorphic glaucoma and mean age of 63 years +/-11 years for phacolytic glaucoma.⁸

Thirty-six cases (i.e. 72%) were females and the findings were consistent with findings of studies conducted by Dr. G. Narendranatha Reddy et al.;⁹ reported that the incidence of lens induced glaucomas was slightly higher in females

(58%) than males. R.Ramkrishnan et al. conducted a study which reported female preponderance (70%).¹⁰ The female to male ratio in other studies, i.e; by Raghunandan Kothari et al. (ratio of 1.8:1), Lahan study by Pradhan et al. (ratio of 1.7:1)^{11,12} by Rakshya Pant Sitoula and Indrajit Sarkar et al. reported female to male ratio of 2.07:1 and this study it was 2.5:1.¹³

In 24 cases (48%) right eye was affected while in 26 cases (52%) left eye was affected and the results were consistent with the study conducted by Dr .G. Narendranatha Reddy et al.⁹ Twenty- five cases (50%) presented within the 1st week, 12 cases (24%) within the 2nd week and rest 13 cases (26%) presented within the 3rd week after development of symptoms. The findings regarding the time of presentation after development of symptoms co-related with and were comparable with the findings of several other studies.

It was observed that most of the patients presented with vision of perception of light and positive projection of rays (54%) followed by faulty projection of rays (26%). There was a statistically highly significant observation ($p < 0.001$) for higher frequencies of PL+PR+ seen ($p = 0.0024$). Cases of phacomorphic glaucoma and phacolytic glaucoma were diagnosed. Despite high IOP at the initial presentation in cases of lens induced glaucoma, IOP came down to normal limits after cataract extraction. The results of lens induced glaucoma in response to visual recovery and intra ocular pressure control were quite satisfactory and encouraging. Clinically significant association was found between pre-operative intra-ocular pressure and final best corrected visual acuity. The association between intraocular pressure and best corrected visual acuity was statistically non-significant ($p > 0.05$). The findings were consistent with majority of the studies.^{14,15}

There was a positive correlation between duration of symptoms and pre op IOP to the final best corrected visual acuity which was improved to a greater extent in majority of the cases. Positive correlation was found between duration of symptoms and final visual outcome. Same findings were noted in the other studies.¹⁶ According to Lim, Cheu & Jen the incidence of posterior capsular rent during cataract surgery was around 6-10%. The incidence of PCR was 6 percent in cases of lens induced glaucoma.

5. Conclusion

Good visual acuity could be achieved in Lens induced glaucoma presenting within 1 week, with intraocular pressure of less than 35 mm Hg and with meticulous control of intra-ocular pressure and inflammation with medications preoperatively. Otherwise it would result in severe inflammation, affecting the optic nerve, which would ultimately affect vision. Planned manual small-incision cataract extraction with IOL implantation, minimal tissue handling, a good follow-up with efficient management of attendant complications and inflammation are the key factors in the management. Emphasis should be made on creating awareness about cataract, its implications among the rural community, ophthalmic assistants, and peripheral health workers.

This study highlighted the importance of early diagnosis and efficient medical management to control IOP and inflammation, with meticulous surgery and IOL implantation. To achieve excellent visual prognosis proficient postoperative management and follow-up would probably be needed.

6. Source of Funding

None.

7. Conflict of Interest

None.

References

1. Murthy GVS, Murthy S, Gupta SK, Bachani D, Jose, John. Current estimates of blindness in India. *Br J Ophthalmol*. 2005;89:253.
2. Sihota R, Tandon R. Diseases of the eye. 22nd ed.; 2015.
3. Verma R, Khanna P, Prinja S, Rajput M, Arora V. The National Programme for Control of Blindness in India. *AMJ*. 2011;4(1):1–3.
4. Minassian DC, Mehra V. 3.8 million blinded by cataract each year: projections from the first epidemiological study of incidence of cataract blindness in India. *Br J Ophthalmol*. 1990;74(6):341–3.
5. Sharma RG, Verma GL, Singhal B. A clinical evaluation of Scheie's operation with sclerectomy along with lens extraction in lens induced glaucoma. *Indian J Ophthalmol*. 1983;31(5):639–41.
6. Jain IS, Gupta A, Dogra MR, Gangwar DN, Dhir SP. Phacomorphic glaucoma—management and visual prognosis. *Indian J Ophthalmol*. 1983;31(5):648–53.
7. Lowe RF. Causes of Shallow Anterior Chamber in Primary Angle-Closure Glaucoma. *Am J Ophthalmol*. 1969;67(1):87–93.
8. Prajna NV, Ramakrishnan R, Krishnadas R, Manoharan N. Lens induced glaucomas - Visual results and risk factors for final visual acuity. *Indian J Ophthalmol*. 1996;44(3):149–55.
9. Reddy GN, Premanandam M, Sudha G. Clinical Study of Visual Outcome of Lens Induced Glaucomas. *J Med Sci Clin Res*. 2015;3(2):4419–32.
10. George R, Arvind H, Baskaran M, Ramesh SV, Raju P, Vijaya L. The Chennai glaucoma study: Prevalence and risk factors for glaucoma in cataract operated eyes in urban Chennai. *Indian J Ophthalmol*. 2010;58(3):243–5.
11. Kothari R, Tathe S, Gogri P, Bhandari A. Lens-Induced Glaucoma: The Need to Spread Awareness about Early Management of Cataract among Rural Population. *ISRN Ophthalmol*. 2013;2013:1–3.
12. Pradhan D, Hennig A, Kumar J, Foster A. A prospective study of 413 cases of lens-induced glaucoma in Nepal. *Indian J Ophthalmol*. 2001;49(3):204.
13. Sitoula RP, Sarkar I, Nayak D, Singh SK. Lens induced glaucoma: An experience in tertiary eye care center in eastern Nepal. *Nepalese J Ophthalmol*. 2017;8(2):161–6.
14. Rao BYB, Gupta R, Harish B. Assessment of Intraocular Pressure and Visual Acuity in Patients of Lens Induced Glaucoma before and after Manual Cataract Surgery. *Int J Contemp Med Res*. 2018;5(12):10–3.
15. Akbani MI, Ashraf MF. Visual outcome in cases of lens-induced Glaucomas following Manual Small Incision Cataract Surgery in a tribal district of South India - A prospective study. *Sch J Appl Med Sci*. 2017;5(4F):1635–39.
16. Prajna RV, Ramakrishnan R, Krishnadas R, Manoharan N. Lens induced glaucomas - Visual results and risk factors for final visual acuity. *Indian J Ophthalmol*. 1996;44(3):149–55.

Author biography

Mohite Uday Sheshrao Professor and Head

Gandhi Niyati Pankaj Resident

Cite this article: Sheshrao MU, Pankaj GN. Visual outcome and intraocular pressure control after cataract surgery in patients with lens induced glaucoma: A longitudinal study at a tertiary care centre. *Indian J Clin Exp Ophthalmol* 2020;6(3):452-456.