



Original Research Article

Evaluation of ocular manifestations in Type 2 Diabetes mellitus

Deepa R^{1,*}, Anuradha P¹¹Dept. of Ophthalmology, Saveetha Medical College, Chennai, Tamil Nadu, India

ARTICLE INFO

Article history:

Received 11-04-2020

Accepted 18-04-2020

Available online 30-09-2020

Keywords:

Diabetes mellitus

Diabetic eye diseases

Diabetic retinopathy

Ocular manifestation

ABSTRACT

Objective: The prevalence of diabetes mellitus is increasing globally and a range of ocular conditions with sight threatening complications due to diabetes are known to occur. Aim of this study is to evaluate diabetes related ocular changes in patients with type 2 diabetes mellitus in a tertiary care hospital.

Design: Observational study.

Materials and Methods: Study was conducted with a total number of 90 patients with Type 2 diabetes mellitus in a tertiary care hospital. Patients aged 40 to 70 years with duration of diabetes mellitus of more than 5 years were included. They underwent a detailed fundus examination and ocular evaluation which included refraction, Schirmer's test, corneal sensitivity, Applanation tonometry, gonioscopy along with systemic investigations and the observed findings were recorded.

Results: It was noted that among the study population, majority of them (42.2%) were in the age group between 51-60 years and men (54.4%) were more in number than females (45.5%). Diabetic retinopathy was the most common ocular manifestation (47.7%) followed by cataract (44.4%), cranial nerve palsy (16.6%) and glaucoma (16.6%).

Conclusion: These ocular findings suggest that regular screening and eye examinations of diabetic patients is mandatory to reduce the burden of visual impairment.

© 2020 Published by Innovative Publication. This is an open access article under the CC BY-NC license (<https://creativecommons.org/licenses/by-nc/4.0/>)

1. Introduction

The prevalence of diabetes mellitus (DM) is increasing globally in both developed and developing countries.¹ The global prevalence of diabetes mellitus in the year 2017 was estimated to be approximately 425 million and it is said to increase to approximately 630 million in 2045.²

Type 2 Diabetes mellitus, which is a disease of impaired metabolism characterized by insulin resistance and relative decrease in insulin secretion. Chronic state of hyperglycemia of diabetes, is associated with damage to blood vessels, eyes, kidneys, nerves and heart. There is a high potential for vision loss in patients with diabetes mellitus, with approximately two-thirds of the population having varying degrees of visual impairment after 30 – 40 years of diabetes, manifesting with a range of ocular

diseases involving structures from the lids to retina and to cranial nerves.^{3–5} Current treatment modalities are aiming to preserve vision and to prevent blindness by timely diagnosis and treatment of ocular manifestations due to diabetes.⁶ The aim of this study is to evaluate the diabetes related ocular changes in patients with type 2 diabetes mellitus in a tertiary care hospital.

2. Materials and Methods

A hospital based Observational study which included 90 patients who attended the OPD of our tertiary care hospital over a period of 9 months from January 2019 to September 2019 and the study was approved from the Institutional Ethical committee. Patients aged 40 to 70 years with type 2 diabetes mellitus, of duration of more than 5 years were included in the study. Patients with associated systemic co-morbidities, previous treatment in the eye or ocular trauma were excluded from the study. A detailed

* Corresponding author.

E-mail address: deepamoorthy16@gmail.com (Deepa R).

history was obtained along with systemic examination was done. All patients were subjected to routine systemic investigations. Ocular examination and evaluation was done which included best corrected visual acuity, Schirmer’s test, corneal sensitivity, Applanation tonometry, gonioscopy and fundus examination using IDO and the observed findings were recorded.

3. Results

Among the study population of 90 patients, there were 31 patients (34.4%) in the age group of 40-50 years, 38 patients (42.2%) of age group between 51-60 years and 21 (23.3%) patients aged 61-70 years. (Figure 1) and there were 49 males (54.4%) and 41 females (45.5%). (Figure 2). Distribution of study population based on best corrected visual acuity is depicted in Table 1, among which 16 patients (17.7%) had BCVA < 3/60. Ocular manifestations of patients with type 2 diabetes is shown in Figure 3, of which Diabetic retinopathy is the most common manifestation seen in 43 patients (47.7%) followed by Cataract in 40 patients (44.4%).

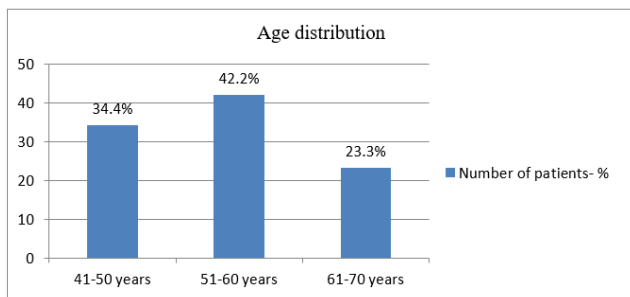


Fig. 1: Age distribution

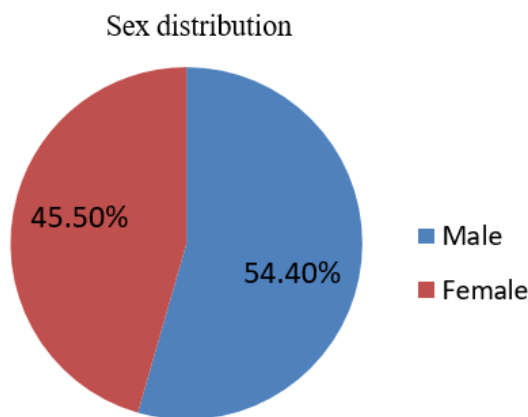


Fig. 2: Sex distribution

Among the diabetic patients who presented with cranial nerve palsy (16.6%), the pattern of involvement of cranial nerve palsy is as follows (n=15).(Figure 4)

Table 1: Distribution of study population based on BCVA

BCVA	Number of patients (n=90)
6/6-6/18	20(22.2%)
6/18-6/60	26(28.8%)
6/60-3/60	28(31.1%)
< 3/60	16(17.7%)

Based on the various corneal findings observed in 13 patients of the study population, 2(15.3%) patients had exposure keratopathy, 7 (53.8%) patients had corneal ulcer, 4(30.7%) patients had superficial punctate keratitis. Incidence of dry eye among the diabetic patients was 25.5%. Association of various types of glaucoma in the diabetic patients are shown in the Table 2. Diabetic retinopathy was present in 43 patients (47.7%) and it was graded according to ETDRS classification as in Table 3.

Table 2: Type of glaucoma among the diabetic patients

Type of Glaucoma	Number of patients (n=15)
POAG	7(46.7%)
PACG	2(13.3%)
NVG	5(33.3%)
Lens induced glaucoma	1(6.66%)

Table 3: Classification of Diabetic retinopathy among the study population

Grades of DR	Number of patients (n=43)
Mild NPDR	9(20.9%)
Moderate NPDR	12(27.9%)
Severe NPDR	16(37.2%)
High risk PDR	3 (6.97%)
Advanced PDR	3 (6.97%)
DME	21 (48.83%)

4. Discussion

Thus this study help us to know the different spectrum of ocular manifestation of patients with Type 2 diabetes mellitus In our study, majority of them were in the age group 51-60 years (42.2%) as in accordance to many studies.⁷⁻⁹ and males were more in number than females but a study reported that chronic subclinical inflammation showed stronger association of Type 2 DM with women than men.¹⁰ According to our study, majority of the patients (31.1%) with best corrected visual acuity was between 6/60-3/60 and around 17.7% had visual acuity <3/60 which emphasizes that all diabetic patients must be aware of the vision threatening complications of diabetes and hence the need for regular eye examinations.^{11,12} It was noted in our study that most common acquired cranial nerve palsy due to diabetes(16.6%) was abducens nerve followed sequentially

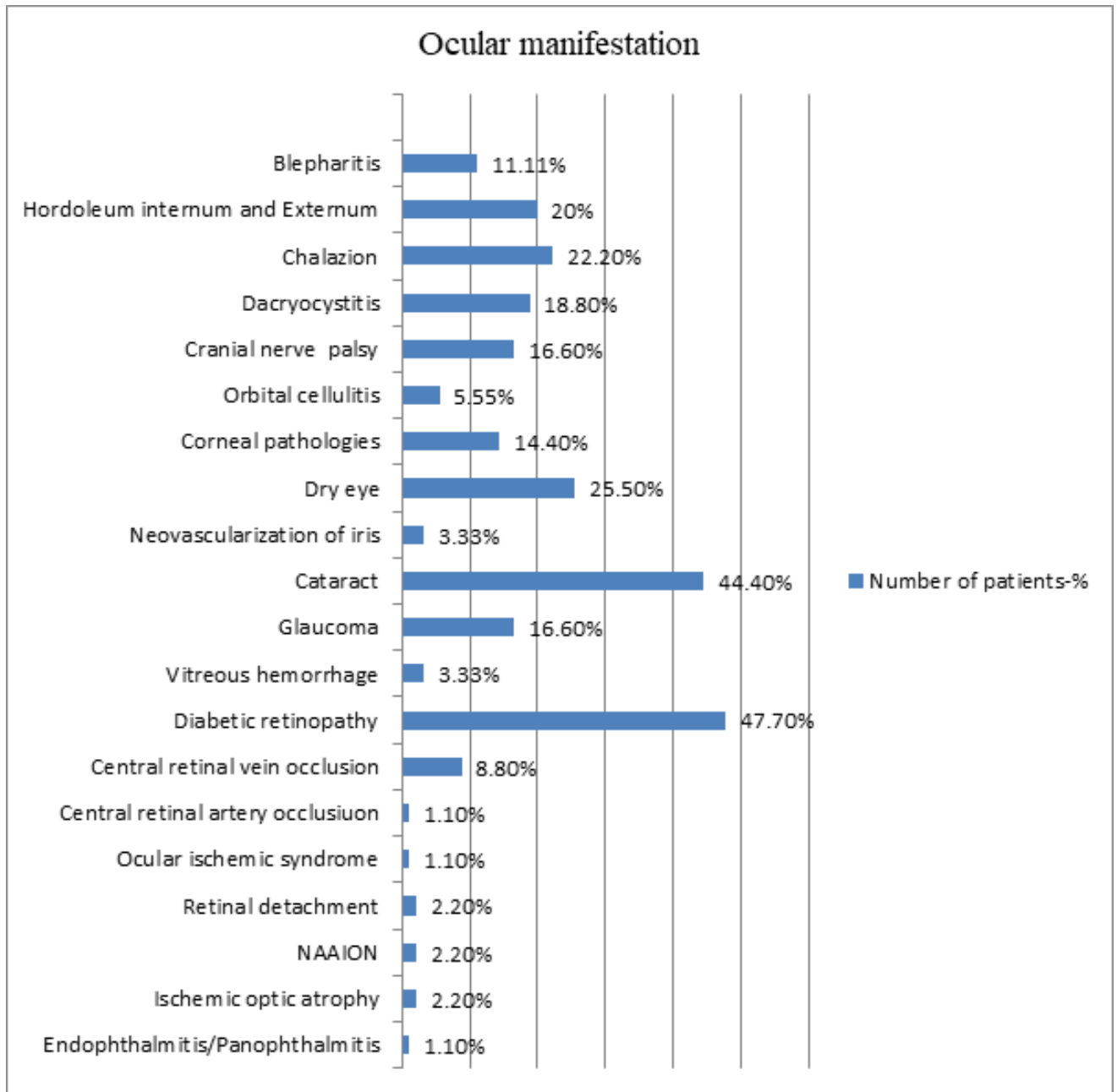


Fig. 3: Distribution of study population based on ocular manifestations

by oculomotor nerve, facial nerve and trochlear nerve. As reported, diabetes is the underlying cause in 25-30% of the patients aged above 45 years who developed acute extraocular muscle palsy.¹³ Corneal abnormalities were noted in 14.4% of the patients while a study reported that corneal pathologies were detected upto 73.6% of patients with diabetes due to high accumulation of sorbitol.¹⁴ Patients with diabetes are at a risk of developing two major types of glaucoma which is primary open angle glaucoma and neovascular glaucoma¹⁵⁻¹⁸ as in our study among the

patients detected with glaucoma(16.6%), the most common was primary open angle glaucoma followed by neovascular glaucoma. About 44.4% of the study group manifested with cataract and numerous studies have documented an association between diabetes and cataract.¹⁹⁻²² Diabetic retinopathy being the major cause of visual impairment in patients with diabetes,²³⁻²⁸ about 47.7% of patients have been diagnosed with diabetic retinopathy where majority of them had severe NPDR. Thus this study revealed a wide spectrum of ocular conditions that has been associated

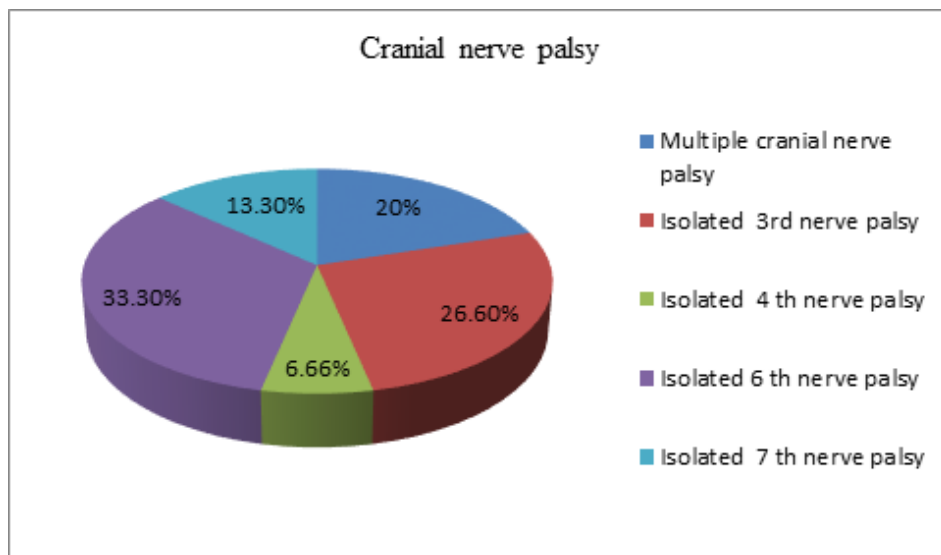


Fig. 4: Pattern of involvement of cranial nerve palsy

with diabetes. Management of diabetes eye diseases is primarily preventive and hence regular eye examinations and appropriate ophthalmology referral remains the key to prevent diabetes related vision loss.

5. Limitations of the Study

Long term complications were not assessed.

6. Source of Funding

None.

7. Conflicts of Interest

None.

References

- Rani P, Raman R, Subramani S. Knowledge of diabetes and diabetic retinopathy among rural populations in India, and the influence of knowledge of diabetic retinopathy on attitude and practice. *Rural Remote Health*. 2008;8:838.
- International Diabetes Federation. IDF Diabetes Atlas. 8th ed. Available from: <http://www.diabetesatlas.org>.
- Lotfy M, Adeghate J, Kalasz H, Singh J, Adeghate E. Chronic Complications of Diabetes Mellitus: A Mini Review. *Curr Diabetes Rev*. 2016;13(1):3–10.
- Fowler MJ. Microvascular and Macrovascular Complications of Diabetes. *Clin Diabetes*. 2008;26(2):77–82.
- Klein R, Klein BEK, Moss SE. Visual Impairment in Diabetes. *Ophthalmol*. 1984;91(1):1–9.
- Ferris FL. Issues in Management of Diabetic Retinopathy. *Hosp Pract*. 1993;28(5):79–89.
- King H, Aubert RE, Herman WH. Global Burden of Diabetes, 1995–2025: Prevalence, numerical estimates, and projections. *Diabetes Care*. 1998;21(9):1414–31.
- Deshpande AD, Harris-Hayes M, Schootman M. Epidemiology of Diabetes and Diabetes-Related Complications. *Physical Ther*. 2008;88(11):1254–64.
- World Health Organization. Prevention of Blindness from Diabetes Mellitus. Geneva: WHO; 2006.
- Thorand B, Baumert J. Sex differences in the prediction of type2 diabetes mellitus by inflammatory markers. *Diabetes care*. 2007;30(4):854–60.
- Klein R, Klein BEK, Moss SE. Visual Impairment in Diabetes. *Ophthalmol*. 1984;91(1):1–9.
- Brechner RJ. Ophthalmic examination among adults with diagnosed diabetes mellitus. *J Am Med Assoc*. 1993;270(14):1714–8.
- Rush JA. Extraocular Muscle Palsies in Diabetes Mellitus. *Int Ophthalmol Clin*. 1984;24(4):155–9.
- Didenko TN. Clinical and pathogenetic features of neurotrophic corneal disorders in diabetes. *Vestn Oftalmol*. 1999;115:7–11.
- Kahn HA, Milton RC. Revised Framingham Eye Study prevalence of glaucoma and diabetic retinopathy. *Am J Epidemiol*. 1980;111(6):769–76.
- Dielemans I, de Jong PTVM, Stolk R, Vingerling JR, Grobbee DE, Hofman A. Primary Open-angle Glaucoma, Intraocular Pressure, and Diabetes Mellitus in the General Elderly Population. *Ophthalmol*. 1996;103(8):1271–5.
- Loffler KU. Neovascular glaucoma: aetiology, pathogenesis and treatment. *Ophthalmol*. 2006;103:1057–63.
- Hohl RD, Barnett DM. Diabetic Hemorrhagic Glaucoma. *Diabetes*. 1970;19(12):944–7.
- Rowe NG. Diabetes, fasting blood glucose and age-related cataract: the Blue Mountains Eye Study. *Ophthalmic Epidemiol*. 2000;7:103–14.
- Hiller R, Sperduto RD, Sperduto F. Epidemiologic associations with nuclear, cortical, and posterior subcapsular cataracts. *Am J Epidemiol*. 1986;124(6):916–25.
- Miglior S, Marighi PE, Musicco M, Balestreri C, Nicolosi A, Orzalesi N. Risk factors for cortical, nuclear, posterior subcapsular and mixed cataract: a case-control study. *Ophthalmol Epidemiol*. 1994;1(2):93–105.
- Saxena S, Mitchell P, Rochtchina E. Five-year incidence of cataract in older persons with diabetes and pre-diabetes. *Ophthalmol Epidemiol*. 2004;11(4):271–7.
- Raman R, Rani PK, Racheppalle SR, Gnanamoorthy P, Uthra S, Kumaramanickavel G. Prevalence of diabetic retinopathy in India: Sankara Nethralaya diabetic retinopathy epidemiology and molecular genetics study report. *Ophthalmol*. 2009;116:311–8.
- Solomon SD, Chew E, Duh EJ, Sobrin L, Sun JK, VanderBeek BL, et al. Diabetic Retinopathy: A Position Statement by the American Diabetes Association. *Diabetes Care*. 2017;40(3):412–8.

25. Awh CC, Cupples HP, Javitt JC. Improved detection and referral of patients with diabetic retinopathy by primary care physicians. Effectiveness of education. *Arch Intern Med.* 1991;151:1405–1413.
26. Rohan TE, Frost CD, Wald NJ. Prevention of blindness by screening for diabetic retinopathy: a quantitative assessment. *BMJ.* 1989;299(6709):1198–1201.
27. Dandona L, Dandona R, Naduvilath TJ, McCarty CA, Rao GN. Population based assessment of diabetic retinopathy in an urban population in southern India. *Br J Ophthalmol.* 1999;83(8):937–40.
28. Maurya RP. Diabetic retinopathy: My brief synopsis. *Indian J Clin Exp Ophthalmol.* 2015;1(4):189–90.

Author biography

Deepa R Junior Resident

Anuradha P Associate Professor

Cite this article: Deepa R , Anuradha P . Evaluation of ocular manifestations in Type 2 Diabetes mellitus. *Indian J Clin Exp Ophthalmol* 2020;6(3):338-342.