



Original Research Article

A clinical study of association between asteroid hyalosis and diabetes mellitus

Jitendra Kumar¹, Samya Singh^{1,*}, Amisha Garg¹¹Dept. of Ophthalmology, MLB Medical College, Jhansi, Uttar Pradesh, India

ARTICLE INFO

Article history:

Received 09-01-2020

Accepted 12-02-2020

Available online 16-06-2020

Keywords:

Asteroid hyalosis

Diabetes mellitus

ABSTRACT

Aim: to study the association between asteroid hyalosis and diabetes mellitus.**Material and Methods:** This study was carried out in the Department of Ophthalmology, MLB Medical College, Jhansi between February 2019- December 2019 on patients diagnosed with asteroid hyalosis on routine examination. A total of 80 patients who showed evidence of asteroid hyalosis were further sent for random blood sugar and HbA1c levels. They were then divided into two groups-group A was diabetic and group B-non diabetic**Results:** The median age of presentation was between 40-75 years. 80 patients diagnosed with asteroid hyalosis were divided into two groups; Group A with diabetes and Group B without diabetes. In Group A there were 68.42% males (13) and 31.58% females (6) and in Group B there were 70.50% males (43) and 29.50% females(18). In group A 63.16% (12) patients showed unilateral eye involvement and 36.84% (7) patients showed bilateral eye involvement while in group B 80.33%(49) patients showed unilateral eye involvement and 19.67% (12) patients showed bilateral involvement. The mean random blood sugar was found to be 239.26±38.37 mg/dl in group A while in group B it was found to be 132.31±26.26 mg/dl. The p-value was found to be <0.0001 which was extremely statistically significant. The mean HbA1c levels was found to be 8.4±1.3% in group A whereas in group B it was 5.4±0.6%.The p-value was found to be <0.0001 which was extremely statistically significant**Conclusion:** There appears to be significant association between asteroid hyalosis and diabetes mellitus.© 2020 Published by Innovative Publication. This is an open access article under the CC BY-NC license (<https://creativecommons.org/licenses/by-nc/4.0/>)

1. Introduction

Asteroid hyalosis is a common degenerative process in which calcium pyrophosphate particles collect within the vitreous gel. It is seen clinically as numerous tiny round yellow-white opacities of various size and density. An autopsy study¹ of 10801 eyes found an incidence of 1.96%;with male/female ratio of 2:1. Asteroid hyalosis is unilateral in greater than 75% of cases.

Asteroid bodies are associated with the vitreous gel and move with vitreous displacement during eye movement, thereby suggesting a relationship with age related collagen fibril degeneration. However, PVD either complete or partial occurs less frequently in individuals with asteroid hyalosis than in age-matched controls and this finding does not

support age related degeneration as a cause. The prevalence of asteroid hyalosis increases with age and affects 3% of those aged 75-86 years. OCT and ultrasonography show high reflectivity foci.

Some reports have suggested an association²⁻⁵ between asteroid hyalosis and diabetes mellitus whereas other investigations found no such association.⁶⁻⁸ Asteroid hyalosis appears to be associated with certain pigmentary retinal degenerations although it is not known whether this is related to the presence of diabetes in these patients.

Yu and Blumenthal⁹ proposed that asteroid hyalosis results from aging collagen whereas other studies have suggested that asteroid formation is preceded by depolymerization of hyaluronon.

The most interesting aspect of asteroid hyalosis is marked absence of patient complaints and symptoms.

* Corresponding author.

E-mail address: samyal1sept@gmail.com (S. Singh).

Although it can be difficult in some cases to examine and image the fundus, these patients often experience no visual disturbances whereas patients with PVD can be markedly symptomatic. It is hypothesized that the explanation is related to the smooth surfaces of asteroid bodies that may not scatter light in as disturbing a fashion as irregular surfaces of the collagen fibrils of the vitreous body.

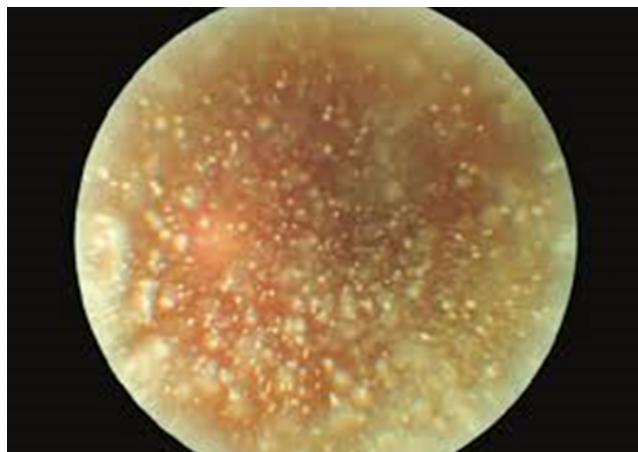


Fig. 1: Asteroid hyalosis clinical appearance

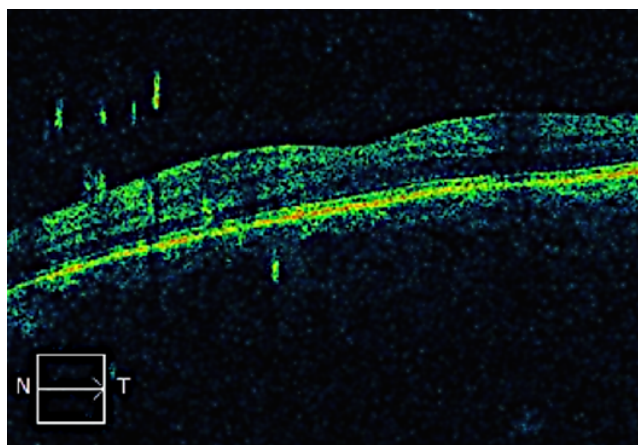


Fig. 2: OCT appearance of asteroid hyalosis

2. Materials and Methods

The study was done in the Department of Ophthalmology, MLB Medical College, Jhansi from February 2019- december 2019. A total of 80 patients presenting to the OPD who were diagnosed with asteroid hyalosis and fitted the inclusion and exclusion criteria were taken for the study. It was performed under the Helsinki Declaration of 1975, as revised in 2000. An informed consent of the patients was taken and necessary permission was obtained from the Ethical and Research Committee for the study.

The 80 patients diagnosed with asteroid hyalosis were divided into two groups-

Group A- diabetic (those with random blood sugar of 200mg/dl or higher or HbA1c higher than 6.5%).

Group B- non-diabetic (those with random blood sugar less than 200 mg/dl or HbA1c less than 6.5%).

All the patients of Group A and Group B will undergo complete ophthalmic examination, which includes best corrected visual acuity, slit lamp anterior segment examination, slit lamp biomicroscopy (+90D)/ indirect ophthalmoscopy for posterior segment examination. Detailed history of all patients was taken regarding duration of diabetes and treatment. Random blood sugar and HbA1c levels were recorded.

2.1. Inclusion criteria

All patients presenting to the OPD of the Department of Ophthalmology, MLB Medical College, Jhansi between February 2019- December 2019 with the diagnosis of asteroid hyalosis.

2.2. Exclusion criteria

1. Patients with Diabetes Mellitus with hypertension, thyroid disorder and other systemic diseases.
2. Patients having other retinal or vitreous disorders.
3. Patients having corneal pathology and any other ocular abnormalities like pterygium, entropion, trichiasis.
4. Patients who have undergone previous ocular surgeries.
5. Mentally or physically unfit patients.

2.3. Statistical analysis

All analyses were performed using statistical software Graph pad. All means were expressed as mean \pm standard deviation. Differences of means were analyzed using the t-test where appropriate and forward stepwise binary logistic regression was implemented for analysis of the variables: random blood sugar and HbA1c levels in association with the development of asteroid hyalosis. The critical value of significance was set at $P < 0.05$ for all tests.

3. Results

The 80 patients diagnosed with asteroid hyalosis were divided into two groups; Group A with diabetes and Group B without diabetes. In Group A there were 68.42% males (13) and 31.58% females (6) and in Group B there were 70.50% males (43) and 29.50% females (18).

In group A 63.16% (12) patients showed unilateral eye involvement and 36.84% (7) patients showed bilateral eye involvement while in group B 80.33% (49) patients showed unilateral eye involvement and 19.67% (12) patients showed bilateral involvement.

Group A had 19 patients therefore 23.75% of patients with asteroid hyalosis were diabetic while Group B had 61 patients therefore 76.25% of patients with asteroid hyalosis were non-diabetic.

The mean random blood sugar was found to be 239.26 ± 38.37 mg/dl in group A while in group B it was found to be 132.31 ± 26.26 mg/dl. The p-value was found to be <0.0001 which was extremely statistically significant.

The mean HbA1c levels was found to be 8.4 ± 1.3 % in group A whereas in group B it was 5.4 ± 0.6 %.

The p-value was found to be <0.0001 which was extremely statistically significant. The median age of presentation was found to be 40-75 years.

Table 1: Sex distribution of patients in Group A and Group B

Group	Sex	Number of patients	Percentage
Group A	Males	13	68.42%
	Females	6	31.58
Group B	Males	43	70.50%
	Females	18	29.50%

Table 2: Eye involvement in Group A and Group B

Group	Eye involved	Number of patients	Percentage
Group A	Unilateral	12	63.16%
	Bilateral	7	36.84%
Group B	Unilateral	49	80.33%
	Bilateral	12	19.67%

Table 3: Comparison of Random blood sugar in Group A and Group B

Group	Number of patients	Mean RBS(mg/dl)	p-value
Group A	19	239.26 ± 38.37	<0.0001
Group B	61	132.31 ± 26.26	

Table 4: Comparison of HbA1c in Group A and Group B

Group	Number of patients	Mean HbA1c	p-value
Group A	19	8.4 ± 1.3	<0.0001
Group B	61	5.4 ± 0.6	

4. Discussion

There have been quite a few studies to determine the association between diabetes mellitus and asteroid hyalosis and till date the association between the two remains debatable. While in some studies the relation between the two has been clearly established, others have completely ruled out the possibility of any correlation.

In our study out of 80 patients who were diagnosed with asteroid hyalosis 19(23.75%) had established diabetes

mellitus. The mean random blood sugar was found to be 239.26 ± 38.37 mg/dl in group A while in group B it was found to be 132.31 ± 26.26 mg/dl. The p-value was found to be <0.0001 which was extremely statistically significant. The mean HbA1c levels was found to be 8.4 ± 1.3 % in group A whereas in group B it was 5.4 ± 0.6 %. The p-value was found to be <0.0001 which was extremely statistically significant. Zinn¹⁰ found 27% patients with asteroid hyalosis were diabetic while Bergren¹¹ found that 29% of asteroid hyalosis patients were diabetic. Jones¹² has also documented a patient with acquired asteroid hyalosis in a case of early diagnosed diabetes mellitus which strongly supports a association between the two conditions The Blue Mountains Eye Study¹³ on the other hand, failed to establish a significant association between asteroid hyalosis and diabetes as well as other systemic conditions like heart disease, higher body mass index, a history of gout and of higher levels of alcohol consumption.

Bilateral asteroid hyalosis was found in 23.75% of our patients. Moss¹⁴ in his study found approximately 9% bilateral cases of asteroid hyalosis whereas according to Zinn¹⁰ it was 25%. Therefore it is quite clear that asteroid hyalosis is mostly unilateral. The bilateral cases of asteroid hyalosis are mostly related to systemic diseases like diabetes, the rationale being that both the eyes are equally exposed to a particular systemic condition (like hyperglycemia in case of diabetes mellitus). In our study also the diabetes group A has 36.84% bilateral involvement as compared to 19.67% bilateral involvement in the non diabetic group. This fact has also been confirmed by the UCLA autopsy study,¹ which observed a statistical association between diabetes and bilateral AH before adjusting the data for age and sex.

In our study asteroid hyalosis was found to be higher in males (68.42% in group A 70.50% in group B. Various other studies have also shown higher incidence in males.^{6,7,13,15–17}

5. Conclusion

Diabetes mellitus encompasses within itself a wide range of multi systemic diseases. Almost all body organs are affected in some way or the other by this disease. Asteroid hyalosis is a benign condition in which the eye develops yellow white opacities within the vitreous. The association between asteroid hyalosis and diabetes mellitus has been a debatable topic in ophthalmology. Though it has not been clearly established yet if the two are related or not but the evidence is enough to consider diabetes as a risk factor for asteroid hyalosis especially in cases of bilateral asteroid hyalosis. It is therefore advisable that patients of asteroid hyalosis should be screened for diabetes mellitus.

6. Source of Funding

None.

7. Conflict of Interest

None.

References

1. Fawzi AA, Vo B, Kriwanek R, Ramkumar HL, Cha C, Carls A, et al. Asteroid hyalosis in an autopsy population – the UCLA experience. *Arch Ophthalmol*. 2005;123(4):486–90.
2. Bard LA. Asteroid hyalosis: Relationship to diabetes and hypercholesterolemia. *Am J Ophthalmol*. 1964;58:239–41.
3. Cockburn DM. Are vitreous asteroid bodies associated with diabetes mellitus. *Am J Optom Physiol Opt*. 1985;62(1):40–3.
4. Sebag J, Albert DM, Craft JL. The alstrom syndrome: Ocular histopathology and retinal ultrastructure. *Br J Ophthalmol*. 1984;68(7):494–6.
5. Smith HL. Asteroid hyalites: Incidence of diabetes mellitus and hypercholesterolemia. *JAMA*. 1958;168:891–4.
6. Hatfield RE, Gastineau CF, Ruke CW. Asteroid bodies in the vitreous: Relationship to diabetes and hypercholesterolemia. *Mayo Clin Proc*. 1962;37:513–6.
7. Kearns TP. Discussion of asteroid hyalitis and diabetes mellitus. *Trans Am Acad Ophthalmol Otolaryngol*. 1965;69:277–81.
8. Luxenberg M, Sime D. Relationships of asteroid hyalosis to diabetes mellitus and plasma lipid levels. *Am J Ophthalmol*. 1969;67(3):406–9.
9. Yu SY, Blumenthal HT. The calcification of elastic tissue. In: Wagner BM, Smith DE, editors. *The connective tissue*; 1967. p. 17–49.
10. Zin KM. Asteroid hyalosis. In: Verlag S ed. *Clinical Atlas of Peripheral retinal disorders*. New York: Churchill Livingstone Publishers; 1988.
11. Bergren RL, Brown GC, Duker JS. Prevalence and association of asteroid hyalosis with systemic diseases. *Am J Ophthalmol*. 1991;111(3):289–93.
12. Jones WL, Twamley CR. Documented acquired asteroid hyalosis in a case of early-diagnosed diabetes mellitus. *Optom*. 2001;72(5):315–21.
13. Kim JH. Prevalence of and risk factors for asteroid hyalosis in Seoul, Korea. *Retina*. 2008;28(10):1515–21.
14. Moss SE, Klein R, Klein BE. Asteroid hyalosis in a population: The beaver dam eye study. *Am J Ophthalmol*. 2001;132(1):70–5.
15. Potter JW, Newcomb R. Prevalence of asteroid bodies in a VA optometry clinic. *J Am Optom Assoc*. 1980;p. 5119–25.
16. Lamba PA, Shukla KN. Vascular factors in asteroid hyalopathy. *Can J Ophthalmol*. 1971;p. 646–51.
17. Cockburn DM. Are vitreous asteroid bodies associated with diabetes mellitus? *Am J Optom Physiol Opt*. 1985;p. 6240–4.

Author biography

Jitendra Kumar Associate Professor

Samya Singh Junior Resident

Amisha Garg Junior Resident

Cite this article: Kumar J, Singh S, Garg A. A clinical study of association between asteroid hyalosis and diabetes mellitus. *Indian J Clin Exp Ophthalmol* 2020;6(2):231-234.